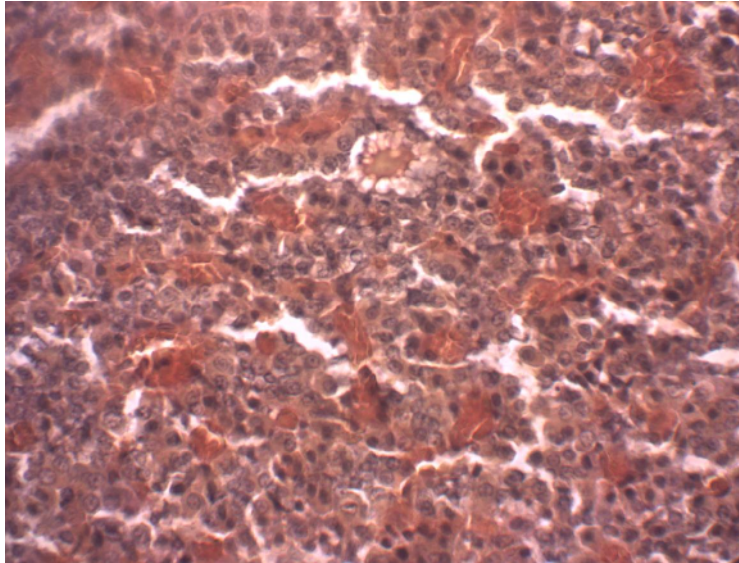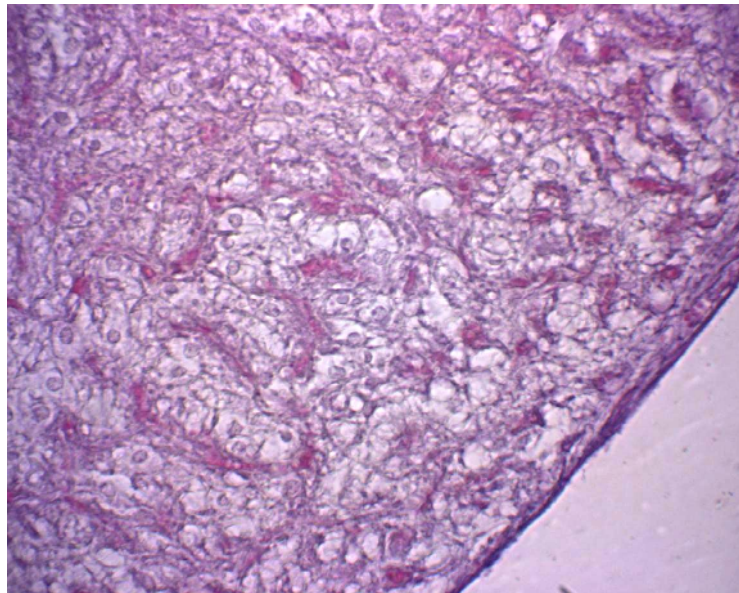


1 – *1* . . . 360



2 – *7* . . . 360

« »
,

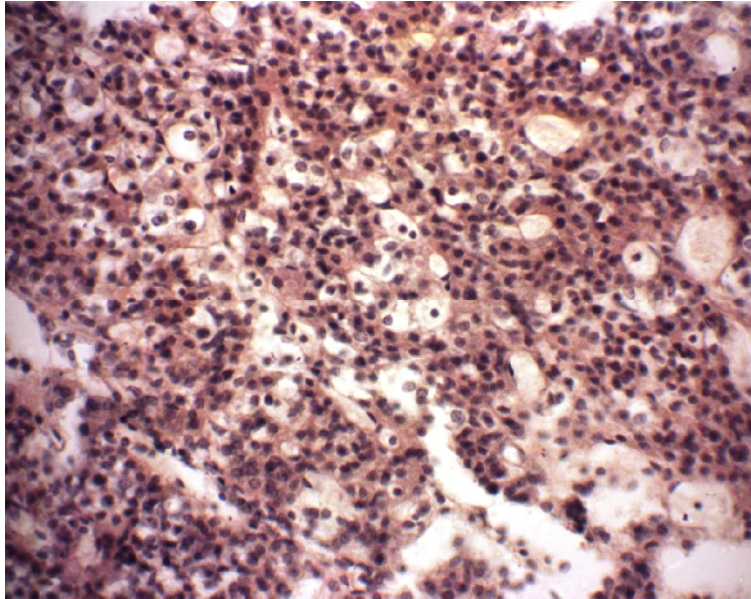
(, ,). , , , . : , . , 1- , - , , - , , - 7 , , , , , , (.2). , , , , , - , , , : , , . 15 , , , - , , - , , , , , (, ,), .

30

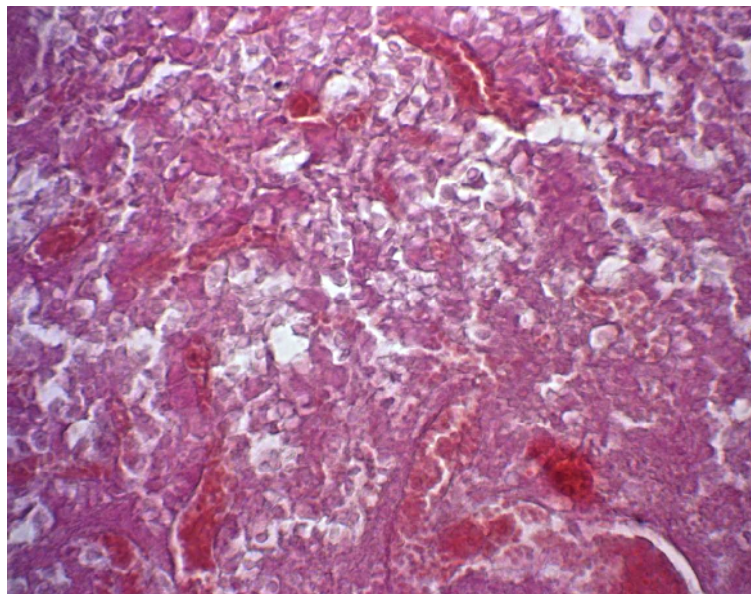
30

1-

(. 3).



3— *I* . . . 360



4— *15* . . . 360

, 1-

()

[3, 4],

7

« »,

(. 5).

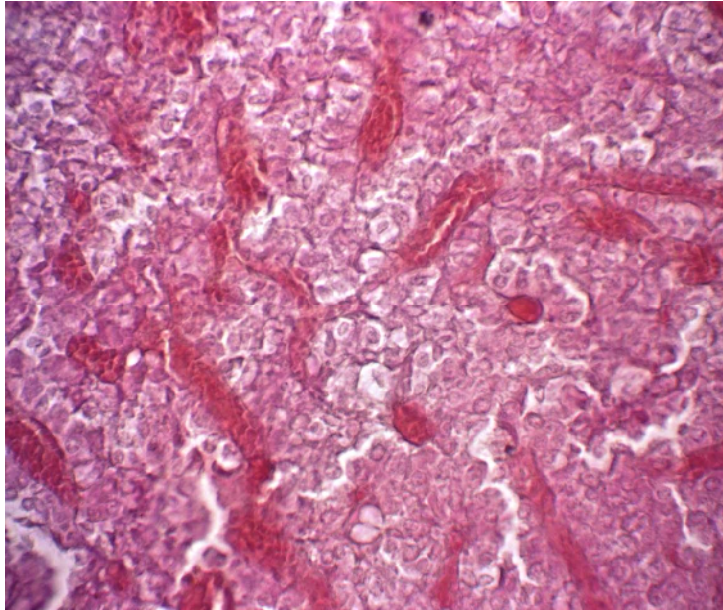
7-

15-

30

(. 6).

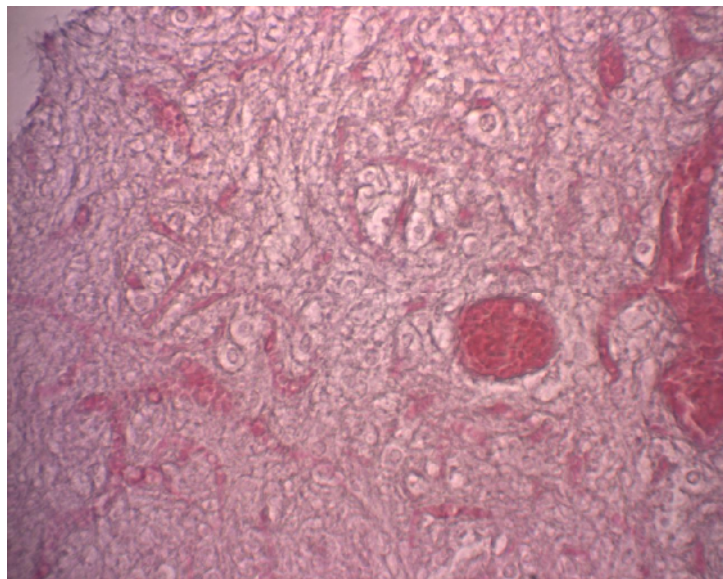
30



5—

7

360



6 -

30

360

[5].

SUMMARY

HISTOLOGICAL CHANGES OF RAT PITUITARISM OF DIFFERENT AGE UNDER HYPOSMOTIC OVERHYDRATION

Bumeister V. I., Korneikova I.P.
Sumy State University, Sumy

We studied morphological changes in rat pituitarism of different age under hyposmotic overhydration. The greatest changes are observed in senile animals, the least – in mature ones. With increasing time of observation in the period of readaptation the activation of compensatory and adaptive mechanisms leads to the restoration of the histological structure of hypophysis in young and mature animals.

Key words: pituitary gland, hyposmolarity, overhydration, histological changes.

1. Bankir L. Antidiuretic action of vasopressin: quantitative aspects and interaction between V1a and V2 receptor-mediated effects / L. Bankir // *Cardiovasc Res.* – 2001. – Vol.51. – P. 372–390.
2. Lee P. Hyponatremia in Pulmonary TB: Evidence of Ectopic Antidiuretic Hormone Production / P. Lee, K.Y. Ken // *Chest.* – 2010. – Vol. 137. – P. 207-208.
3. . . . / . . . , . . . // . . . – 2006. – 3 (44). – . 126-128.
4. . . . / . . . , . . . // 9- : . . . , 21-22 2005. – : . . . , 2005. – . 171.
5. . . . // . . . – 2006. – 12 (2). – . 260-263.

12 2011 .