

Giant-cell epulis: immunohistochemical analysis of MGMT, p53, OPN and MMP-1

Y. KUZENKO, A. ROMANYUK

Sumy State University, Department of Pathological Anatomy, Sumy, Ukraine

SOUHRN

Kuzenko Y., Romanyuk A.: **Epulis gigantocelularis: imunohistochemická analýza MGMT, p53, OPN a MMP-1**

Cíl práce: Cílem studie bylo analyzovat expresi MGMT, p53, OPN a MMP-1 u epulis gigantocelularis.

Materiál a metody: U deseti případů epulis gigantocelularis byla imunohistochemicky hodnocena exprese MGMT, p53, OPN a MMP-1.

Výsledky: Silná pozitivita MGMT v obrovských buňkách byla pozorována v 96,9 ± 0,5 % (P < 0,05). Silná mezenchymální imunoreaktivita MMP-1 byla zjištěna u obrovských buněk (75,9 ± 1,33%) a stromatu (54,12 ± 1,36%; P < 0,05). Imunoreaktivita OPN byla nalezena u obrovských buněk epulis v 15,77 ± 1,8 %, pozitivita p53 byla zjištěna u 5,67 ± 0,32 % obrovských buněk a 0 % stromatu.

Závěr: MGMT, p53 a OPN mohou hrát důležitou roli v biologii epulis gigantocelularis. Kromě toho, MMP-1 těchto proteáz ve vyšších hladinách u epulis gigantocelularis může pomoci vysvětlit invazi do kostní matrix.

Klíčová slova: MGMT, p53, OPN a MMP-1; imunohistochemie; orální epulis gigantocelularis

SUMMARY

Kuzenko Y., Romanyuk A.: **Giant-cell epulis: immunohistochemical analysis of MGMT, p53, OPN and MMP-1**

Object: The object of this study was to analyze the expression of MGMT, p53, OPN and MMP-1 in giant-cell epulis.

Methods: 10 giant-cell epulis were evaluated for expression of MGMT, p53, OPN and MMP-1 by immunohistochemistry.

Results: Strong giant-cell positivity for MGMT was observed in 96.9 ± 0.5 % (P < 0.05). Strong mesenchymal immunoreactivity for MMP-1 was figured in giant-cell, 75.9 ± 1.33 % and in the stroma 54.12 ± 1.36 % (P < 0.05). Immunoreactivity for OPN was fixed in the giant-cell of epulis 15.77 ± 1.8%, positivity for p53 was found in 5.67 ± 0.32 % of giant-cell contrast and in the stroma 0 %.

Conclusion: MGMT, p53 and OPN may play important roles in the biology of giant-cell epulis. Furthermore, the MMP-1 of these proteases at higher levels in giant-cell epulis may help to explain invasion in bone matrix.

Keywords: MGMT, p53, OPN and MMP-1, immunohistochemistry, oral giant-cell epulis

Osteologický bulletin 2013;18(3):87-9

Adresa: MUDr. Yevhen Kuzenko, Sumy State University, Department of Pathological Anatomy 2, Rymyskogo-Korsakova st., Sumy, 40007, Ukraine, e-mail: kuzenko_yevhen@rambler.ru

Došlo do redakce: 10. 4. 2013

Přijato k tisku: 14. 8. 2013

Introduction

Giant-cell epulis is an infrequent reactive, exophytic lesion of the oral cavity, also known as osteoclastoma, giant cell reparative granuloma, peripheral giant cell granuloma or giant cell hyperplasia.

It usually affects the mandible in 70 % of cases and the maxilla in the remaining 30 % [1]. Giant-cell epulis is associated with perforation of the cortical plate(s) [2]. It is probably a reactive lesion caused by local irritation or chronic trauma which hurts connective tissue, periosteum or periodontal membrane [3].

A study by Willing et al [4] says that the stromal cells secrete a variety of cytokines and differentiation factors, including monocyte chemoattractant protein-1 (MCP1), Osteoclast differentiation factor (ODF), and Macrophage-colony stimulating factor (M-CSF). These molecules are monocyte chemoattractants and are essential for osteoclast differentia-

tion, suggesting that the stromal cell stimulates blood monocyte immigration into tumour.

Immunohistochemical evaluation by Falaschini S et al [5] reveals a diffuse presence of CD68 (antigen most widely distributed in monocyte macrophages lineage at various differentiation stages as well dendritic cells and osteoclasts) in a fraction of round mononuclear stromal cells and in mononuclear giant cells. This result confirms that these latter may derive from osteoclasts, according to previous study [6].

Giant-cell epulis is strongly positive for this antibody CD34, reaction product is not evident in the lesion within the aggregations of multinucleate giant cells. This data may suggest that multinucleate giant cell does not come from endothelial cells of the capillaries [7].

In this study, we tested the hypothesis that p53 (tumor suppressing protein) is regulated by MGMT (O-6-methylguanine-DNA methyltransferase) in giant-cell epulis.

MGMT protein acts through a self-destruction mechanism, removing abnormal adducts from the O6 position of guanine, providing protection from mutagenic agents [8]. Loss of MGMT expression has been associated with aggressive tumor behavior and progression in several types of neoplasia, including esophageal, hepatocellular, lung, gastric and breast carcinomas [9].

Many types of stress activate p53, including DNA damage, telomere attrition, oncogene activation, hypoxia and loss of normal growth and survival signals. These stress signals may be encountered by a developing tumor. Activation of

p53 can induce several responses in cells, including differentiation, senescence, DNA repair and the inhibition of angiogenesis [10].

We tested the hypothesis that expression of matrix metalloproteinase-1 (MMP1), osteopontin (OPN) could also augment lesion periosteum or periodontal membrane.

Osteopontin (OPN) is biosynthesized by a variety of tissue types including fibroblasts, preosteoblasts, osteoblasts, osteocytes, odontoblasts, some bone marrow cells [11]. OPN which works as a cytokine, function as an extracellular matrix protein, protein against apoptosis and induce survival and proliferation in several cell types. OPN has a pro-survival and/or proliferative function in adherent cell types such as epithelial cells [11].

Matrix metalloproteinases (MMPs) secreted by cervical and ovarian cancer, especially MMP-2 and MMP-9, play crucial roles in tumor invasion and metastasis. Sutinen M et al [12] reported the release of MMP1 by human normal and transformed fibroblasts, chondrocytes, epithelial cells, macrophages. They showed that active MMP1 splitting by collagen I, VII, X. However, the mechanism of MMP1 activation was not elucidated in giant-cell epulis and degradation of extracellular periosteum or periodontal membrane matrix.

So it is necessary to understand the cellular mechanism of giant-cell epulis infiltrate the alveolar bone.

In the present work, we show the expression of MGMT, p53, OPN and MMP-1 in giant-cell epulis. There have been no reports about expression of MGMT, p53, OPN and MMP-1 in giant-cell epulis.

Methods

The study population included 10 patients with giant-cell epulis. Only patients with available tissue represent a subset of the overall study cohorts.

Hematoxylin and eosin (H&E) stains have been used for at least a century and are still essential for recognizing various tissue types and the morphologic change. Paraffin sections are immersing into three sets of xylene for 10 minutes each followed by three sets of absolute ethanol for 10 minutes and finally rinsed with tap water. Slides are placed into haematoxylin for 5 minutes and rinsed thoroughly under tap water for approximately 4–5 minutes. Excess haematoxylin is removed by adding 1% acid alcohol (1% HCl in 70% (v/v) alcohol) for 5 seconds followed by a tap water wash. The slides are rinsed in tap water before being stained in eosin (1% (w/v)) for 15 seconds with a subsequent wash in running tap water for 1–5 minutes. The slides are covered with glass cover slips.

Immunostainings for MGMT, p53, OPN and MMP-1 were performed on formalin-fixed (pH 7.4), paraffin-embedded Giant-cell epulis tissue sections using mouse monoclonal anti- MGMT, anti-OPN, anti-MMP-1 and anti- p53 (Thermo Fisher Scientific UK). Briefly, 4 µm thick tissue sections were dewaxed in xylene and were brought to water through graded alcohols. Antigen retrieval was performed by microwaving slides in 10mM citrate buffer (pH 6.2) for 30 min at high power, according to the manufacturer's instructions. To remove the endogenous peroxidase activity,

Figure 1
Giant-cell epulis, Haematoxylin and Eosin
(x800 magnification) A – Areas of haemorrhages,
B – Fibroblastic stroma, C – Giant cells

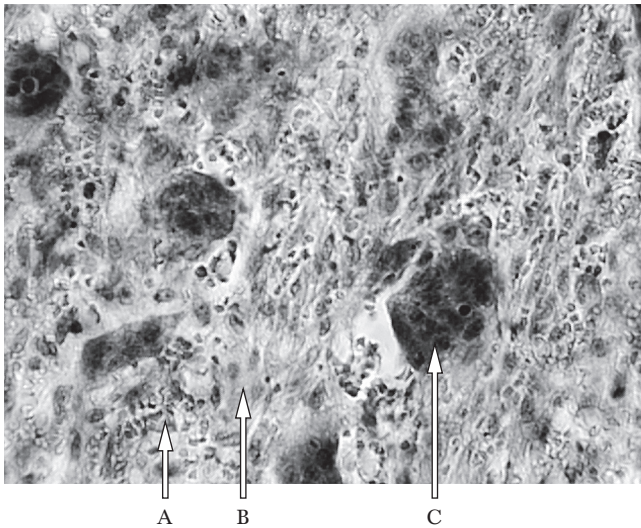
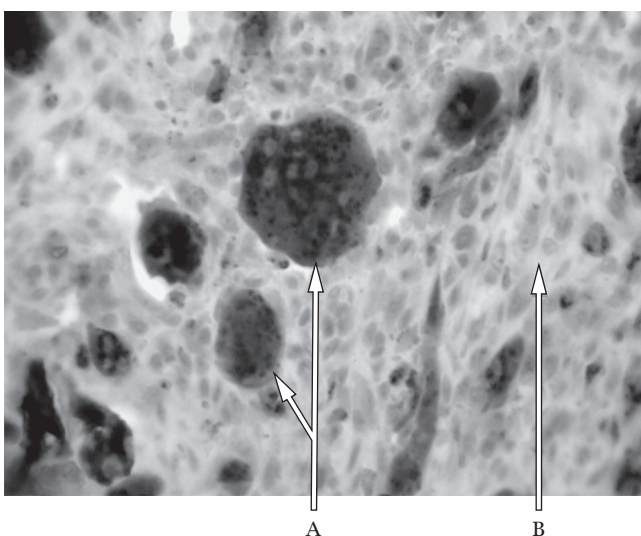


Figure 2
Expression of MGMT proteins in giant-cell epulis
(x800 magnification) A – Giant cells MGMT “+”,
B – Fibroblastic stroma MGMT “-”



sections were then treated with freshly prepared 1.0% hydrogen peroxide in the dark for 30 min at 37 °C temperature. Non-specific antibody binding was blocked using blocking serum. The sections were incubated for 30 min, at 37 °C temperature, with the primaries antibodies against MGMT, p53, OPN and MMP-2 diluted 1 : 100 in phosphate buffered saline (PBS) pH 7.2. After washing 3 times with PBS. Anti-(mouse IgG)–horseradish peroxidase conjugate (1 : 40 000 dilution) was used for the detection of the MGMT, p53, OPN and MMP-1 primaries antibodies, sections were then incubated for 20 min, at 37 °C temperature. The colour was developed by DAB.

Appearance of positive factors was detected semiquantitatively by counting of positive structures in visual field (- - 0, + - few, ++ - moderate, +++ - numerous, ++++ - abundance positive structures in visual field).

Results

Peripheral giant cell epulis is shown in *Figure 1*. Microscopic examination revealed tissue with giant-cell (*Figure 1C*), fibrous connective tissue (*Figure 1B*), areas of haemorrhages (*Figure 1A*) and few capillaries. There was no sign of malignancy.

MGMT and p53 was expressed in giant-cell. Expression of MGMT and p53 in giant-cell epulis is shown in *Figures 2 and 3*. Induction of the enzymatic activity of MGMT was increased p53. This could be explained by the fact that MGMT is physiologically expressed by the giant-cell of epulis, p53 expression is weak or absent in giant-cell epulis and non induced apoptosis in the fibrous connective tissue.

MMP-1 and OPN were expressed in all specimens. The immunorexpression of these proteins was confirmed by the presence of brown stained cytoplasm in giant-cell epulis. MMP-1 was expressed in giant-cell and stromal cells at the invasion front in all. In general, MMP-1 staining was more intense in the giant-cell than in the stroma.

By immunohistochemistry, $96.9 \pm 0.5 \%$ ($P < 0.05$) of giant-cells were positive for MGMT, whereas only $5.67 \pm 0.32 \%$ of giant-cells were positive for p53 ($P < 0.05$).

With respect to the immunorexpression of MMP-1 in giant-cell, $75,9 \pm 1.33 \%$ ($P < 0.01$) positive cells. In the stroma, immunoreactivity of MMP-1 was classified with a score of 9 in most cases $54.12 \pm 1.36 \%$ ($P < 0.05$) (*Figure 5*). OPN was expressed in giant-cell at the invasion front in all specimens analyzed. With respect to the immunorexpression of OPN in the giant-cell of epulis $10 (15.77 \pm 1.8 \%)$ ($P > 0.05$) cases (*Figure 4*) In the stroma, immunoreactivity of OPN was in cases 0 %.

Discussion

The results of this study demonstrate giant-cell expression of p53 or MGMT in human.

The role of MGMT proteins in response to DNA damage can be inferred from the interactions of MGMT proteins with the tumor suppressor protein, p53, and p53-related proteins. p53 acts as a major point in a complex network that responds to diverse cellular stresses, including DNA damage [13, 14].

In precancerous oral lesions, significant loss of MGMT expression was noted from hyperplasia to dysplasia, supporting the assumption that MGMT deregulation may be an early event in oral tumorigenesis [15].

Type I collagen, responsible for connective tissue strength and rigidity, is the main bone organic matrix component [16] and MMP-1 is one of the proteases that can degrade the triple-helical domain of type I fibrillar collagen [15]. The presence of MMP-1 in giant-cell epulis may be associated with the degradation of the organic bone matrix [17]. The

Figure 3
Expression of p53 proteins in giant-cell epulis, (x800 magnification) A – Giant cells p53 “-”, B – Giant cells p53 “+”, C – Fibroblastic stroma p53 “-”

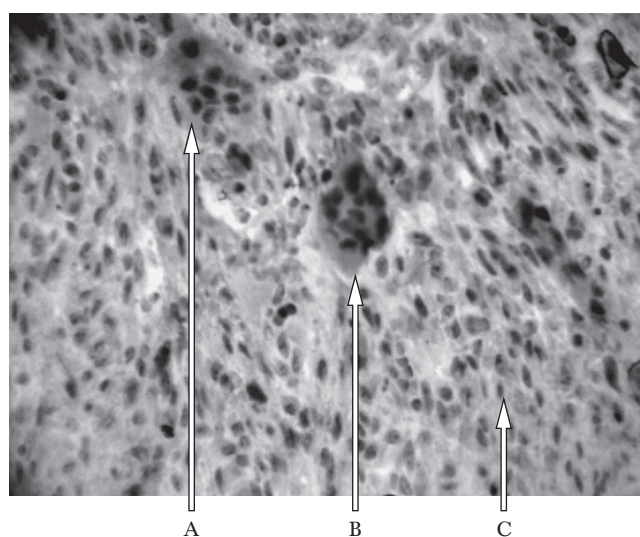


Figure 4
Expression of OPN proteins in giant-cell epulis (x800 magnification) A – Fibroblastic stroma OPN “-”, B – Areas of haemorrhages, C – Giant cells OPN “+”

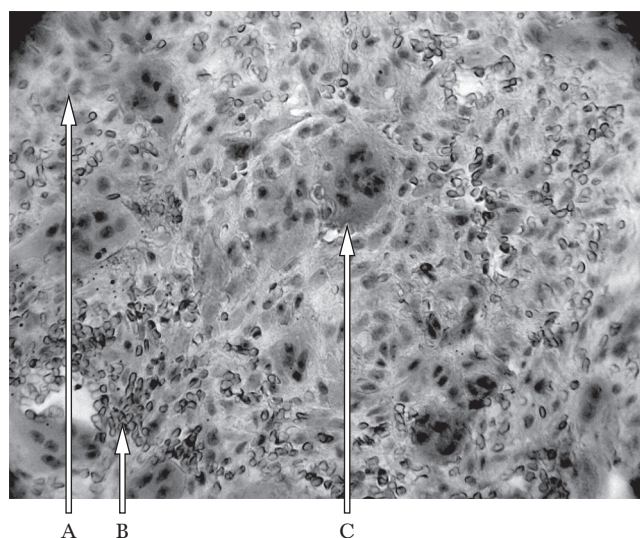
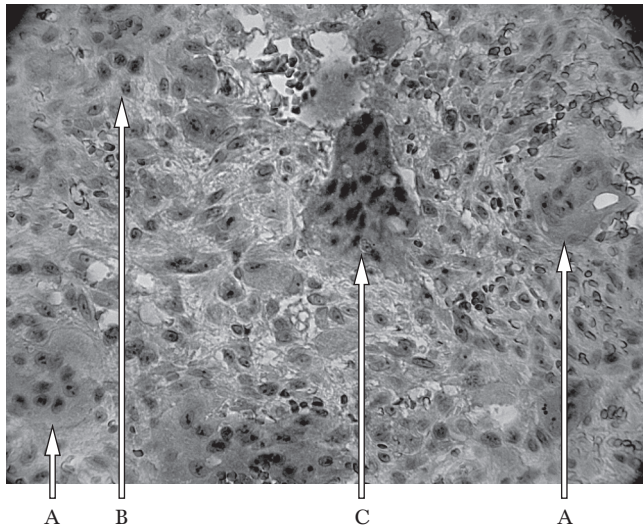


Figure 5

Expression of MMP-1 proteins in giant-cell epulis (x800 magnification) A – Giant cells MMP-1 “+”, B – Fibroblastic stroma MMP-1 “-”, C – Giant cells MMP-1 “+++”



present study showed that giant-cell and stromal cells studied produced MMP-1. However, expression was higher in the parenchyma. It is believed that these stromal enzymes potentiate the action of MMPs produced by the parenchyma. This fact supports the view of an interaction between neoplastic cells and the adjacent stroma as demonstrated in some experiments [18]. This strategic interaction permits neoplastic cells to induce stromal cells to produce proteolytic enzymes that act in synergism with tumor enzymes, thus facilitating the processes of invasion in bone matrix.

We have previously shown that osteopontin expressive epulis. The osteopontin pattern of distribution was in the form of diffuse granular cytoplasmic reactivity and, more rarely, of paranuclear dots in the Golgi area [19]. This increased in association with interstitial macrophage infiltration [20]. Kelly L et al [21] demonstrated a pattern of focal strong osteopontin expression in association with very focal macrophage accumulations. This may reflect localized ischemia induced by the vasoconstrictive effects. Increased osteopontin levels have been detected in the plasma or serum derived from patients with a number of solid neoplasms, head and neck [22]. Thus, OPN expression appears to affect the biological behavior of giant-cell epulis, and this effect depends on the anatomical origin of the tumor. These results indicate that determination of the prognosis of patients with giant-cell epulis should consider OPN expression.

Conclusion

MGMT, MMP-1, p53 and OPN may play important roles in the biology of giant-cell epulis. Presence of reparative enzyme MGMT indicate benign variant of tumor process due to the possibility reparation pathologically alkylated guanine. MMP-1 in giant-cell epulis may help to explain invasion in bone matrix.

References

- Kramer IRH, Pindborg JJ, Shea M. Histologic typing of odontogenic tumours. 2nd ed. Berlin, Springer-Verlag 1992; p 118.
- Adornato MC, Paticoff KA. Intralesional corticosteroid injection for treatment of central giant-cell granuloma. *J Am Dent Assoc* 2001;132:186–190.
- Neville BW, Damm DD, Allen CM, Bouquet JE. Soft Tissue Tumors. In: Oral and Maxillofacial Pathology. 3rd ed. St. Louis: Saunders 2009; pp 507–563.
- Willing M, Engels C, Jesse N, Werner M, Dellling G, Kaiser E. The nature of giant cell tumor of bone. *J Cancer Res ClinOncol* 2001;127:467–474.
- Falascini S, Ciavarella D, Mazzanti R, Di Cosola M, Turco M, Escudero N, Bascones A, Lo Muzio L. Peripheral giant cell granuloma: immunohistochemical analysis of different markers. Study of three cases *Avances en odontostomatología*. 2007;23(4):189–196.
- Palacios E, Valvassori G. Giant cell reparative granuloma. *Ear Nose Throat J* 2000;79:688.
- Hoeijmakers JH. Genome maintenance mechanisms for preventing cancer. *Nature* 2001; 411:366–374.
- Giaginis C, Michailidi C, Stolakis V, Alexandrou P, Tsourouflis G, Klijanienko J, Delladetsima I, Theocharis S. Expression of DNA repair proteins MSH2, MLH1 and MGMT in human benign and malignant thyroid lesions: An immunohistochemical study. *Med Sci Monit* 2011;17(3):81–90.
- Ryan KM, Phillips AC, Karen H. Regulation and function of the p53 tumor suppressor protein. *Vouடன் Current Opinion in Cell Biology* 2001;13:332–337.
- Merry K, Dodds R, Littlewood A, Gowen M. Expression of Osteopontin mRNA by osteoclasts and osteoblasts in modelling adult human bone. *J Cell Sci* 1993; 104(4):1013–1020.
- Kelly L, Hudkins, Quoc CLE, Segerer S, Johnson RJ, Davis CL, Giachelli CM, Alpers ChE. Osteopontin expression in human cyclosporine toxicity. *Kidney International* 2001;60:635–640.
- Sutinen M, Kainulainen T, Hurskainen T, Vesterlund E, Alexander JP, Overall CM, Sorsa T, Salo T. Expression of matrix metalloproteinases (MMP-1 and -2) and their inhibitors (TIMP-1, -2 and -3) in oral lichen planus, dysplasia, squamous cell carcinoma and lymph node metastasis. *Br J Cancer* 1998;77(12):2239–2245.
- Ko LJ, Prives C P53: puzzle and paradigm. *Genes Dev* 1996;10:1054–1072.
- Sawhney M, Rohatgi N, Kaur J et al. MGMT expression in oral precancerous and cancerous lesions: correlation with progression, nodal metastasis and poor prognosis. *Oral Oncol* 2007;43:515–522.
- Delaisse JM, Engsig MT, Everts V, Ovejero MC, Ferreras M, Lund L et al. Proteinases in bone resorption: obvious and less obvious roles. *Clin Chim Acta* 2000;291:223–234.
- Ala-Aho R, Kahari VM. Collagenases in cancer. *Biochimie* 2005;87:273–286.
- Henriques CG, de Matos FR, Galvao HC, de A. Freitas R. Immunohistochemical expression of MMP-9 and VEGF in squamous cell carcinoma of the tongue. *Aguida Journal of Oral Science* 2012;54(1):105–111.
- Packer L, Pavey S, Parker A et al. Osteopontin is a downstream effector of the PI3-kinase pathway in melanomas that is inversely correlated with functional PTEN. *Carcinogenesis* 2006;27:1778–1786.
- Hudkins KL, Giachelli CM, Cui Y et al. Osteopontin expression characterization of small proteoglycans I and II, bone sialoproteins in fetal and mature human kidney. *Kidney International* 2000;60:635–640.
- Le QT, Sutphin PD, Raychaudhuri S et al. Identification of osteopontin as a prognostic plasma marker for head and neck squamous cell carcinomas. *Clin Cancer Res* 2003;9:59–67.
- Kelly SL, Sullards MC, Murphy RC et al. Regulated accumulation of desmosterol integrates macrophage lipid metabolism and inflammatory responses. *Cell* 2012; 151:138–152.
- Cappia S, Righi L, Mirabelli D et al. Prognostic role of osteopontin expression in malignant pleural mesothelioma. *Am J Clin Pathol* 2008;130:58–64.