

AB1104

ANALYSIS OF ANTINUCLEAR ANTIBODY TITERS AND PATTERNS USING HEP 2 INDIRECT IMMUNOFLUORESCENCE IN VARIOUS LIVER DISEASES

Q. Wei¹, Y. Jiang¹, M. Yang¹, J. Xie¹, M. Xiao¹, J. Gu¹. ¹The Third Affiliated Hospital of Sun Yat-sen University, Guangzhou, China

Background: Abnormal liver function can be seen in not only hepatitis B virus infection (HBV), hepatitis C virus infection (HCV), hepatic carcinoma (HCC), but also in primary biliary cirrhosis (PBC), autoimmune hepatitis (AIH), and systemic autoimmune rheumatic diseases (SARD). Antinuclear antibody (ANA) testing using indirect immunofluorescence assay (IIFA) is a common and economical method which contributes to detect SARD and autoimmune liver diseases [1].

Objectives: Our objective was to investigate ANA positivity, titers and their patterns in multiple liver diseases, including PBC, AIH, HBV, HCV, and HCC, compared to healthy controls (HC).

Methods: 2537 patients with SARD, 137 PBC cases, 57 AIH cases, 3420 HBV cases, 769 HCV cases, 268 HCC cases, and 1073 HC were retrospectively assessed. The titers and patterns of ANA were detected with the IIFA method.

Results: ANA positivity rate was considerably discernible between these diseases, which is 90.1% in SARD, 93.4% in PBC, 49.1% in AIH, 19.1% in HBV, 13.9% in HCV and 23.5% in HCC. Moreover, only 4.9% of HCC cases, 2.5% of HBV patients and 1.6% of HCV patients had an ANA titer $\geq 1:320$. The mixed pattern which composed of at least two patterns majorly lied in PBC. AC-15 and AC-21 was frequently related to liver diseases; the former pattern was more frequently found in AIH (84.2%) and PBC (8.8%), and the latter pattern was easily seen in PBC (62.2%) and HCC (22.6%). The positive rate of ANA in HC was 12.2% and its major pattern was AC-2.

Conclusion: There are differences in ANA positivity among patients with SARD and various liver diseases. Some mixed patterns may provide important evidence for the diagnosis of PBC. Clinicians should pay attention to ANA patterns and titer during the interpretation of this test.

References:

- [1] Damoiseaux J, Andrade L, Carballo OG, Conrad K, Francescantonio P, Fritzler MJ, Garcia DLT, Herold M, Klotz W, Cruvinel WM, Mimori T, von Muhlen C, Satoh M, Chan EK, (2019) Clinical relevance of HEP-2 indirect immunofluorescent patterns: the International Consensus on ANA patterns (ICAP) perspective. ANN RHEUM DIS 78: 879-889

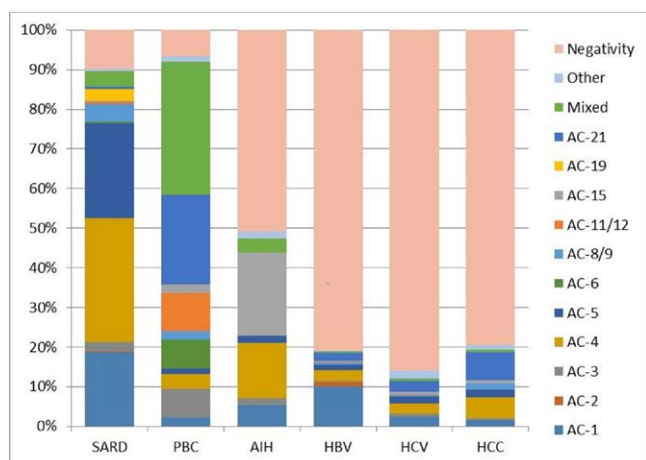


Figure 1. The Proportion of Each ANA Pattern Exhibited in Different Diseases and HCANA: antinuclear antibodies; HC: healthy controls; PBC: primary biliary cirrhosis; AIH: autoimmune hepatitis; SARD: systemic autoimmune rheumatic diseases; HBV: hepatitis B virus infection; HCV: hepatitis C virus infection; HCC: hepatic carcinoma.

Acknowledgments: None.

Disclosure of Interests: None declared

DOI: 10.1136/annrheumdis-2020-eular.726

AB1105

ASSOCIATION BETWEEN CAPILLAROSCOPIC ALTERATIONS AND ANGIOGENIC AND TISSUE REMODELING FACTORS IN PATIENTS WITH DERMATOMYOSITIS.

V. Kachkovska¹, A. Kovchun¹, O. Orlovskiy¹, L. Prystupa¹. ¹Sumy State University, Sumy, Ukraine

Background: During last years we are seeking for new biomarkers of early or even preclinical diseases stages, precise definition of disease activity and accurate prediction of the disease course as well as biomarkers of treatment efficiency. Nailfold capillaroscopy (NFC) considering as a method for early or even preclinical diagnostic tool for systemic scleroderma, at the same time there is enough data that dermatomyositis (DM) characterized with similar NFC changes along with other idiopathic inflammatory myopathies (IIM) due to the peripheral vascular involvement.

Objectives: The goal of our research was aimed to analyze possible association between capillaroscopic alterations and angiogenic, tissue remodeling factors in patients with DM.

Methods: 44 patients with DM were examined and included in the study. NFC we performed using *Dino-Lite CapillaryScope with 200 magnification*. We assessed nailfold capillary density (NCD), presence of microhemorrhages, giant, dilated and ramified capillaries, scleroderma patterns (defined as an early, active or late pattern) and neovascular pattern (defined as an active and late scleroderma patterns). We use Manual Muscle Testing 8 (MMT8), Health Assessment Questionnaire (HAQ), Myositis Disease Activity Assessment Tool (MDAAT), Cutaneous Dermatomyositis Disease Area and Severity Index (CDASI), physician's VAS, patient's VAS, serum muscle enzymes levels to assess disease activity. The level of transforming growth factor alpha (TGF- α) and vascular endothelial growth factor (VEGF) were assayed by the enzyme immunoassay system in the blood serum. We divided patients into 4 groups: 1st group – 17 DM patients with early NFC scleroderma pattern, 2nd group included 11 DM patients with active NFC scleroderma pattern, 3rd group – 6 DM patients with late NFC scleroderma pattern and 4th group included 10 DM patients with no any significant NFC alterations.

Results: We didn't find any significant difference of the VEGF level between examined groups, though the level of VEGF in the 1st group was $-473,65 \pm 48,24$ pg/ml, 2nd – $412,89 \pm 106,24$ pg/ml, 3rd – $283,0 \pm 71,93$ pg/ml, 4th – $305,9 \pm 45,89$ pg/ml ($p=0,12$, $F=2,06$), however at the same time we compare the level of VEGF between patients with long disease duration and newly onset disease and VEGF was higher among newly onset active DM patients – $465,32 \pm 54,54$ pg/ml VS $324,96 \pm 41,16$ pg/ml ($p=0,042$, $F=4,365$). The level of TGF- α in the 1st group was $100,82 \pm 8,98$ ng/ml, 2nd – $65,78 \pm 9,21$ ng/ml, 3rd – $56,9 \pm 5,01$ ng/ml, 4th – $65,5 \pm 10,2$ ng/ml, though it was significantly higher in the 1st group patients ($p=0,002$, $F=5,88$).

Conclusion: According to our results we can assume that VEGF and TGF- α could be applied as biomarkers of disease activity and duration, however more data is required.

Disclosure of Interests: None declared

DOI: 10.1136/annrheumdis-2020-eular.6329

AB1106

DO TENDER JOINTS IN PSORIATIC ARTHRITIS REFLECT INFLAMMATION ON ULTRASOUND?

S. Kamp Felbo¹, C. Wiell¹, M. Østergaard¹, H. B. Hammer², M. Szkudlarek³, L. Terslev¹. ¹Rigshospitalet, Copenhagen Center for Arthritis Research, Center of Rheumatology and Spine Diseases, Glostrup, Denmark; ²Diakonhjemmet Hospital, Dept. of Rheumatology, Oslo, Norway; ³Zealand University Hospital, Dept. of Rheumatology, Køge, Denmark

Background: Ultrasound (US) is a sensitive method for evaluating inflammation in arthritis, but several studies have shown discrepancies in inflammatory findings on US examination and clinically assessed disease activity, both in rheumatoid arthritis (RA) and psoriatic arthritis (PsA) (1, 2). In RA, a recent study found that swollen but not tender joints reflect synovitis detected by US (3). In PsA tenderness without joint swelling is a frequent finding.

Objectives: To investigate the agreement of clinical joint evaluation (swollen joints (SJ) and tender joints (TJ)) and US findings of inflammation in PsA assessing joints and periarticular tissue involvement (e.g. joint capsule, adjacent ligaments etc.).

Methods: We included 42 patients with active PsA (min. 3 swollen and tender joints) and hand involvement (min. 1 finger joint and/or 1 finger with dactylitis). All patients had US examination performed by one examiner (blinded to clinical data) using a high-end US scanner with a high-frequency 14 MHz linear transducer. 2-5th metacarpophalangeal- (MCP), proximal and distal interphalangeal (PIP and DIP) and 1-5th metatarsophalangeal (MTP) -joints were assessed by greyscale (GS) and power Doppler (PD) mode, bilaterally. Synovitis was scored for GS and PD change (0-3) according to OMERACT guidelines (4), PIP and DIP joints were additionally scored for volar synovitis (0-3) and presence of periarticular PD activity (PD activity in the joint capsule and/or adjacent structures). SJ (76) and TJ (78) counts were performed by an experienced rheumatologist blinded to US findings. As prevalence of lesions was low, agreement between TJ, SJ and US was calculated using the prevalence and bias adjusted Kappa