

ORIGINAL ARTICLE

STRUCTURE OF THE KNEE ARTICULAR CARTILAGE AFTER THE FEMUR AND TIBIA EXTRA-ARTICULAR INJURY

DOI: 10.36740/WLek202108115

Artem S. Tkachenko, Olena S. Maksymova, Oleksii V. Korenkov, Andrii P. Voznyi, Gennadii F. Tkach

SUMY STATE UNIVERSITY, SUMY, UKRAINE

ABSTRACT

The aim: To study the microscopic, ultramicroscopic, and histomorphometric features of the knee articular cartilage in rats with an extra-articular injury of the femur and tibia.

Materials and methods: 60 white laboratory rats divided into three groups (I – control; II – animals with traumatic femur injury; III – animals with traumatic tibia injury) were used for the study. The light microscopy was performed by Olympus BH-2 microscope (Japan), transmission electron microscopy – by JEM-1230 microscope (Japan). SPSS software (version 17.0) was used for mathematical analysis.

Results: The more pronounced morphological changes were observed in the articular cartilage of the proximal tibial epiphysis after mechanical tibial injury. The thickness of the articular cartilage was 27.89 % less than in the control. The chondrocyte number in the superficial zone was lower by 8.94 %, intermediate zone – by 14.23 %, and deep zone – by 21.83%, compared to control. Herewith, the histological changes were mostly detected in the intermediate and deep zones of the articular cartilage of both bones. Also, some chondrocytes had deformed nuclei, hypertrophied organelles, numerous inclusions, and residual glycogen granules.

Conclusion: The extra-articular mechanical trauma of the lower limb bones leads to pathological changes in the knee articular cartilage. The structural changes include the articular cartilage thickening, the decrease in chondrocyte number, as well as chondrocyte rearrangement due to degenerative-dystrophic processes.

KEY WORDS: cartilage, knee, extra-articular, microscopy

Wiad Lek. 2021;74(8):1863-1868

INTRODUCTION

Today, the musculoskeletal pathology ranks the 3rd place in the overall morbidity structure (after cardiovascular and cancer diseases) and the 1st place among working age population [1]. The lower extremity trauma is one of the most serious injuries of the human musculoskeletal system, due to its anatomical and functional features [2]. The injuries of the knee joint account for up to 14 % of the total lesion number [3]. Herewith, the knee osteoarthritis is the third of the most common diagnoses made by general practitioners in elderly patients [4].

The main reasons leading to impairment of the integrity and structure of the knee articular cartilage are direct and indirect articular surfaces injuries (which cause the primary cartilage damage) [5]; recurrent or chronic extremities injuries (which indirectly lead to restriction of the joint functional capacity and cause the secondary cartilage damage) [6]; destructive-dystrophic diseases, such as osteoarthritis [7], osteochondritis [8], and osteonecrosis [9].

Currently, there is a lot of information about the rearrangement in the knee articular cartilage and the development of gonarthrosis due to the direct knee joint injury [5, 10, 11]. However, the studies describing the impact of extra-articular extremities injuries on the possible knee articular cartilage changes are practically absent.

Thus, the significant prevalence of lower extremities traumas among the working people, unresolved issues on

the causes and mechanisms of osteoarthritis development, as well as a lack of data on knee articular cartilage changes due to extra-articular extremities injuries have prompted us to conduct this experiment.

THE AIM

The aim of the study was to reveal the microscopic, ultramicroscopic, and histomorphometric features of the knee articular cartilage in rats with an extra-articular injury of the femur and tibia.

MATERIALS AND METHODS

Totally 60 white laboratory rats (male, age – 7-9 months) were used for the study. The experimental animals were divided into three groups: I (20 rats) – control (animals without bones trauma); II (20 rats) – animals with traumatic femur injury; III (20 rats) – animals with traumatic tibia injury.

All rats were kept according to General ethical principles of experiments on animals (Kyiv, 2001), Declaration of Helsinki (2000), European Convention for the Protection of Vertebrate Animals used for Experimental and Other Scientific Purposes (Strasbourg, 1985). Ethics and morality were not violated during the study. The rats lived under constant temperature (24-25 °C), humidity (60 ± 5) %,

and 12-hour dark-light cycle. Current cages cleaning were performed daily.

To simulate the mechanical bone trauma, we used the technique described in our previous study [12]. Surgery was performed under the ketamine (8 mg/kg) and xylazine (3 mg/kg) anesthesia. The prophylactic dose of ampicillin (7.5 mg/kg) was intramuscularly administered 30 minutes before surgery. The incisions of the soft tissues (0.8–1.5 cm long) along the margo anterior tibiae line and on the lateral surface of the thigh were made. Using the portable dental drill with sterile burs (d 1.6 mm, low speed with cooling) the port into the bone marrow was formed in the distal third of the femoral diaphysis (group II), and in the proximal third of the tibial diaphysis (group III). The wounds were closed with skin suture treated with a 3 % alcohol iodine solution. For the next 3 days after surgery, postoperative sutures were treated with a 3% alcohol iodine solution. Also, ketorolac (0.2 mg twice daily) was administered intramuscularly for analgesia.

The rats were removed from the experiment by the thiopental overdose (4 mg/100 g body weight) 30 days after trauma.

To evaluate the microscopic structure the knee joints of the injured limbs were fixed in 10 % formalin solution with subsequent demineralization in Trilon B (5 % aqueous solution). Then samples were dehydrated in alcohols of increasing concentration and poured into paraffin. The sections (thickness of 4–6 μm) from obtained knee joints were made using microtome MC-2. Hematoxylin-eosin staining was used for histology analysis. The light microscopy was performed by Olympus BH-2 microscope (Japan). Digimizer software (Version 5.3.5) was used for morphometric analysis.

The articular cartilage of both the injured and the opposite bone were studied simultaneously in each group. The following parameters were assessed: the articular cartilage thickness (μm); the surface zone thickness (μm); the intermediate zone thickness (μm); the deep zone thickness (μm); the number of chondrocyte in the surface zone (pcs); the number of chondrocyte in the intermediate zone (pcs); the number of chondrocyte in the deep zone (pcs).

The ultramicroscopic analysis was done by the transmission electron microscopy. The pieces of the articular surface of the distal femoral epiphysis and proximal tibial epiphysis were removed and fixed in 2.5 % glutaraldehyde solution with cacodylate buffer (0.2 M, pH 7.2, +4 °C) and postfixed in 1% OsO₄ solution (4 hours, +4 °C). The dehydration was done using the series of ethyl alcohol ascending concentration. After the exposure to propylene oxide, the samples were enclosed in a mixture of epoxy resins. Semi-thin sections (1 μm) stained with a 1% methylene blue solution were made and examined under the light microscope. Ultrathin sections (40–60 nm) were contrasted with uranyl acetate followed by Reynolds' lead citrate and examined using the transmission electron microscope (JEM-1230, JEOL, Japan).

SPSS software (version 17.0, USA) was used for mathematical analysis of the numerical data. Kolmogorov-Smirn-

ov criterion was used to check the normality distribution. Unpaired Student's t-test was used to evaluate the differences between two comparison groups. The P value < 0.05 was considered as significant. Data are presented as mean \pm standard deviation.

RESULTS

The articular cartilage of the distal femoral epiphysis on the 30th day after injury of the third of the femoral diaphysis (group II) was characterized by the changes mostly in the superficial and intermediate zone (Fig. 1A). The small portion of chondrocytes had the vacuolated, weakly eosinophilic, and optically bright cytoplasm. The nuclei were located eccentrically. Some chondrocytes were reduced in size. They had pyknotic nuclei, expanded perinuclear space, numerous dark basophilic inclusions concentrated on the cell periphery (Fig. 1A). Cell distribution was somewhat disturbed. Cell-free areas were observed. The demarcation line of the deep zone of articular cartilage was well visualized and showed no signs of destruction.

The articular surface of the proximal tibial epiphysis was characterized by the thinning of the articular cartilage. Cell distribution was disrupted, but the boundaries between the zones were traced (Fig. 1B). The demarcation line was well visualized. Chondrocytes with an eccentrically placed large nucleus were observed in the intermediate and deep zones. The cytoplasm of these cells was significantly expanded and contained hyperchromic inclusions. Decreased hyperchromic nuclei were observed within some chondrocytes (Fig. 1D).

On the 30th day after the injury of the proximal third of the tibial diaphysis (group III), the morphology of the articular cartilage of the proximal tibial epiphysis was characterized by greater changes in the intermediate and deep layers compared to group II (Fig. 2A). The thickness of the articular cartilage decreased much more than the thickness of the articular cartilage of distal femoral epiphysis after the femur injury. However, the boundary between the superficial and intermediate zone was well traced. In addition, in the marginal parts, there was a thickening of the synovial layer of the articular capsule visceral part due to fibrosis and edema of the extracellular matrix.

The surface area was characterized by the denser arrangement of cells with an elongated shape. Cells with enlarged and hypochromic nuclei were observed in the intermediate zone. The positional distribution of the cells was changed. The cells were placed in pairs and more densely compared to control. Chondrocyte-free areas were observed. The demarcation line of the deep zone was traced. The most pronounced changes were detected in the chondrocytes of the intermediate and deep zone. Thus, deep-zone chondrocytes had an expanded, vacuolated cytoplasm, numerous hyperchromic inclusions, and fragmented nuclei.

At the ultramicroscopic level, chondrocytes of the deep and intermediate zones of the articular cartilage marginal parts had significantly reduced size, pyknotic nuclei, reduced organelles, numerous cellular inclusions, and

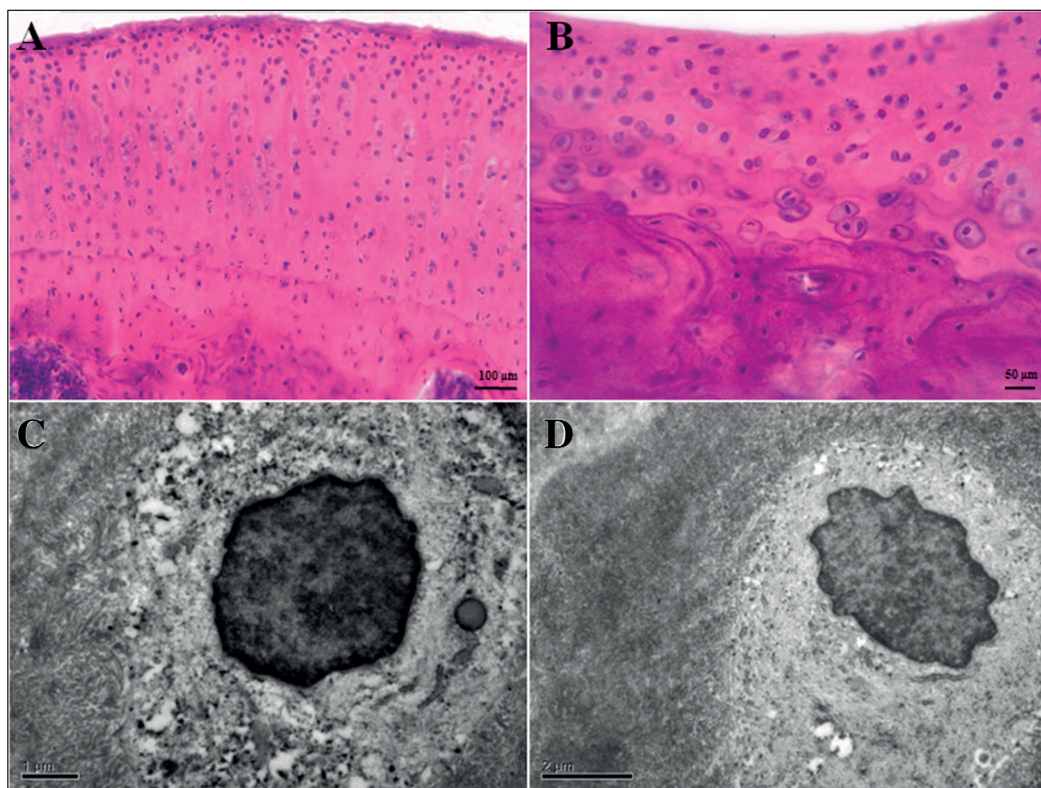


Fig. 1. A – the articular cartilage of the distal femoral epiphysis in the group II rats; B – the articular cartilage of the proximal tibial epiphysis in the group II animals; C – the chondrocyte within articular cartilage of the distal femoral epiphysis (group II); D – the chondrocyte within articular cartilage of the proximal tibial epiphysis (group II). A, B – staining with hematoxylin and eosin; C, D – transmission electronic microphotographs.

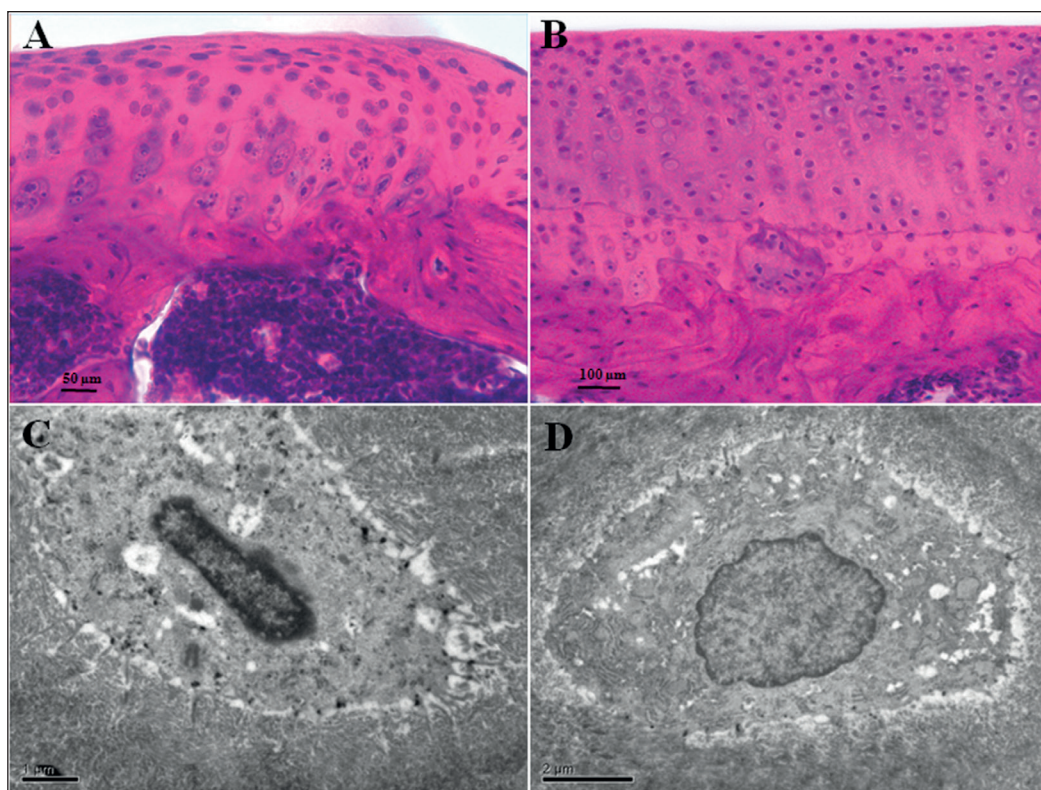


Fig. 2. A – the articular cartilage of the proximal tibial epiphysis in the group III rats; B – the articular cartilage of the distal femoral epiphysis in the group III rats; C – the chondrocyte within articular cartilage of the proximal tibial epiphysis (group III); D – the chondrocyte within articular cartilage of the distal femoral epiphysis (group III). A, B – staining with hematoxylin and eosin; C, D – transmission electronic microphotographs.

residual glycogen granules (Fig. 2C). At the same time, plasmalemma and cell processes were well visualized. A rim of the matrix enlightenment due to cell shrinkage was observed around the cell membrane.

The articular cartilage of the distal femoral epiphysis of group III rats was characterized by the changes mostly

in the intermediate zone (Fig. 2B). Cell-free areas and areas of matrix rarefaction were revealed. But the vertical distribution of cells was preserved. On ultramicroscopic examination, chondrocytes had a preserved shape and cytoplasmic processes. The nuclei were placed in the center of the cells and contained euchromatin. The parts of

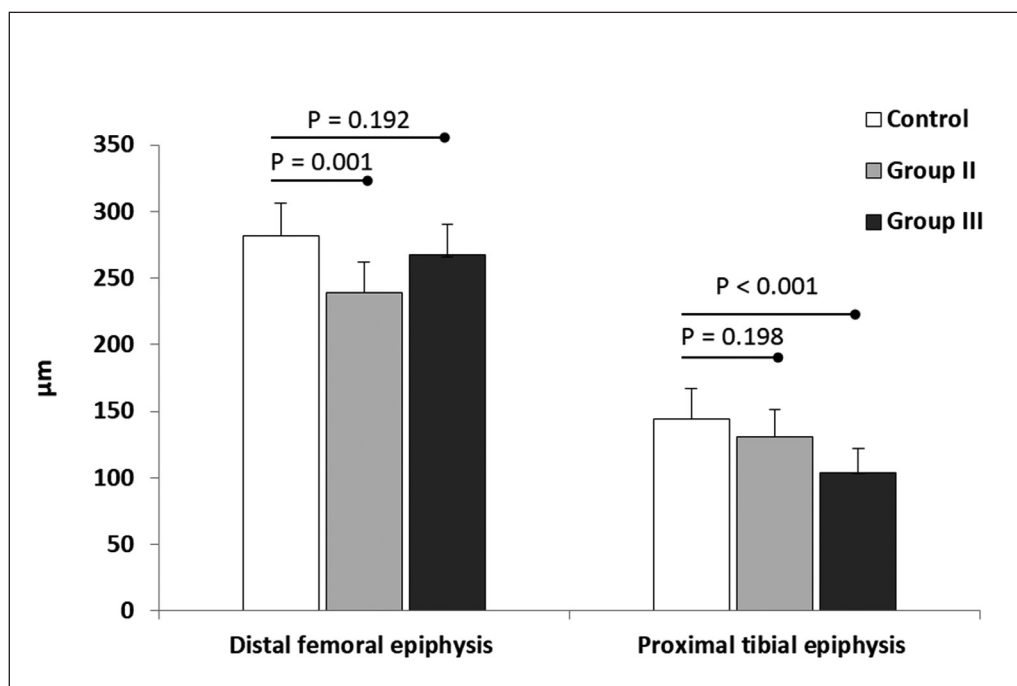


Fig. 3. The thickness of the femur and tibia articular cartilage in the control and experimental animals.

Table I. The layers thickness of the knee articular cartilage in rats of different groups (µm).

		Control (n = 20)	Group II (n = 20)	Group III (n = 20)
Superficial zone	Distal femoral epiphysis	26.14 ± 4.9	19.08 ± 3.3 $P_1 = 0.001$	24.28 ± 4.6 $P_2 = 0.324$
	Proximal tibial epiphysis	16.78 ± 2.8	15.55 ± 2.6 $P_1 = 0.393$	11.71 ± 1.9 $P_2 < 0.001$
Intermediate zone	Distal femoral epiphysis	205.04 ± 32.3	174.03 ± 28.4 $P_1 = 0.035$	194.65 ± 31.1 $P_2 = 0.456$
	Proximal tibial epiphysis	88.87 ± 26.4	80.37 ± 23.4 $P_1 = 0.473$	62.18 ± 18.2 $P_2 = 0.017$
Deep zone	Distal femoral epiphysis	50.58 ± 9.1	46.17 ± 7.9 $P_1 = 0.265$	48.24 ± 9.5 $P_2 = 0.096$
	Proximal tibial epiphysis	38.19 ± 4.9	34.26 ± 5.1 $P_1 = 0.579$	29.93 ± 3.8 $P_2 = 0.001$

Note: n – number of rats; Group II – animals with defect in the distal third of the femoral diaphysis; Group III – animals with defect in the proximal third of the tibial diaphysis; P_1 – difference between control and group II; P_2 – difference between control and group III.

the endoplasmic reticulum were expanded but contained nonchanged ribosomes (Fig. 2D).

The thickness of the articular cartilage of the distal femoral epiphysis in group II rats was less than in the control group by 15.12 % ($P = 0.001$) (Fig. 3). The thickness of the superficial zone decreased by 26.55 % ($P = 0.001$), the intermediate zone – by 15.19 % ($P = 0.035$), and the deep zone – by 8.57 % ($P = 0.265$) (Table I). The number of chondrocyte in the superficial zone decreased by 5.22 % ($P = 0.158$), in the intermediate zone – by 8.58 % ($P = 0.103$), in the deep zone – by 15.56 % ($P = 0.027$) compared to control rats (Table II).

The thickness of the articular cartilage of the proximal tibial epiphysis in group II rats decreased by 9.23 %

($P = 0.198$) compared to control (Fig. 3). The thickness of the superficial zone decreased by 7.38 % ($P = 0.324$), the intermediate zone – by 9.48 % ($P = 0.456$), and the deep zone – by 9.35 % ($P = 0.096$) (Table I). The chondrocyte number in the superficial zone decreased by 4.31 % ($P = 0.532$), in the intermediate zone – by 6.75 % ($P = 0.021$), and in the deep zone – by 10.24 % ($P = 0.047$) compared to control (Table II).

The thickness of the articular cartilage of the proximal tibial epiphysis in group III rats was 27.89 % less than in the control ($P < 0.001$) (Fig. 3). The thickness of the superficial, intermediate and deep zones became lower by 30.25 % ($P < 0.001$), 29.98 % ($P = 0.017$), and 21.26 % ($P = 0.001$) compared to control animals (Table I). At the same time,

Table II. The chondrocyte number in different layers of the knee articular cartilage

		Control (n = 20)	Group II (n = 20)	Group III (n = 20)
Superficial zone	Distal femoral epiphysis	103.3 ± 8.3	97.9 ± 8.1 P ₁ = 0.158	97.8 ± 8.2 P ₂ = 0.153
	Proximal tibial epiphysis	55.6 ± 11.1	52.8 ± 8.5 P ₁ = 0.532	50.6 ± 10.0 P ₂ = 0.302
Intermediate zone	Distal femoral epiphysis	286.9 ± 37.8	261.3 ± 28.2 P ₁ = 0.103	268.8 ± 32.2 P ₂ = 0.264
	Proximal tibial epiphysis	174.6 ± 9.6	162.9 ± 10.9 P ₁ = 0.021	149.7 ± 11.6 P ₂ < 0.001
Deep zone	Distal femoral epiphysis	60.1 ± 9.3	50.7 ± 8.1 P ₁ = 0.027	52.2 ± 7.6 P ₂ = 0.052
	Proximal tibial epiphysis	51.2 ± 5.9	45.9 ± 5.2 P ₁ = 0.047	39.6 ± 6.3 P ₂ < 0.001

Note: n – number of rats; Group II – animals with defect in the distal third of the femoral diaphysis; Group III – animals with defect in the proximal third of the tibial diaphysis; P₁ – difference between control and group II; P₂ – difference between control and group III.

the chondrocyte amount in the superficial zone decreased by 8.94 % (P = 0.302), intermediate zone – by 14.23 % (P < 0.001), and deep zone – by 21.83% (P < 0.001) (Table II).

The total thickness of the articular cartilage of the distal femoral epiphysis in group III animals was 5.17 % (P = 0.192) less than in the control (Fig. 3). The thickness of the superficial, intermediate and deep zones decreased by 7.11 % (P = 0.393), 5.08 % (P = 0.473) and 4.81 % (P = 0.579), respectively (Table I). The number of chondrocyte in the superficial zone decreased by 5.33 % (P = 0.153), intermediate zone – by 6.12 % (P = 0.264), and deep zone – by 12.86 % (P = 0.052) (Table II).

DISCUSSION

The obtained results showed that extra-articular mechanical injury of the lower limb bones leads to pathological changes in the articular cartilage of the knee joint. We found that 30 days after the trauma of the tibial and femoral diaphysis the more pronounced changes occurred in the articular cartilage of the proximal tibial epiphysis. Herewith, the structural changes were mostly detected in the intermediate and deep zones of the articular cartilage of both bones.

To date, there are no similar morphological studies. However, Lindau et al. have revealed that extra-articular radial fractures in young non-osteoporotic patients were linked to space narrowing in the radiocarpal joints 1 year after injury [13]. The authors suggested that subchondral hematoma may be the main cause of articular cartilage impairment due to extra-articular bone damage.

It's known that instability of the joint leads to inadequate loading forces, disruption of chondrocyte metabolism, and consequence cartilage degradation [14]. It is also shown, that abnormal mechanical pressure results in chondrocyte metabolic activation and releasing of inflammatory cytokines [15]. Few studies demonstrated that cartilage degradation in mice with

anterior cruciate ligament injury is associated with elevated expression of apoptotic (caspase-3), inflammatory (IL-6, IL-1β) and catabolic (MMP-13) proteins in chondrocytes [16, 17]. In our experiment, the most changes have consisted of articular cartilage thickening, reduction of chondrocyte number, and impairment of cell distribution. Isaac et al. found that blunt trauma of the knee joint leads to thickening and microcracks of tibial subchondral bone, but not to changes in cartilage thickness [18]. However, Nicoliche et al. revealed that zymosan-induced knee osteoarthritis was associated with increased chondrocyte number and cartilage layers thickening [19].

Today it is believed that chondrocyte apoptosis is an integral part of morphological changes due to cartilage mechanical injury [20]. In our study, we did not observe necrotic changes and chondrocyte apoptosis. The changes within cells and cartilage matrix had the degenerative-dystrophic character. Though, Mutsuzaki et al. showed that knee immobilization after anterior cruciate ligament insertion leads to chondrocyte apoptosis activation as well as to thinning of cartilage layers [21].

This is the first report about the effect of femur and tibia extra-articular injury on the structure of the knee articular cartilage. The specific morphological changes in the knee articular cartilage in response to mechanical injury of the lower limb bones have been established. However, our experiment has important limitations that have to be taken into account. Methods of immunohistochemistry, scanning, and confocal microscopy were not used. Also, molecular-genetic techniques in order to evaluate specific protein expression (e.g. inflammatory cytokines, matrix metalloproteinases) were also not applied.

CONCLUSIONS

Thus, extra-articular mechanical trauma of the lower limb bones results in pathological changes of the knee articular cartilage. The structural changes include the articular cartilage thickening, the decrease in chondrocyte number,

as well as chondrocyte rearrangement due to degenerative-dystrophic processes. 30 days after the injury of the tibial and femoral diaphysis the more pronounced changes occurred in the articular cartilage of the proximal tibial epiphysis. Herewith, the articular surface of the femur was the most stable.

REFERENCES

- Ge H., Sun X., Liu J et al. The Status of Musculoskeletal Disorders and Its Influence on the Working Ability of Oil Workers in Xinjiang, China. *Int J Environ Res Public Health*. 2018;15(5). pii: E842. doi: 10.3390/ijerph15050842.
- Lyndin M., Gluschenko N., Sikora V. et al. Morphofunctional features of articular cartilage structure. *Folia medica Cracoviensia*. 2019;59(3):81-93. doi: 10.24425/fmc.2019.131138.
- Xu Yu, Li Q., Shen T. et al. Early Diagnosis and Treatment of Trauma in Knee Joints Accompanied With Popliteal Vascular Injury. *Int J Clin Exp Med*. 2015;8(6):9421-9429.
- Bruyère O., Cooper C., Pelletier J. et al. An algorithm recommendation for the management of knee osteoarthritis in Europe and internationally: A report from a task force of the European Society for Clinical and Economic Aspects of Osteoporosis and Osteoarthritis (ESCEO). *Semin Arthritis Rheum*. 2014;44(3):253-263. doi: 10.1016/j.semarthrit.2014.05.014.
- Bollen S. Epidemiology of knee injuries: diagnosis and triage. *The British Journal of Sports Medicine*. 2000;34:227-228.
- Qi S., Guo Xin F., Li X. et al. Relationship Between Femur and Femoral Arteries for Identifying Risk Factors for Vascular Injury. *Med Sci Monit*. 2017;23:1733-1740.
- Hada S., Kaneko H., Sadatsuki R. et al. The degeneration and destruction of femoral articular cartilage shows a greater degree of deterioration than that of the tibial and patellar articular cartilage in early stage knee osteoarthritis: a cross-sectional study. *Osteoarthritis and Cartilage*. 2014;22(10):1583-1589.
- Zanon G., Vico G., Marullo M. Osteochondritis dissecans of the knee. *Joints*. 2014; 2(1): 29-36.
- Karim A., Cherian J., Jauregui J. et al. Osteonecrosis of the knee: review. *Ann Transl Med*. 2015;3(1):6. doi: 10.3978/j.issn.2305-5839.2014.11.13]
- Chubinskaya S., Haudenschild D., Gasser S. et al. Articular Cartilage Injury and Potential Remedies. *J Orthop Trauma*. 2015;(12):S47-52. doi: 10.1097/BOT.0000000000000462.
- Tan S., Kripesh A., Chan C. et al. Gender Differences in Intra-articular and Extra-articular Injuries Associated With Acute Anterior Cruciate Ligament Ruptures. *J Knee Surg*. 2019;32(7):616-619. doi: 10.1055/s-0038-1666828.
- Dudchenko Ye., Maksymova O., Pikaliuk V. et al. Morphological Characteristics and Correction of Long Tubular Bone Regeneration under Chronic Hyperglycemia Influence. *Anal Cell Pathol (Amst)*. 2020;5472841. doi: 10.1155/2020/5472841.
- Lindau T., Adlercreutz C., Aspenberg P. Cartilage Injuries in Distal Radial Fractures. *Acta Orthop Scand*. 2003;74(3):327-331. doi: 10.1080/00016470310014265.
- Chaudhari A., Briant P., Bevil S. et al. Knee kinematics, cartilage morphology, and osteoarthritis after ACL injury. *Med Sci Sports Exerc*. 2008;40:215-222. doi: 10.1249/mss.0b013e31815cbb0e.
- Attur M., Dave M., Akamatsu M. et al. Osteoarthritis or osteoarthrosis: the definition of inflammation becomes a semantic issue in the genomic era of molecular medicine. *Osteoarthritis Cartilage*. 2002;10:1-4. doi: 10.1053/joca.2001.0488.
- Papathanasiou I., Michalitsis S., Hantes M. et al. Molecular changes indicative of cartilage degeneration and osteoarthritis development in patients with anterior cruciate ligament injury. *BMC Musculoskelet Disord*. 2016;17:21. doi: 10.1186/s12891-016-0871-8.
- Chinzei N., Brophy R., Duan X. et al. Molecular Influence of Anterior Cruciate Ligament Tear Remnants on Chondrocytes: A Biologic Connection between Injury and Osteoarthritis. *Osteoarthritis Cartilage*. 2018;26(4): 588-599. doi: 10.1016/j.joca.2018.01.017.
- Isaac D., Meyer E., Kopke K. et al. Chronic Changes in the Rabbit Tibial Plateau Following Blunt Trauma to the Tibiofemoral Joint. *J Biomech*. 2010;43(9):1682-1688. doi: 10.1016/j.jbiomech.2010.03.001.
- Nicoliche T., Maldonado D., Faber J. et al. Evaluation of the Articular Cartilage in the Knees of Rats With Induced Arthritis Treated With Curcumin. *PLoS One*. 2020;15(3):e0230228. doi: 10.1371/journal.pone.0230228.
- Zamli Z., Sharif M.. Chondrocyte apoptosis: a cause or consequence of osteoarthritis? *Int J Rheum Dis*. 2011;14:159-166. doi: 10.1111/j.1756-185X.2011.01618.x.
- Mutsuzaki H., Nakajima H., Sakane M. Extension of knee immobilization delays recovery of histological damages in the anterior cruciate ligament insertion and articular cartilage in rabbits. *J Phys Ther Sci*. 2018;30(1):140-144. doi: 10.1589/jpts.30.140.

The present study is the part of the scientific project “Morphofunctional aspects of organism homeostasis disturbance”, supported by Ministry of Education and Science of Ukraine (no. 0118U006611).

ORCID and contributionship:

Artem S. Tkachenko: 0000-0002-0362-8544 ^{A,D}
 Olena S. Maksymova: 0000-0002-1470-1700 ^{A,C}
 Oleksii V. Korenkov: 0000-0002-1314-5642 ^{B,C}
 Andrii P. Voznyi: 0000-0002-4765-9430 ^{B,E}
 Gennadii F. Tkach: 0000-0002-6482-4792 ^{E,F}

Conflict of interest:

Authors declare no conflict of interest

CORRESPONDING AUTHOR

Artem S. Tkachenko

Sumy State University
 2, Rymskogo-Korsakova st., 40007 Sumy, Ukraine
 tel: +380996754283
 e-mail: artemstkachenko@ukr.net

Received: 30.06.2020

Accepted: 02.06.2021

A – Work concept and design, **B** – Data collection and analysis, **C** – Responsibility for statistical analysis, **D** – Writing the article, **E** – Critical review, **F** – Final approval of the article