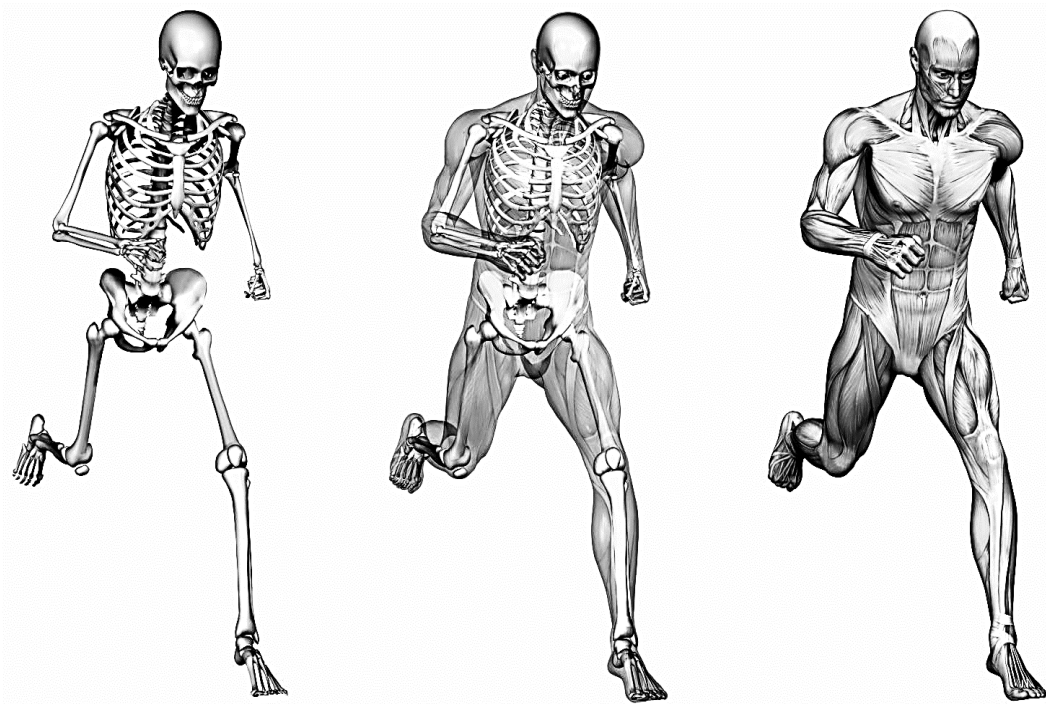


# SUPPORTING and LOCOMOTOR APPARATUS

Study guide



Ministry of Education and Science of Ukraine  
Ministry of Health of Ukraine  
Sumy State University

# **SUPPORTING and LOCOMOTOR APPARATUS**

Study guide

*Edited by V. I. Bumeister*

Recommended by the Academic Council of Sumy State University



Sumy  
Sumy State University  
2022

**UDC 611.71/.75(075.8)**

Author:

V. I. Bumeister, Doctor of Biological Sciences, professor of Sumy State University;  
O. S. Yarmolenko, PhD, Associate Professor of Sumy State University;  
O. O. Prykhodko, PhD, Associate Professor of Sumy State University;  
L. G. Sulim, Senior Lecturer of the Sumy State University;  
T. P. Teslyk, PhD, Assistant of the Sumy State University;  
A. O. Ponyrko, PhD, Assistant of the Sumy State University;  
S. M. Dmitruk, PhD, Associate Professor of the Sumy State University;  
V. Yu. Iliashenko, Assistant of the Sumy State University

Reviewers:

*O. H. Popadinets* – Doctor of Medical Sciences, professor of Ivano-Frankivsk National Medical University;  
*A. M. Romanuk* – Doctor of Medical Sciences, professor of Sumy State University

*Recommended for publication  
by the Academic Council of Sumy State University  
as a study guide  
(minutes № 9 of 10.02.2022)*

S 93 **Supporting** and locomotor apparatus : study guide / V. I. Bumeister et al. ;  
edited by V. I. Bumeister. – Sumy : Sumy State University, 2022. – 207 p.

ISBN 978-966-657-897-9

This manual is intended for the students of medical higher educational institutions of IV accreditation level, who study of Human Anatomy in English language.

**UDC 611.71/.75(075.8)**

ISBN 978-966-657-897-9

© Sumy State University, 2022  
© Bumeister V. I. et al., 2022

## CONTENTS

	P.
INTRODUCTION .....	4
THE EXPLANATORY NOTE .....	5
THE AIM OF THE STUDY OF THE DISCIPLINE .....	5
A SYSTEM OF ASSESSMENT .....	6
OF STUDENTS' EDUCATIONAL ACTIVITY .....	6
INTRODUCTION TO HUMAN BODY .....	8
SKELETAL SYSTEM.....	9
BONES OF THE TRUNK, THE VERTEBRAL COLUMN .....	10
THE TYPICAL VERTEBRAE.....	10
THE STERNUM .....	12
THE SKELETON OF THE UPPER LIMB .....	13
THE SKELETON OF THE LOWER LIMB .....	15
THE SKELETON OF THE HEAD .....	18
THE BONES OF THE VISCERAL CRANIUM .....	22
THE SKULL AS A WHOLE .....	24
ARTICULAR SYSTEM.....	48
THE MUSCULAR SYSTEM .....	69
GENERAL ANATOMY OF MUSCLES.....	69
MUSCLES OF THE BACK .....	71
MUSCLES OF THE CHEST.....	73
MUSCLES OF THE ABDOMEN .....	74
MUSCLES OF THE NECK (NECK MUSCLES).....	75
MUSCLES OF THE HEAD.....	77
MUSCLES OF THE UPPER LIMB.....	79
MUSCLES OF THE LOWER LIMB.....	83
HUMAN BODY FASCIA .....	98
TOPOGRAPHY OF THE UPPER LIMB .....	101
FASCIAE OF THE LOWER LIMB.....	103
TOPOGRAPHY OF THE LOWER LIMB .....	105
TEST QUESTIONS (COMPUTER) .....	122
MODULE 1 CLINICAL TASKS – SUPPORTING AND LOCOMOTOR APPARATUS.....	200
REFERENCES.....	206

## INTRODUCTION

*Human anatomy is a scientific study of the structure of the human respect to all its functions and mechanisms of its development.*

*By studying the structure of separate organs and systems in close connection with their functions, anatomy looks into a person`s organism as a unit, which develops basing on the regularities under the influence of internal and external factors during the whole process of evolution.*

*The purpose of this subject is to study the structure of organs and systems of a person, features of the body structure of the person in comparison with animals, revealing the anatomic frames of the age, sexual and individual variability, to study the adaptation of the form and structure of the organs to varying conditions of function and existence. Such functional and anatomic, evolutionary and causal treatment of the information about morphological features of an organism of a person in a course of anatomy has huge value for clinical manifestation as it promotes comprehension of the nature of a healthy and sick person.*

*This educational and methodical practical work is based on the sample of educational and working programs on human anatomy according to the credit-modular system of the organization of the educational process. It is directed toward the assistance to the students and teachers in the organization and realization of the most effective methods of studying and teaching of this subject.*

### **The study guide prepared by:**

V. I. Bumeister, Doctor of Biological Sciences, professor of Sumy State University, (introduction, the explanatory note. The bones of the skull and the articulations between them. Muscles of the head. Test questions (computer) concerning anatomy of the head).

Yarmolenko O. S., PhD, Associate Professor of Sumy State University, (the bones of the upper limb and the articulations between them. Muscles and topography of the upper limb. Test questions (computer) concerning anatomy of the upper limb).

Prykhodko O. O., PhD, Associate Professor of Sumy State University, (the bones of the lower limb and the articulations between them . Muscles of the lower limb. Test questions (computer) concerning anatomy of the lower limb).

Sulim L. G., Senior Lecturer of the Sumy State University, (the bones of the trunk. The articulations of the bones of the trunk. Muscles and topography of the neck. Test questions (computer) concerning anatomy of the neck).

Teslyk T. P., PhD, Assistant of the Sumy State University; Muscles of the chest and abdomen. Diaphragm. Topography of abdomen. Test questions (computer) concerning anatomy of the chest.

Ponyrko A. O., PhD, Assistant of the Sumy State University, (a system of assessment of students' educational activity; introduction to human body. The bones and the articulations of the foot. Muscles of the foot. Test questions (computer) concerning anatomy of the foot).

Dmitruk S. M., PhD, Associate Professor of the Sumy State University, (the bones and the articulations of the pelvic girdles. Muscles of the pelvic girdles. Test questions (computer) concerning anatomy of the pelvic girdles).

V. Yu Iliashenko, Assistant of the Sumy State University, (module 1 clinical tasks. The bones and the articulations of the hand. Muscles of the hand. Test questions (computer) concerning anatomy of the hand).

## THE EXPLANATORY NOTE

According to the curriculum, the study of human anatomy is carried out in the I–III semesters.

Human anatomy as a subject:

a) is based on the knowledge that students obtain from medical biology, histology, cytology and embryology, biophysics, Latin and is integrated with these disciplines;

b) introduces students to the basic knowledge in order to help them in future study of subjects, such as normal physiology, introduction to clinical disciplines and forms skills in order to apply knowledge on human anatomy in further study of all clinical disciplines and in the future professional practice.

The organization of the educational process is carried out on the basis of the credit-modular system according to the demands of the Bologna Process.

The credit-modular system of the organization of the educational process is a learning model which is based on the association of modular technologies of training.

The credit-modular system of the organization of the educational process is based on regular work of students in the course of the academic year.

Kinds of educational activities on human anatomy according to the curriculum are:

- a) lectures;
- b) practical classes;
- c) independent work of the students;
- d) individual work at a choice.

Themes of the lectures disclose problems of corresponding sections of human anatomy.

Practical classes provide mastering in:

- knowledge of Latin (Greek) terminology;
- knowledge of sources and mechanisms of fetal development, structures of organs and systems of human organs, clinical methods of their examination (X-ray anatomy, computer tomography, magnetic resonance tomography (MRT), ultrasonic examination, an endoscopy, etc.);

- skills in dissection, demonstration of anatomical structures on anatomical preparations, models;

- evaluation of age, sexual and specific features of a structure of a human body;

- solution of tasks which have clinical and anatomic substantiation.

An independent work provides the acquisition of the skills :

- to describe the organs anthropometrically;
- to show on specimens their parts and other structures;
- to draw diagrams and drawings about materials of a topic;
- to interpret visualized results of clinical methods of investigation (to interpret X-ray films, tomograms, etc.).

Individual educational and research work of students (ERWS) or scientific and research work of students (SRWS), at a choice, assume:

- a) preparation of reviews of scientific literature (abstract);
- b) preparation of illustrative materials on the studied themes (diagrams, drawings, etc.);
- c) making educational and museum anatomical preparations, models;
- d) carrying out of the research study within the framework of Student's Scientific Society of the department, etc.

The final modular control takes place after completion of studies on the module and includes:

- computerized objective questions, which include multiple choice questions, situational tasks, and photo copies;
- oral interview on anatomical preparations (practical skills examination).

The gained score of a student on a discipline is rated and is evaluated according to the scale as an average mark of mastering of corresponding modules according to European Credit Transfer and Accumulation System (ECTS) and the four-ball system accepted in Ukraine.

## THE AIM OF THE STUDY OF THE DISCIPLINE

The aim of the study of human anatomy – the ultimate goals are fixed on the basis of general training of a doctor in specialty according to the volume of the modules (natural science training) and become a basis for construction of the matter of the discipline. The description of the aims is formulated on the basis of skills as target tasks (actions). Based on each module specific goals

such as the certain skills, the ability (actions) and the target (tasks) providing achievement of the ultimate goal of the discipline study are formulated.

Ultimate goals of a discipline:

- to analyze the information about a human body structure, structure of systems, organs and tissues;
- to manage English and Latin (Greek) terminology according to the international anatomical nomenclature;
- to define topographic and anatomical relations of human organs and systems, master practical skills of dissection and to demonstrate the anatomical structures on the anatomical preparations;
- to interpret mechanism of prenatal and early postnatal development of human organs, variability, of organs maldevelopments;
- to interpret sexual, age and specific features of the human body structure;
- to provide interdependence and unity of structures and functions of human organs, their variability under the influence of ecological factors;
- to master skills of interpreting the results of clinical research methods (X-ray anatomy, computed tomography CT scan, magnetic resonance tomography (MRT scan, ultrasonic ultrasound examination, endoscopy, etc.);
- to define influence of social conditions and labour on the development and structure of the human organism.

#### **A SYSTEM OF ASSESSMENT OF STUDENTS' EDUCATIONAL ACTIVITY**

Evaluation is the final stage of a student's educational activity, which is to assess progress and to indicate successfulness of study and training.

The evaluation of the development of the discipline is expressed by average marks for modules on which the subject is divided.

The mark for the module is calculated as the sum of marks of the current educational activity and marks of the final control, expressed in point (200 points) scale.

#### **Module evaluation**

The module evaluation is defined as the sum of marks for current educational activity (in points) and marks of the final control (in points) which are based on assessment of theoretical knowledge and practical skills.

The maximum number of points that a student can get for each module is 200, including 120 points for the current educational activity and 80 points for the final control (general module).

#### **Evaluation of the current educational activity**

Mastering of each topic of the module by a student is estimated according to the 4 point (traditional) system. Thus all kinds of works stipulated by methodical supply for study, are taken into account.

The evaluations, which are exposed on a traditional scale, are converted into points depending on the number of practical classes in the module.

The value measurement (the price in points) of each thematic class within the module is identical and is determined by the number of practical classes in the module.

The main difference between final session (final control) and the current practical classes is that the students must show their ability to synthesize theoretical and practical knowledge that they have obtained for the module. The educational elements that were studied earlier are analyzed in morphological and functional relations as well as their role in the structure and function of the system and organism as a whole.

The final control (general module) includes two stages:

- computerized objective questions;
- oral interview on anatomical preparations.

The maximum number points, which the student can obtain from the current activity studying the module, is calculated by multiplication of points which correspond to "5" by each thematic class in the module (max. 120 points).

The minimum number of points, which the student can obtain in the module qualified for the final modular exams, is calculated by multiplying the number of points which correspond to "3" to by number of thematic classes in the module (min. 72 points).

### **The final module or examination**

The final modular examination is carried out after the study completion in the module at the end of the module.

The students must attend all practical classes and lectures that are stipulated by the curriculum and, also, they must score from studying in the module at least the minimum (see Table) to be qualified for the final module test.

The students, who attended all stipulated by the curriculum practical classes and lectures and have scored at least minimum points, are admitted to the final modular exam.

The student, who has missed some of the educational studies with good reasons (practical classes and lectures), can rework missed classes and lectures within the term with the Dean's Office permission. For students, who have missed educational studies without any good reason, the decision about reworking is made by the Dean of the faculty individually.

The final exam includes: 80 objective computer questions.



## INTRODUCTION TO HUMAN BODY

Human Anatomy is the oldest basic medical science. Anatomy (ana = up; – tomy = process of cutting) is the science of body structures and the relationships among structures. It was first studied by dissection (dis = apart; – section = act of cutting) – the careful cutting apart body structures to study their relationships. Today, a variety of imaging techniques also contribute to the advancement of anatomical knowledge.

### BODY POSITIONS

Descriptions of region or part of the human body assume that it is in a specific stance called the anatomical position. In the anatomical position, the body stands erect, the feet together, the arms to the side, and the head, eyes and palms facing forward. In the anatomical position, the body is upright.

### AXES AND PLANES OF HUMAN BODY

In order to study the spatial relations of organs and parts of the body, anatomists use universally accepted axes and planes, which are mentally drawn through the body. A sagittal plane is a vertical plane that divides the body or an organ into right and left sides. More specifically, when such a plane passes through the midline of the body or an organ and divides them into equal right and left halves, it is called a midsagittal plane or median plane. If the sagittal plane does not pass through the midline but, instead, divides the body or an organ into unequal right and left halves, it is called a parasagittal plane. A frontal plane divides the body or an organ into anterior and posterior portions. A transverse plane divides the body or an organ into superior and inferior portions. Sagittal, frontal, and transverse planes are all at right angles to each other.

### ANATOMICAL TERMINOLOGY

Scientists and health care professionals use a common language of special terms when referring to body structures and their functions. The language of anatomy has precisely defined meanings that allow us to communicate without using needless or ambiguous words.

<i>Term</i>	<i>Definition</i>
Anterior (ventral)	Toward the front of the body or body part
Posterior (dorsal)	Toward the back of the body or body part
Superior (cranial)	Uppermost part of a structure or above
Inferior (caudal)	Lowermost part of a structure or below
Medial	Near the median plane or midline of the body or os structure
Lateral	Farther from the median plane or midline of the body
Intermediate	Between two structures
Ipsilateral	On the same side of the body
Contralateral	On the opposite side of the body
Proximal	Towards the beginning, the nearest of two (or more) items
Distal	Away from the point of origin or attachment
Superficial	Toward or on the surface of the body
Deep	Down from the surface of the body: extending downward or inward
Parietal	Relating to or forming the walls or part of the walls of a bodily cavity, or similar structure
Visceral	Relating to, or located on, or among the viscera

## SKELETAL SYSTEM

(see Fig. 1– 34)

### Bone classification

1. Tubular bones are composed of spongy and compact substances forming a tube with a marrow cavity. Long tubular bones (arm bones, forearm bones, thigh bones, and leg bones) are supports and long levelers of movement. The process of endochondral ossification occurs in both epiphyses (biepiphyseal plate) but not in the diaphysis. Short tubular bones (metatarsal, metacarpal, phalanges) are short levelers of movement; an endochondral ossification occurs only in one (true) epiphysis (monoepiphyseal bones).

2. Spongy bones consist of a spongy substance covered with a thin layer of compact substance. There are long (ribs and sternum) and short (carpal, tarsal) spongy bones. This group of bones, also, includes sesamoid bones (the knee cap, the pisiform bone, the sesamoid bones of the fingers and toes). They act as accessory devices in the work of muscles, are located close to the joints but are not joined directly to the bones of the skeleton.

3. Flat bones:

a) the flat bones of the skull (frontal and parietal) perform a protective function. They have – diploe structure (consist of spongy substance lying between two bone layers, the outer and the inner), and they ossify from connective tissue;

b) the flat bone of the girdles (shoulder blades, pelvic bones) perform supportive and protective functions. Their structure is primarily spongy. Ossification occurs in cartilaginous tissue.

4. Mixed (irregular) bones (bones of the base of the skull) are formed by the fusion of several parts. They vary in the amounts of spongy and compact bones.

5. Pneumatic bones

### Bone structure

A typical long bone, for instance, the arm bone, consists of the following parts:

1. **The diaphysis** (= growing between) is the main or midsection (shaft) of a long bone, between the epiphyses.

2. **The epiphyses** (= growing over) are the distal and proximal ends of the long bone.

3. **The metaphysis** (meta = between) is the wide portion of a bone between the narrow diaphysis and the epiphyses.

4. **The articular cartilage** is a white, smooth tissue which covers the ends of bones in joints.

5. **The periosteum** (peri = around, os = bone) is the fibrous membrane of connective tissue that snugly covers the bone except at joints of long bones. The periosteum contains bone-forming cells that enable bone to grow in diameter, but not in length. It also protects the bone, assists in fracture repair, helps in nourishing bone tissue, and serves as an attachment for ligaments and tendons.

6. **The medullary cavity** (medulla = marrow) or marrow cavity is the space within the diaphysis that contains fatty yellow bone marrow in adults or red bone marrow in fetus.

7. **The endosteum** (endo = within) is a highly vascular membrane that lines the medullary cavity. It contains a thin layer of bone-forming cells and a small amount of connective tissue.

Bone tissue contains an abundant matrix of intercellular materials that surround widely separated cells. The matrix contains 25 % of water, 25 % of collagen fibres, and 50 % of crystallized mineral salts. The abundant mineral salts are hydroxyapatite, magnesium hydroxide, fluoride, and sulfate. These mineral salts are deposited in the framework formed by the collagen fibres of the matrix. Four types of cells are present in bone tissue:

1. **Osteogenic cells** (–genic = producing) are unspecialized stem cells derived from mesenchyme, the tissue from which all connective tissues are formed.

2. **Osteoblasts** (–blasts = buds) are bone-building cells. They secrete collagen fibers needed to build the matrix.

3. **Osteocytes** (–cytes = cells) mature bone cells which maintain daily metabolism of the bone tissue. Like osteoblasts, osteocytes do not undergo cell division.

4. **Osteoclasts** (–clasts = break) huge cells are concentrated in the endosteum and break down extracellular matrix (bone resorption). This is part of the normal development, growth, and repair of a bone structure.

### Compact bone tissue

Compact bone tissue contains few spaces. It forms the external layer of all bones and makes up the bulk of the diaphyses of long bones. Compact bone tissue is arranged in units called osteons or haversian systems. Blood and lymphatic vessels, and nerves from the periosteum penetrate the compact bone through transverse perforating (Volkmann's) canals. They connect with central (haversian) canals running longitudinally through the bone. Around the canals, there are concentric lamellae – rings of calcified matrix. Between them, there are small spaces – lacunae (= little lakes), which contain osteocytes. There are tiny canaliculi, radiating in all directions, which are filled with extracellular fluid. Inside the canaliculi, slender processes of osteocytes take place. The canaliculi connect lacunae with each other and with the central canals and provide multiple routes for nutrients and oxygen to reach the osteocytes, and for wastes to be diffused away. Lamellae that encircle the bone just beneath the periosteum are called outer circumferential lamellae, those that encircle the medullary cavity are called inner circumferential lamellae.

### Spongy bone tissue

Spongy bone tissue does not contain osteons. It consists of trabeculae (= little beams), an irregular latticework of thin columns of spongy bone. The macroscopic spaces between the trabeculae are filled with red bone marrow. Within each trabecula, there are osteocytes that lie in the lacunae. Radiating from the lacunae are canaliculi. Spongy bone tissue makes up most of short, flat and irregular bones, and the epiphyses of tubular bones.

### Bone formation

The process by which a bone is formed is called ossification or osteogenesis. The "skeleton" of a human embryo is composed of loose connective tissue membranes and pieces of hyaline cartilage, which are shaped like bones and are the sites where ossification occurs. It begins during the sixth or seventh week of embryonic development and follows one of two patterns:

1. **Intramembranous ossification** – the bone is formed directly on or within loose fibrous connective tissue membranes. The flat bones of the skull are formed in this way.

2. **Endochondral ossification** is a replacement of cartilage by the bone. Most bones of the body are formed in this way.

### Division of skeletal system

The human adult skeleton consists of 206 named bones, most of which are paired. The skeleton of infants and children has more than 206 bones because some of their bones fuse during life.

Bones of the adult human skeleton are divided into two principal groups: 80 bones of the axial skeleton and 126 bones of the appendicular skeleton.

### BONES OF THE TRUNK, THE VERTEBRAL COLUMN

The vertebrae, ribs and sternum are the bones of the trunk.

The vertebral column consists of 33–34 vertebrae, of which 24 are free (7 cervical, 12 thoracic and 5 lumbar); the rest (accreted) form two bones – the sacrum (5 vertebrae) and the coccyx (4-5 vertebrae).

The spine acts as an axial skeleton, which is the support of the body, protects the spinal cord which is inside the channel, and participates in the movements of the trunk and skull.

The vertebral column has bends in the sagittal plane: in the cervical and lumbar regions it is curved forward (lordosis), in the thoracic and coccyx regions it is backward (kyphosis). This form provides flexibility of the spine, and softens tremors during intense motor activity.

### THE TYPICAL VERTEBRAE

Each vertebra has following features:

1. The body or **corpus vertebrae** is its anterior part.

2. The arch or **arcus vertebrae** is a broad flat plate, which is attached to the posterior surface of the body by two pedicles (pediculi arcus vertebrae) and contributes to the formation of the vertebral foramen. A series of these foramina form the vertebral or spinal canal.

3. The vertebral processes, seven in number, are attached to the arch. They are:

a) transverse process or **processus transversus** is paired and projects laterally on each side;

b) spinous process or ***processus spinosus*** is unpaired and arises from the arch on the midline;

c) superior and inferior articular processes or ***processus articulares superiores*** and ***inferiores*** are paired and project superiorly and inferiorly. The articular processes bind notches on the posterior aspect. They are paired – ***incisurae vertebrales superiores*** and ***inferiores*** – two on each side. The inferior notch is larger. The superior and inferior vertebral notches form the intervertebral foramen when one vertebra is placed on another.

### **The cervical vertebrae C<sub>I</sub> – C<sub>VII</sub>**

The cervical vertebrae are small in size.

Each transverse process contains a transversal foramen or ***foramen transversarium***, which protects the vertebral artery. The ends of the transverse processes have anterior and posterior tubercles. The anterior tubercle of the sixth vertebra is enlarged and is called the carotid tubercle. The spinous process is short and bifid. The first and second cervical vertebrae have a specific shape.

***The first cervical vertebra*** received the name "atlas" from supporting the globe of the head. The first vertebra has no body. In the I vertebra, most of the body in the process of development moves to the II vertebra and to merge together, forming a tooth-like process – dens. The atlas consists of an anterior arch, a posterior arch, and two lateral masses. Two articular facets, superior and inferior, are present on the lateral masses. The groove for the vertebral artery (***sulcus arteriae vertebralis***) is located on the superior surface of the posterior arch.

***The second cervical vertebra or axis*** is named so because of forming the pivot upon which the first vertebra rotates. The axis has a tooth-like process – the dens. The dens has two articular surfaces: anterior and posterior.

***The seventh cervical vertebra*** has a long spinous process, and for that reason it is called ***the prominent vertebra***.

### **The thoracic vertebrae, Th<sub>I</sub> – Th<sub>XII</sub>**

The thoracic vertebrae articulate with the ribs. Their distinctive feature is the presence of articular facets for the head of the ribs, costal facets (fovea costalis) on the body of each vertebra. The transverse processes have a small

articular surface, transverse costal facet (fovea costalis processus transversus) for articulating with the tubercle of the rib. The transverse processes of the last two vertebrae lack these facets. The spinous processes are long. They are directed obliquely downwards.

Most vertebral bodies (second – ninth) have two incomplete (half) costal facets: one – on the superior edge of the vertebra (fovea costalis superior), and another – on the inferior surface (fovea costalis inferior).

The peculiar thoracic vertebrae are: the first – T1, the tenth – T10, the eleventh – T11, and the twelfth – T12.

***The first thoracic vertebra*** on each side of the body has a single entire articular facet for the head of the first rib, and a half demifacet for the upper half of the head of the second rib.

***The tenth thoracic vertebra*** has half costal demi-facet on each side above. It has no demifacet below.

***The eleventh and twelfth thoracic vertebrae*** contain the bodies which are almost similar in their form and size to the lumbar vertebra. The articular facets for the head of the ribs are located on each side of the body. The spinous process is short. The transverse processes are very short and have no articular facets for the tubercles of the ribs.

### **The lumbar vertebrae, L<sub>I</sub> – L<sub>V</sub>**

The lumbar vertebrae (5 in number) are the largest segments of the moveable part of the vertebral column, and may be characterized by the following:

- the body is large;
- the spinous processes are thick and broad, thicker inferiorly than superiorly;
- the superior articular processes are concave and look backward and inward;
- the inferior articular processes are convex, they look forward and outward;
- the transverse processes are long, slender, and are homologous with the ribs. Of the three tubercles noticed in connection with the transverse processes of the lumbar vertebrae, the superior one is connected in the lumbar region with the back part of the superior articular process and is named the mammillary process.

### **The sacral vertebrae, S<sub>I</sub> – S<sub>V</sub>**

The sacral vertebrae are connected by means of the cartilaginous tissue up to the age of 18–25 years. Then they merge together and form a single bone – the sacrum.

The sacral vertebrae or **vertebrae sacrales** consist of 5 separate pieces at an early period of life, which are united in the adult so as to form the sacrum.

The sacrum is a large triangular bone, situated in the lower part of the vertebral column, and at the upper and back part of the pelvic cavity, where it is inserted between two hip bones.

The sacrum forms with the last lumbar vertebra a prominent sacrovertebral angle, called the promontorium.

The central part of the bone projects backwards and reveals for examination an anterior and posterior surfaces, two lateral parts, a base and apex.

The anterior or pelvic surface is concave from above downward. In the middle, there are four transverse lines. At each end of the lines, there are the anterior sacral foramina, four in number on each side.

The posterior or dorsal surface is convex. Along the midline of the dorsal surface of the sacrum a median sacral crest runs, which represents the rudimentary spinous process.

The median sacral crest is formed by the fusion of the articular processes.

The paired median sacral crest ends at the top with the superior articular processes of the I sacral vertebra, and with the modified lower articular processes of the V sacral vertebra at the bottom. These processes, called the sacral horns, are used to articulate the sacrum with the coccyx. Sacral horns limit the sacral hiatus – the exit of the sacral canal.

In addition, laterally to the sacral foramina, transverse processes of sacral vertebrae form lateral sacral crest.

On the posterior surface, there are four posterior sacral foramina.

The lateral surface of the sacrum has an ear-shaped surface – the auricular surface.

The sacral canal passes inside the sacrum. The base of the sacrum is articulated with the V lumbar vertebra, and the apex with the coccyx.

The sacrum is shorter and wider in women than in men.

### **Coccygeal vertebrae Co<sub>I</sub> – Co<sub>IV-V</sub>**

Coccygeal vertebrae or vertebrae coccygea consist of four separate segments at an early period of life which are united in the adult so as to form the coccyx.

The coccyx has coccygeal cornua which are facing upward towards the sacral cornua.

Coccyx function. The front sections of the coccyx need to attach the muscles and ligaments, the pelvic diaphragm, and the organs of the genitourinary system. The coccyx plays a role in the distribution of physical load on the anatomical structures of the pelvis, serving as a fulcrum.

## **THE STERNUM**

The sternum or the breast-bone is a flat, narrow bone, situated on the anterior wall of the chest. It consists of three sections for adults.

1. **Manubrium sterni (handle)** – the broad, upper part of the sternum. It contains a jugular notch or incisura jugularis sternalis at its superior border, and lateral to jugular notch, a clavicular notch or incisura claviculae. The lateral borders are each marked above by a depression for the first costal cartilage and below by a small facet which, with a similar facet on the upper angle of the body of the sternum, forms a notch for the reception of the costal cartilage of the second rib.

The junction of the inferior border of the manubrium and the superior border of the body joint at an anteriorly protruding angle from the sternal angle or angulus sterni.

2. **Corpus sterni or the body of sternum** – the middle and the largest portion of the sternum. The lateral border of the body of the sternum has costal facets or incisurae costales for articulation with the cartilages of the ribs (7 on each side). The inferior border is narrow and articulates with the xiphoid process.

3. **The xiphoid process or processus xiphoideus** – a small cartilaginous process of the lower part of the sternum which is usually ossified in adult human. It is the smallest of the three parts. It is a small triangular cartilaginous extension from the breast bone in the skeletal system near the rib cage. It may be perforated, bifid and turned laterally.

## **The ribs**

There are usually 12 ribs on each side. They are elongated flat bones.

Classification of the ribs:

1. The anterior ends of the upper seven ribs are joined directly to the sternum by cartilages. They are the true ribs (costae verae).

2. The next three ribs (the eighth, the ninth and the tenth) are joined by their cartilages to the cartilage of the next above rib. They are the false ribs (costae spuriae).

3. The anterior ends of the eleventh and twelfth ribs lie free. Those ribs are called floating ribs (costae fluctuantes). That terminates within the abdominal muscles.

The length of the ribs increases from the first rib to the seventh rib. But then decreases again from seventh to the twelfth. The seventh rib is the longest of all, where the XI and XII ribs are the shortest.

The ribs consist of two parts:

- the posterior part is formed by the rib bone (os costale);
- the anterior part or the rib, cartilage (cartilago costalis).

Each typical rib consists of:

- the head of the rib (caput costae), which has an articular facet separated by a ridge. The head of the rib articulates with the vertebral bodies. The facet of the first, eleventh and twelfth ribs does not have a separating ridge;
- the neck of the rib (collum costae) is the flattened part;
- the tubercle of the rib carries a facet for joining with the articular surface of the transverse process of the corresponding vertebra;
- the shaft of the rib or corpus costae is a part between the anterior and posterior ends of the bony part of the rib;
- the angle of the rib is situated lateral to the tubercle and is located posteriorly on the shaft;
- a costal groove or sulcus costae is detectable on the inferior border of the inner surface of the rib.

The first rib has the following features:

- the superior and inferior surfaces;
- the superior surface has the scalene tubercle, which serves for insertion of the scalenus anterior muscle;

- the groove for the subclavian artery (sulcus a. subclaviae) is located behind scalene tubercle;
- the groove for the subclavian vein (sulcus v. subclaviae) is anterior to the scalene tubercle;
- the angle and the tubercle coincide.

## **THE SKELETON OF THE UPPER LIMB**

The skeleton of the upper limbs is divided into bones of the shoulder girdle (clavicle and scapula) and bones of the free part of the upper limb (bones of the arm – humerus, bones of the forearm – ulna and radius, the bones of the hand).

### **The bones of the shoulder girdle**

#### **The clavicle**

The clavicle (collarbone) is the single bone which is fastening the upper limb to the skeleton of the trunk. The body (shaft) and two ends are distinguished in it. The thickened medial, or sternal end has an articular surface for uniting with the sternum. The lateral or acromial end has a flat articular surface for articulating with the acromial process of the scapula. The conoid tubercle and trapezoid line are on the inferior surface of the acromial end. The shaft of the clavicle is curved so that its medial part is convex anteriorly, while the lateral part is convex posteriorly.

#### **The scapula**

The scapula (shoulder blade) is a flat triangular bone which is lying on the posterior surface of the thoracic cage in the space between the second and seventh ribs. According to the shape of the bone, three borders are distinguished in it: the medial, the lateral and the superior border. There is the scapular notch on the superior border. Three borders meet at three angles: inferior, superior and lateral. The lateral angle is broad and bears the articular glenoid cavity. The edge of the cavity is separated from the rest of the scapula by a constriction – the neck of the scapula. Above the superior edge of the cavity, there is the supraglenoid tubercle, and below the inferior edge of the cavity, there is the infraglenoid tubercle. The coracoid process arises from the superior border of the scapula in the vicinity of the glenoid cavity. The anterior costal surface of the

scapula forms a hollow depression, called the subscapular fossa. The spine of the scapula projects from the dorsal surface and divides it into two fossae – the supraspinous and the infraspinous. The spine of the scapula stretches laterally and proceeds with the acromion. The acromion has the articular facet for articulation with the acromial end of the clavicle.

### **Bones of the free upper limb**

The bones of the upper limb consist of the humerus, two forearm bones and the bones of the hand.

#### **The humerus**

The humerus is a long tubular bone. It has diaphysis and two epiphyses: proximal and distal. On the proximal epiphysis, there is a spherical head (caput humeri) which articulates with the glenoid cavity of the scapula. The head is separated from the rest of the bone by anatomical neck. Directly below it, there are two tubercles: the greater and lesser ones. Bony crests run downward from the tubercles. They form the lateral lip of the bicipital groove (crista tuberculi majoris) and the medial lip of the bicipital groove (crista tuberculi minoris). The intertubercular groove passes between both tubercles and crests. The part of the humerus, directly below the tubercles at the junction with the diaphysis, is called the surgical neck (where fractures often occur). The upper part of the body of the humerus has cylindrical outlines, but its lower part has a distinctly trihedral shape, in which a posterior surface, an anterolateral surface, and anteromedial surface are distinguished. Two anterior surfaces are separated from the posterior one by lateral and medial borders. Almost in the middle of the shaft, on its anterolateral surface, there is the deltoid tuberosity. A sloping, spiral, shallow groove of the radial nerve passes behind the tuberosity on the posterior surface of the body.

On the widened distal part of the humerus, there is the condyle, which consists of the medial trochlea (it articulates with the ulna) and the capitulum, laterally, for articulation with the radius. The condyle has two projections on its sides: the medial and lateral epicondyles, which are preceded with the medial and lateral borders.

There are two fossae above the trochlea. One, the coronary fossa, is in front; and the other, the olecranon fossa, is behind. A small radial fossa lies above the capitulum in front.

The medial epicondyle is more prominent than the lateral one and has a groove for the ulnar nerve on its posterior surface.

#### **The ulna**

The upper (proximal) thickened end of the ulna is separated into two processes: the thicker, posterior process (olecranon), and the smaller, anterior one, (the coronoid process). The trochlear notch is located between these two processes. It serves for articulation with the trochlea of the humerus. On the radial side of the coronoid process, there is the tuberosity of the ulna, to which the tendon of the brachial muscle attaches. The radial notch is located on the lateral side of the proximal epiphysis and serves for articulation with articular circumference of the radius. The lower (distal) end of the ulna has the spherical head with a flat inferior surface, from which the styloid process projects. The head of the ulna has the articular surface on its circumference, by means of which it articulates with the ulnar notch of the radius.

#### **The radius**

The radius, in contrast to the ulna, has a distal end that is thicker than the proximal end. The proximal end forms a rounded head which has a concave surface for articulation with the head of the humerus. One third or one half of the circumference of the head is also occupied by an articular surface which articulates with the radial notch of the ulna. The head of the radius is separated from the rest of the bone by a neck; directly below it, on the anterior side of the radius, there is the radial tuberosity. The lateral border of the distal end of the radius proceeds with the styloid process. There is the concave carpal articular surface on the distal epiphysis. The medial border of the distal radial end has a small ulnar notch for articulation with the circumferential articular surface of the ulnar head.

#### **The bones of the hand**

The bones of the hand are subdivided into the carpal, metacarpal bones, and bones which are the components of the fingers, the phalanges.

### **The carpus**

The carpus is a collection of eight small, spongy bones arranged in two rows of four bones each.

The proximal or first row nearest to the forearm is made up of the following bones (named from the thumb):

- the scaphoid bone;
- the lunate bone;
- the triquetral bone;
- the pisiform bone.

The distal or second carpal row consists of the following bones:

- the trapezium bone (larger multangular);
- the trapezoid (smaller multangular);
- the capitate bone;
- the hamate bone, it bears the hook of the hamate.

The names of bones reflect their shape. Each bone has facets for articulation with the neighbouring bones.

The carpal groove (sulcus carpi) on the radial side is bounded by a prominence which is formed by the tubercle of the scaphoid and trapezium bones: on the ulnar side it is bounded by another eminence, consisting of the hamulus of the hamate bone and the pisiform bone.

### **The metacarpus**

The metacarpus consists of five metacarpal bones which are short tubular bones and are numbered in sequence, beginning with the thumb: the first, the second, the third, the fourth, and the fifth. Each metacarpal bone has a base, a diaphysis (body, shaft), and a rounded head. The base of the fifth metacarpal bone is saddle shaped. It articulates with the hamate, and has tuberositas ossis metacarpi V.

### **Bones of the fingers (phalanges)**

Bones of the fingers, called phalanges, are short tubular bones. Each finger, with the exception of the thumb, has three phalanges: proximal, middle, and distal. The thumb has only two phalanges: the proximal and the distal phalanx. Each phalanx has the base, the body and the head. The heads are pulley-shaped with a groove in the middle. The distal end of the distal phalanx is flattened and has a tuberosity.

Name of fingers:

- pollex – the 1st finger;
- index, or pointer finger, or forefinger – the 2nd finger;
- middle or long finger – the 3rd finger;
- ring or annular finger – the 4th finger;
- small finger – the 5th finger.

## **THE SKELETON OF THE LOWER LIMB**

The skeleton of the lower limbs is divided into two parts: the pelvic girdle (hip bone) and bones of the free part of the lower limb.

### **The pelvic girdle**

The pelvic girdle is created by right and left hip bones. The hip bone is formed by fusion of three separate bones: the ilium, the pubis, and the ischium. These bones fuse in the region which bears the greatest weight, namely, in the region of the acetabulum, the articular cavity of the hip joint. The ilium is above the acetabulum, the pubis is below and in front of it, and the ischium is below and to the back of the acetabulum. In individuals under the age of 16, three bones are separated one from another by layers of cartilage, which, in an adult, undergo ossification, i.e. synchondrosis changes to synostosis. As a result the three bones fuse to form a single bone.

The acetabulum is a rather deep, cup shaped cavity with a high rim in the medial side of which, there is a notch. The smooth articular surface of the acetabulum (lunate surface) is crescent-shaped. The centre, the acetabular fossa, and the nearest to the notch part are rough.

### **The ilium**

The ilium has the thick inferior part – the body. The superior fan-shaped and fairly thin part of the ilium forms the wing or ala. The superior free border of the wing is a sinuous crest (crista iliaca) to which three broad abdominal muscles are attached (labium externum, linea intermedia, labium internum).

The crest ends anteriorly as the anterior superior iliac spine (ASIS) and posteriorly as the posterior superior iliac spine. Below each of the corresponding spines, there are two other spines, the anterior and posterior inferior iliac spines.



The inner surface of the iliac wing is smooth, slightly concave, and forms the iliac fossa, below which there is an arcuate line. Posteriorly and below the fossa, there is an auricular surface, the site of articulation with the corresponding surface of the sacrum. Behind and above the auricular surface, there is the iliac tuberosity. The gluteal lines run on the external surface of the iliac wing: the anterior gluteal line, the posterior gluteal line, and the inferior gluteal line.

### **The pubis**

The pubic bone has a body and a superior and inferior rami forming an angle. The symphyseal surface connects superior and inferior pubic rami and faces the midline. On the superior ramus, there are a small pubic tubercle and the pectineal line. The inferior surface of the superior pubic ramus has a small groove, the obturator groove. The iliac body fuses with the superior pubic ramus, and they form the iliopectineal eminence.

### **The ischium**

The ischium has a body and a ramus. The greatly thickened part of the ramus is called the ischial tuberosity (tuber ischiadicum). There is the lesser sciatic notch on the posterior border of the body. It is separated from the greater sciatic notch by the ischial spine.

The ischial ramus fuses with the inferior pubic ramus and, together, they form the obturator foramen.

**Bones of the free lower limb** are divided into the thigh (femur), foreleg (tibia and fibula) and the skeleton of the foot.

### **The femur**

**The femur or a thigh bone** is the largest and the thickest long tubular bone in the human skeleton. The upper (proximal) end of the femur has a spherical articular head, on which there is a small rough depression (fovea capitis femoris). The head is connected with the rest of the bone by a neck. Two bony prominences are called trochanters: the greater trochanter and the lesser trochanter are found at the junction of the neck with the shaft of the femur. The trochanteric fossa is on the medial surface of the greater trochanter. Both trochanters

are joined on the posterior surface of the femur by an oblique intertrochanteric crest and on the anterior surface – by the intertrochanteric line.

**The body (shaft)** of the femur has a rounded shape. On the posterior surface of the body, there is a linea aspera (a rough line) which has two lips: lateral and medial. Both lips diverge above and below. Proximally, there is the gluteal tuberosity on the lateral lip and linea pectinea on the medial lip of the linea aspera. Distally, lips diverge and enclose a smooth triangular popliteal surface on the posterior side of the femur.

**The lower (distal)** thickened end of the femur has medial and lateral condyles. Anteriorly, the articular surfaces of the condyles blend with each other to form the patellar surface (facies patellaris).

On the posterior and inferior surfaces, the condyles are separated by a deep intercondylar fossa or notch.

Rough prominences are found on the sides of each condyle above the articular surface. These are medial and lateral epicondyles.

**The patella or the kneecap** is a large sesamoid bone which is lodged in the tendon of the quadriceps femoris muscle. The patella has a superior wide end, the base, and a pointed inferior end or the apex. The anterior surface of the patella is rough, while the posterior surface has the smooth articular surface.

### **The skeleton of the leg**

Leg skeleton consists of two bones of unequal thickness: the tibia and the fibula. The tibia recedes medially and the fibula – laterally.

### **The tibia**

**The proximal end of the tibia (proximal epiphysis)** forms two condyles: medial and lateral. They bear superior articular surfaces for articulation with the respective condyles of the femur. The articular surfaces of the tibial condyles are separated from each other by an intercondylar eminence, which has two intercondylar tubercles: medial and lateral.

The intercondylar eminence has two small intercondylar depressions in front and behind: the anterior intercondylar area and the posterior intercondylar area.

The tibial tuberosity is placed below condyles on the anterior tibial margin. A small flat articular surface for articulation with the fibula is in the posterolateral part of the lateral condyle.

**The body (shaft) of the tibia is trihedral.** The anterior, the medial, and the lateral (interosseous) borders divide the shaft into three surfaces: posterior, medial and lateral. The medial surface and the anterior border are easily palpated under the skin. Medially, the distal end of the tibia has a massive process, the medial malleolus. Behind the malleolus, there is a flat bony groove. The lower end of the tibia has an inferior articular surface, and on the lateral side of the medial malleolus, there is a malleolar articular surface. The fibular notch is on the lateral border of the distal end of the tibia.

### **The fibula**

The fibula is a long thin bone with thickened ends. The proximal epiphysis forms the head which carries an articular facet. A little to the back and lateral of this surface, there is the apex of the head.

The body of the fibula is trihedral and twisted on its longitudinal axis.

The lower, distal fibular epiphysis thickens to form the lateral malleolus, which carries a smooth articular facet. On the posterior surface of the lateral malleolus, there is a malleolar fossa.

### **Bones of the foot**

The tarsal, metatarsal bones, and bones of the toes are distinguished in the foot.

### **The tarsus**

The tarsus is made up of seven short spongy bones, which are arranged in two rows. The posterior or proximal row is formed of two comparatively large bones: the talus – superiorly and the calcaneus lying below it.

The anterior or distal row is formed of the following bones:

- the navicular bone;
- the cuneiform bones: medial, intermediate and lateral;
- the cuboid bone.

**The talus (ankle bone)** consists of a body which extends anteriorly as a constricted neck. The neck is extended with an oval convex head.

**The body of the talus** has a trochlea tali on its superior surface for articulation with the leg bones. The trochlea has two articular surfaces on its sides – the medial and lateral malleolar facets.

Posterior to the trochlea, the body of the talus gives rise to the posterior processes of the tali. On the inferior surface of the talus, there are the anterior, middle and posterior articular facets for joining with calcaneus. A deep rough groove passes between the middle and posterior facets.

**The calcaneus or a heel bone** has anterior, middle and posterior articular surfaces, which correspond to the articular facets on the talus. The calcaneus has a projection and a medial process called the sustentaculum tali. It supports the head of the talus.

**The calcaneal groove (sulcus calcanei)** separates the middle and posterior articular facets of this bone. It joins a similar sulcus of the talus and both form the bone canal (sinus tarsi) opening on the lateral side of the dorsal surface of the foot. On the distal surface of the calcaneus, facing the second row of the tarsal bones, there is a saddle-shaped articular surface for a cuboid. Posteriorly the body terminates as a rough tuber calcanei.

### **The metatarsus**

The metatarsus is formed by five metatarsal bones; they are short tubular bones. Each metatarsal bone consists of the proximal part or the base, the middle part or the body, and the distal part or the head. They are separated by the interosseous spaces. Each bone features the articular surfaces on the proximal and distal ends. The bases of metatarsals have narrow facets on their sides for joining together.

### **The toes**

The bones of the toes or the phalanges are short tubular bones. There are 14 phalanges. The first digit or great toe (**hallux**) has two strong phalanges – proximal and distal. The other digits have three phalanges – the proximal, middle and distal.

Each phalanx consists of:

- the base;
- the body or shaft;
- the head.

The main distinguishing feature of distal phalanges is the distal phalanx tuberosity.

## THE SKELETON OF THE HEAD

The skull (cranium) is divided into two parts:

- the cerebral cranium or the neurocranium;
- the visceral cranium or the facial skull.

The skull cap or cranial vault (calvaria) and floor or cranial base are distinguished in the cerebral cranium.

The human cerebral cranium consists of the unpaired occipital, frontal and ethmoid bones, the paired temporal and parietal bones. The visceral cranium is formed by the paired maxilla, inferior nasal conchae, palatine, zygomatic, nasal and lacrimal bones, and the unpaired vomer, mandible and hyoid bones.

### The frontal bone

The frontal bone is an unpaired bone. It belongs to pneumatic bones because it has the sinus inside. The sinus is filled with air.

The frontal bone consists of three parts:

- the squama (squama frontalis);
- the unpaired nasal part;
- the paired orbital part.

1. **The frontal squama** has the shape of a plate, externally convex and internally concave.

Two frontal tubers are situated on the external surface.

The inferior border of the squama is called the supraorbital margin (margo supraorbitalis).

There is a supraorbital notch or supraorbital foramen on this border. Above the supraorbital foramen on this border. Above the supraorbital border, there is a bony ridge, the known as superciliary arch. Between these arches, there is the flat area – glabella. The lateral end of the supraorbital border stretches out to form the zygomatic process (processus zygomaticus.) The groove for superior sagittal sinus runs on the midline of the internal surface of squama. Its edges unite below to form a ridge, the frontal crest. The crest runs to the foramen caecum.

2. **The orbital or horizontal part.** The orbital parts are separated by the ethmoid notch. The superior cerebral surface has the cerebral ridges of cranium (juga cerebrales) and digitate impressions. The inferior surface (facies orbitalis) features the lacrimal fossa (fossa glandulae lacrimalis) near the zygomatic process, the

trochlear fossa (fovea trochlearis) and the trochlear spine (spina trochlearis) near the supraorbital notch.

3. **The nasal part** occupies the anterior part of the ethmoidal notch on the midline. There is a projection ending as a sharp process – the nasal spine (spina nasalis). On either side of the spine, there are the openings leading into the frontal sinus (sinus frontalis), located in the thickness of the bone. The sinus varies greatly in size. The frontal sinus contains air.

### The parietal bone

The parietal bone is a paired flat bone forming the middle part of the vault of the skull. It is a quadrangular plate with the external convex and internal concave surfaces. Its four borders articulate with the adjoining bones, namely:

- the frontal border – with the frontal bone;
- the occipital border – with the occipital bone;
- the sagittal border – with the contralateral bone;
- the squamous border – with the squamous part of the temporal bone;

The four angles are as follows:

- the frontal angle articulates with the frontal bone;
- the sphenoidal angle articulates with the sphenoid bone;
- the occipital angle articulates with the occipital bone;
- the mastoid angle articulates with the mastoid process of the temporal bone.

In the center of the external surface there is a prominence, the parietal tuber (tuber parietale). Below it, there are two curved temporal lines (linea temporalis, superior, and inferior) for attachment of the temporal fascia and muscle. The parietal foramen is seen near the superior border and occipital angle.

On the internal surface there are sites of attachment of the dura mater (sulcus sinus sagittalis superioris) along the superior border and a transverse groove (sulcus sinus sigmoidei) in the region of the mastoid angle (angulus mastoideus ossis parietalis). The pits for pacchionian granulations are seen on either side of the groove for the superior sagittal sinus.

### **The occipital bone**

The occipital bone forms a posterior and inferior walls of the skull and, there, it is a part of the calvaria and a part of the base of the skull. It has four parts:

- the basilar part anteriorly;
- right and left condylar parts laterally;
- the squamous part posteriorly.

These parts form the borders of the foramen magnum.

**The squamous part**, as a membrane bone, is shaped like a plate with a convex external surface and a concave internal surface.

In the centre of the external surface, there is the external occipital protuberance (protuberantia occipitalis externa). A curved superior nuchal line extends lateralward from the protuberance on either side. Above this – a less conspicuous highest nuchal line. The external occipital crest runs downward from the external occipital protuberance. The inferior nuchae lines extend the lateral ward from the middle of the crest.

On the internal surface of squama there is the internal occipital protuberance. The internal occipital crest extends downward from it. The grooves for the transverse sinus extend the lateral ward from the internal protuberance. The groove for superior sagittal sinus extends upwards of this protuberance. These structures form the cruciate eminence.

**Each lateral part** of the occipital bone has occipital condyle on its external surface, the place of articulation with the atlas. The hypoglossal canal penetrates the occipital condyle. Behind the condyle there is the condylar canal in the condylar fossa. The jugular process extends lateralward from the condyles. The groove for sigmoid sinus is located on the internal surface of the jugular processes. The margin of the jugular process is concave bounding the jugular notch.

**The basilar part** fuses with the sphenoid bone by age of 18 to form a single bone in the centre of the cranial base. A sloping area, clivus, is made up of two fused parts. It is located on the internal surface of this bone. The groove for the inferior petrosal sinus is seen on the lateral edges of the basilar part. The external surface has the pharyngeal tubercle.

### **The ethmoid bone**

The ethmoid bone is an unpaired pneumatic bone. The bony plates of the ethmoid bone are arranged in the form of the letter "T" in which the vertical line is formed by the perpendicular plate and the horizontal line – by the cribriform plate. The ethmoidal labyrinths hang on either side of the perpendicular plate laterally to the lamina cribrosa.

1. **The cribriform plate** is a rectangular plate fitting into the ethmoid notch of the frontal bone. It is perforated by small openings.

2. **The perpendicular plate** divides into two portions. The upper one is crista galli. It projects upward from the midline of the cribriform plate. The lower part is a part of the bony nasal septum.

3. **Ethmoidal labyrinth** makes up a paired complex of bony air cells, cellulae ethmoidales, covered laterally by a thin orbital plate which forms the medial wall of the orbit. On the medial surface of the labyrinth, there are two nasal conchae: superior and middle ones. Between these conchae, the superior nasal meatus is located.

### **The sphenoid bone**

The sphenoid bone is an unpaired pneumatic bone and has following parts:

- the body (corpus);
- the greater wings (alae majores);
- the lesser wings (alae minores);
- the pterygoid processes.

The body has a depression in the shape of a Turkish saddle, the sella turcica at the center of its superior surface. On the floor of sella turcica, there is a depression of the hypophysis (fossa hypophysialis). To the front of the depression, there is the tuberculum sellae, on which prechiasmatic sulcus lies transversely. The optic canal (canalis opticus) is found at either end of the prechiasmatic groove. The sella turcica is bounded posteriorly by dorsum sellae which ends by the posterior clinoid processes. A curved carotid groove (sulcus caroticus) lies on the lateral surface of the body of sphenoid bone.

On the anterior surface of the body, there is the crest of the sphenoid (crista sphenoidalis) which extends down to become the rostrum of the sphenoid. Irregularly shaped openings, apertures

of the sphenoidal sinus, are seen to the sides of the crest. They open into an air cavity, the sphenoidal sinus, which is located in the body. The sinus communicates with the nasal cavity.

**The greater wings (alae majores)** spring from the side of the body laterally and upwards. Each wing has the following four surfaces: cerebral, orbital, temporal, and maxillary. The last two surfaces are separated by the infratemporal crest. The foramen rotundum, foramen ovale, and foramen spinosum are located on the greater wings. On the posterior edge of the greater wings a sharp projection – the spine of the sphenoid – is located.

**The lesser wings (alae minores)** are two flattened triangular plates. The posterior edges of the lesser wings are free and carry the anterior clinoid processes on their medial ends. Between the lesser and greater wings, there is the superior orbital fissure.

**The pterygoid processes** drop vertically down. Their base is pierced by a pterygoid canal. Each process is made up of two plates, one medial and one lateral, between which the pterygoid fossa is enclosed posteriorly. The inferior part of the medial plate bends over to form a hook-like process called hamulus pterygoideus.

### **The temporal bone**

The temporal bone is a paired bone. It has a very complicated structure because it is concerned with three functions of the skeleton and forms not only a part of the lateral walls and a base of the skull but also houses the organs of hearing and equilibrium.

It is the mixed bone which consists of three parts:

- the squamous part;
- the petrous part;
- the tympanic part.

The parts of the temporal bone fuse and form the sutures and fissures, namely:

- **petrosquamous fissure** is on the border between the squamous and petrous parts on the anterior surface of the temporal bone;

- **tympanosquamous fissure** is in the depth of the mandibular fossa separated by the process of the petrous part in the **petrosquamous** and **petrotympanic fissure**.

**The petrous part** is an important component of the temporal bone. It is so named because of its strong bony substance.

This part is also called the pyramid because it is shaped like a trihedral pyramid with the base facing externally and the apex facing anteriorly and internally forward the sphenoid bone.

**The pyramid has three surfaces: anterior, posterior and inferior:**

- the anterior surface is a part of the floor of the middle cranial fossa;
- the posterior surface faces posteriorly and medially, and bounds the posterior cranial fossa in front;
- the inferior surface faces downward and is visible only on the external surface of the skull.

The complex external relief of the pyramid is determined by its structures as a receptacle for the middle and the internal ear as well as by the passage of nerves and vessels.

**The anterior surface of the pyramid** has a small depression near its apex. This is the trigeminal impression which lodges the ganglion of the trigeminal nerve.

There are two small grooves passing lateral to it: sulcus of the greater petrosal nerve – medially and sulcus of lesser petrosal nerve – laterally.

They lead to two openings called the same: a medial opening (hiatus canalis n. petrosi majoris) and a lateral opening (hiatus canalis n. petrosi minoris).

The arcuate eminence (eminencia arcuata) is lateral to those openings; it is formed due to the prominence of the vigorously developing labyrinth (the internal ear).

The bone surface between the petrosquamous fissure and arcuate eminence forms the roof of the tympanic cavity (tegmen tympani).

About the middle of the posterior surface of the pyramid, there is the internal acoustic opening (porus acusticus internus) leading into the internal acoustic meatus.

The inferior surface of the pyramid that faces the base of the skull gives off a slender tapering styloid process for attachment of muscles and ligaments.

Between the styloid and mastoid processes there is the stylomastoid foramen. The deep jugular fossa is medial to the styloid process. The

external opening of the carotid canal is located in front of the jugular fossa and separated from it by a sharp ridge where a tiny fossula petrosa is located.

**The pyramid has three edges: anterior, posterior and superior.** The short anterior edge forms a sharp angle with the squama in which the musculotubal canal is found. It passes to the tympanic cavity.

The canal is divided by a septum into two parts: superior and inferior. The superior, smaller semicanal (semicanalis m. tensor tympani), lodges the tensor tympani muscle, while the lower, larger semicanal (semicanalis tubae auditiva), is the bony part of the auditory tube for the conduction of air from the pharynx to the tympanic cavity.

The superior edge of the pyramid that separates the anterior and posterior surfaces bears a clearly detectable groove, a groove for the superior petrosal sinus, lodging the corresponding venous sinus.

The inferior surface of the pyramid provides the attachment for the muscles that determine its relief. Its lower end stretches out to form the mastoid process.

The mastoid process has a deep mastoid notch (incisura mastoidea), the site of muscles' attachment. and small occipital groove (sulcus occipitalis).

The mastoid process contains compartments or cells (cellulae mastoidea) which are air cavities separated by bone trabeculae. The largest cell is called the mastoid antrum.

A deep groove for sigmoid sinus (sulcus sinus sigmoidei) is found on the cerebral surface of the mastoid process. An opening at the rate of the mastoid process, mastoid foramen, transmits an emissary vein to the sigmoid sinus.

The tympanic part of the temporal bone forms the anterior, inferior and partly posterior border of the external acoustic meatus (meatus acusticus externus). It is a short canal directed medially and somewhat anteriorly and leading into the tympanic cavity. The superior edge of its external opening, porus acusticus externus, and part of the posterior edge are formed by the squama of the temporal bone. The other edges are formed by the tympanic part of the bone.

### ***The squama (squama temporalis)***

The squama has a relatively simple structure of a vertical plate with a rounded edge articulating with the corresponding edge of the parietal bone, margo squamosa, like the scale of fish: hence its name.

The squama forms the anterior and superior part of the bone. The external surface is smooth and convex. It has a groove for the middle temporal artery running vertically.

The cerebral surface of the squamous part bears marks of the brain (impressions digitatae) and an ascending groove lodging the middle meningeal artery (a. meningea media).

The squamous part has the zygomatic process which passes forward to join the zygomatic bone. Near the root of the zygomatic process, the mandibular fossa (fossa mandibularis) is located. It serves for articulating with the lower jaw. In front of this fossa, an articular tubercle is situated.

### **Canals of the temporal bone**

1. **Carotid canal.** The external aperture is placed on the inferior surface of the pyramid, and the internal aperture of the carotid canal is situated on the anterior edge of the pyramid.

2. **Caroticotympanic canaliculi begin** on the posterior wall of the carotid canal and **enter** the tympanic cavity penetrating its anterior wall.

3. **Facial canal.** The facial canal **begins** at the bottom of the internal acoustic meatus. The facial canal **ends** in the stylomastoid foramen.

4. **Canaliculus of chorda tympani.** It opens off the facial canal above the stylomastoid foramen and **exits** through the petrotympanic fissure.

5. **Tympanic canaliculus begins** on the inferior surface of the pyramid in the fossula petrosa and **exits** through the hiatus for lesser petrosal nerve on the anterior surface of the pyramid.

6. **Mastoid canaliculus begins** in the lateral part of the jugular fossa. The tympanomastoid fissure receives the mastoid canaliculus, which transmits the vagal auricular branch into the fissure.

7. **Musculotubal canal is divided** into two semicanals:

a) canal for the tensor tympani muscle, situated above;

b) canal for the auditory (Eustachian) tube, situated below.

The canal is located between the anterior margin of the pyramid and the squamous part of the temporal bone. It enters the tympanic cavity.

## THE BONES OF THE VISCERAL CRANIUM

The bones of the visceral cranium form bony receptacles for sense organs (vision, olfaction) and for the initial parts of the alimentary (oral cavity) and respiratory (nasal cavity) systems that determine their structure.

### The upper jaw bone (maxilla)

The upper jaw bone (maxilla) is a paired pneumatic bone with a complex structure determined by the diversity of its function.

The maxilla consists of a body and four processes.

The body (corpus maxillae) contains a large maxillary air sinus (sinus maxillaris or antrum Highmori), hence, highmoritis, inflammation of the maxillary sinus. Maxillary sinus communicates with the nasal cavity by a wide opening, the maxillary hiatus (hiatus maxillaris).

### The following four surfaces are distinguished on the body:

1. **The anterior surface (facies anterior)** is concave in modern man since his food is cooked and the function on mastication is consequently weaker. Inferiorly it continues as the alveolar process in which a series of depressions (jugae alveolaria) between the ridge of the tooth are seen. The canine fossa (dog's hole) is situated on the anterior surface of the maxilla.

Superiorly, the anterior surface of the maxilla is separated from the orbital surface by the infraorbital margin (margo infraorbitalis). Immediately below it, there is the infraorbital foramen through which the infra-orbital nerve and artery leave the orbit. The medial border of the anterior surface is formed by the nasal notch (incisura nasalis) whose edge extends forward to form the anterior nasal spine.

2. **The infratemporal surface** is separated from the anterior surface by the zygomatic process and carries several small perforations (transmitting the nerves and vessels to the upper teeth), the maxillary tuberosity and greater palatine sulcus for the maxillary nerve.

3. **The nasal surface** extends inferiorly as the superior surface of the palatine process. There is a conchal crest on it. To the back of the frontal process, there is the nasolacrimal canal (sulcus lacrimalis). Still farther backwards, there is a large opening that leads to the maxillary sinus.

4. The smooth, flat **orbital surface** is triangular. There is the lacrimal notch (incisura lacrimalis) lodging the lacrimal bone on its medial border behind the frontal process. The infraorbital groove originates near the posterior border of the orbital surface and is converted anteriorly into the infraorbital canal with the opens onto the anterior surface of the maxilla.

**The alveolar canals** arise from the infraorbital canal; they transmit nerves and vessels passing in the thickness of the anterior maxillary wall to the teeth.

### Processes of the maxilla

1. **The frontal process** projects upward and joins the nasal part of the frontal bone. Its lateral surface is divided into two parts by a vertical lacrimal crest (crista lacrimalis anterior), which continues inferiorly as with the infraorbital margin. The medial surface carries the ethmoidal crest for attachment of the middle nasal concha.

2. **The alveolar process** on its inferior border carries an alveolar arch with dental sockets for the eight upper teeth.

3. **The palatine process** forms most of the hard bony palate (palatum osseum) by joining the contralateral process in the midline. Where they meet, the nasal crest rises to the superior surface facing the nasal cavity. Near the anterior end of the nasal crest on the superior surface, there is an opening that leads into the incisive canal (canalis incisivus)

The superior surface of the process is smooth, whereas the inferior surface, facing the oral cavity, is rough and carries longitudinal palatine grooves (sulci palatini).

4. **The zygomatic process** articulates with the zygomatic bone.

### The lower jaw-bone (mandible)

The lower jawbone, or the mandible, is the only truly moveable skull bone. It is a horseshoe-shaped bone.

The mandible consists of a horizontal part or the body (*corpus mandibulae*), which carries the teeth, and a vertical part in the form of two mandibular rami.

The horizontal and vertical parts meet at the angle called the angle of mandible, on the external surface of which, the masseter muscle inserts to the masseteric tuberosity.

On the inner surface of the angle, there is the pterygoid tuberosity for insertion of another muscle of mastication (*m. pterygoideus medialis*).

The activity of the masticatory apparatus, therefore, affects the size of this angle.

The upper alveolar part of the body (*pars alveolaris*) bears teeth; as a consequence of that, its border, the alveolar arch, has sockets for the teeth (*alveoli dentales*) with interalveolar septa (*septa interalveolaria*) and corresponding depressions on the external surface (*juga alveolaria*).

The thick inferior border of the body forms the base of the mandible. In old age when the teeth are lost, the body of the mandible becomes thin and low.

On the midline of the body, there is a triangular mental protuberance, the presence of which is a characteristic feature of modern man.

On each side of this protuberance, there is a mental tubercle. On the lateral surface of the body, in the space between the first and second premolars, there is the mental foramen or an opening of the mandibular canal, transmitting a nerve and vessels.

An oblique line runs to the back and upward from the mental tubercle.

The mental spine projects from the inner surface of the body of the mandible.

On both sides of the mental spine, there is the site for the digastric muscle attachment, the digastric fossa. Further to the back is the mylohyoid line, running backward and upward. The sublingual fossa resides above the mylohyoid line while the submandibular fossa is situated below. Both fossae house the same named salivary glands.

The ramus of the mandible rises on each side of the posterior part of the body of the mandible. On its inner surface, there is the mandible foramen leading into the mandibular canal, mentioned above.

The medial edge of this foramen projects as the lingula of the mandible.

The mylohyoid groove originates behind the lingula and runs down and forward.

Superiorly, the ramus of the mandible terminates as two processes:

- anterior – the coronoid process;
- posterior – the condylar process.

A crest for the attachment of the buccinator muscle (*crista buccinatoria*) runs upward on the inner surface of the ramus.

The condylar process has a condyle head and neck. On the anterior surface of the neck, there is the pterygoid pit (*fovea pterygoidea*) for attachment of the lateral pterygoid muscle.

### **Small bones of the skull**

The palatine bone is a paired bone. It is a thin bone consisting of two plates which unite at a right angle and supplement the maxilla.

1. **The horizontal bony plate** complements the maxillary palatine process posteriorly to form the hard palate (*palatum osseum*). On the inferior surface of the horizontal plate, there is the greater palatine foramen, through which palatine vessels and nerves leave the greater palatine canal.

2. **The perpendicular bony plate** adjoins the nasal surface of the maxilla. Along its lateral surface the greater palatine sulcus runs. Together with the maxillary sulcus of the same name, it forms the greater palatine canal (*canalis palatinus major*).

The palatine bone has three processes:

1. **The pyramidal process** projects backward and fits into the pterygoid fissure of the sphenoid bone.

The other two processes project from the superior edge of the perpendicular bony plate and form the sphenopalatine notch, which meets the body of the sphenoid bone to form the sphenopalatine foramen, transmitting the sphenopalatine vessels and nerves.

2. **The anterior process** is called the orbital process.

3. **The posterior process** is called the sphenoid process.

### **The zygomatic bone**

The zygomatic bone is a paired bone and the strongest bone of the skull. Two processes and three surfaces are distinguished in it:



- the lateral surface;
- the temporal surface;
- the orbital surface.

1. The frontal process of the zygomatic bone articulates with the zygomatic process of the frontal bone and the greater wing of the sphenoid bone.

2. The temporal process articulates with the zygomatic process of the temporal bone to form the zygomatic arch.

#### ***The vomer***

The vomer (an unpaired bone) is an irregularly quadrangular plate. It forms part of the bony nasal septum. Its superior border is split into two wings (alae vomeris), which fit over the rostrum of the sphenoid bone.

#### ***The hyoid bone***

The hyoid bone is situated at the base of the tongue between the mandible and the larynx. It consists of a body and two pairs of horns (cornua):

- the greater horns;
- the lesser horns.

***The inferior nasal concha*** is a paired and independent bone. The bone is attached to the lateral wall of the nasal cavity.

***The nasal bone*** joins the contralateral bone to form the ridge of the nose and its root.

***The lacrimal bone*** is a paired thin plate found on the medial wall of the orbit behind the frontal process of the maxilla.

## THE SKULL AS A WHOLE

***The external surface*** of the base of the skull (basis cranii externa) is composed of the inferior surface of the visceral (without mandible) and the cerebral cranium. It extends from the incisors, anteriorly, to the superior nuchal line, posteriorly. Its lateral border stretches from the infratemporal crest to the base of the mastoid process.

Three parts in the external surface of the base of the skull are distinguished: anterior, middle, and posterior.

The anterior part is formed of the hard palate (palatum osseum) and the alveolar arch of the maxilla. A transverse suture is seen in the posterior part of the hard palate at the junction of its components: the palatine process of the maxilla and the horizontal plates of the palatine bones. A median palatine suture, joining the

paired parts of the hard palate, runs on the midline, and its anterior end is continuous with the incisive foramen. In the posterior part of the hard palate, there is the greater palatine foramen, the exit from the greater palatine canal, and the opening of the lesser palatine canal.

The middle part extends from the posterior edge of the hard palate to the anterior margin of foramen magnum. On the anterior border of this part, there are openings of the choanae. They are bounded by the body of the sphenoid bone above, by the horizontal plates of the palatine bones below, and by the medial plates of pterygoid processes laterally.

On the posterior part of the base of the skull, there is the jugular foramen, formed by the jugular notch of the temporal bone, and the jugular notch of the occipital bone.

The foramen lacerum is formed between sphenoid, temporal and occipital bones.

The inner surface of the base of the skull (basis cranii interna) can be examined only on the horizontal or sagittal section of the skull. The internal or superior surface of the base of the skull is separated into three cranial fossae: the anterior, middle and posterior. The anterior and middle fossae lodge the cerebrum. The posterior edges of the lesser wings of the sphenoid bone form the borderline between the anterior and middle cranial fossae. The superior edge of the pyramids of the temporal bones is the borderline between the middle and posterior fossae.

***The anterior cranial fossa*** is formed by the orbital part of the frontal bone, the cribriform plate of the ethmoid bone, and the lesser wings of the sphenoid bone.

***The middle cranial fossa*** is located deeper than the anterior one. Its median part is formed by the sella turcica. The lateral parts are made up of the greater wings of the sphenoid bone, the squamosal parts of the temporal bones, and the anterior surfaces of their pyramids. The openings of the middle fossa are: the optic canal, the superior orbital fissure, foramen rotundum, foramen lacerum, foramen spinosum.

***The posterior cranial fossa*** is the deepest and largest of the three fossae. Its components are: the occipital bone, the posterior parts of the body of the sphenoid bone, the petrous part of temporal bone, and the inferoposterior angle of the parietal bone.

The following openings are found in it: foramen magnum, hypoglossal canal, jugular foramen, condylar canal, mastoid foramen, internal acoustic opening.

### **The orbit**

The orbit, or eye socket, (orbita) contains the organ of vision and is a cavity in the shape of a four-sided pyramid. The base of the pyramid corresponds to the opening into the orbit (aditus orbitae), while the apex is directed backward and medially.

**The medial orbital wall** (paries medialis orbitae) is formed by the frontal process of the maxilla, the lacrimal bone, the orbital plate of the ethmoid bone, and the body of the sphenoid bone to the front of the optic canal.

**The lateral orbital wall** (paries lateralis orbitae) is formed by the orbital surface of the zygomatic bone and greater wings of the sphenoid bone.

**The superior wall**, or roof of the orbit, (paries superior orbitae) is formed by the orbital part of the frontal bone and lesser wings of the sphenoid bone.

**The inferior wall**, or floor of the orbit, (paries inferior orbitae) is made up of the zygomatic bone and maxilla, and in the posterior portion, by the orbital process of the palatine bone.

Two openings are seen at the apex of the orbital pyramid: the superior orbital fissure and the optic canal. By means of both openings, the orbit communicates with the cranial cavity. In the corner, formed by the lateral and inferior orbital walls, there is the inferior orbital fissure. Its posterior end leads into the pterygopalatine fossa, and the anterior end – into the infratemporal fossa.

The fossa of the lacrimal sac is in the anterior part of the medial wall. It leads into the nasolacrimal canal. The other end of the nasolacrimal canal opens into the inferior nasal meatus.

Further to the back in the suture between the frontal and ethmoid bones, there are two openings, the anterior and posterior ethmoidal foramina, transmitting the anterior and posterior ethmoidal nerves and vessels. The anterior foramen leads into the cranial cavity; the posterior foramen leads into the nasal cavity.

### **The nasal cavity**

The cavity of the nose is the initial part of the respiratory tract and place of the olfactory organ localization. The piriform aperture leads into the cavity in the front. It is bounded with the maxilla laterally and inferiorly and with the free edges of the nasal bones superiorly and partly laterally. The anterior nasal spine projects forward on the midline on the inferior margin of the piriform aperture.

The paired openings, the choanae, connect the cavity of the nose with the cavity of the pharynx.

The bony septum of the nose is formed by the perpendicular plate of the ethmoid bone and the vomer. The bony septum divides the nasal cavity into two halves which are not quite symmetrical. In most of the cases, the septum deviates from the sagittal plane to one of the sides.

The nasal cavity has three walls: superior, inferior and lateral.

**The lateral wall is** the most complex in structure. It is formed of the following (from front to back) bones:

- the nasal bone;
- the nasal surface of the body and frontal process of the maxilla;
- the lacrimal bone;
- the labyrinth of the ethmoid bone;
- the inferior concha;
- the perpendicular plate of the palatine bone;
- the medial plate of the pterygoid process of the sphenoid bone.

#### **The superior wall is made up of:**

- the small area of the frontal bone;
- the cribriform plate of the ethmoid bone;
- partly of the sphenoid bone.

#### **The inferior wall or floor is formed:**

- by the palatine process of the maxilla;
- by the horizontal plate of the palatine bone which makes up the bony hard palate (palatum osseum). The opening of the incisive canal is seen in its frontal part.

Superior, middle, and inferior nasal conchae project into the nasal cavity from the lateral wall; they separate such three nasal meatuses from each other as: the superior, the inferior and the middle.

**The superior nasal meatus** is between the superior and the middle conchae of the ethmoid bone; it is half the length of the middle meatus and is found only in the posterior part of the nasal cavity. The sphenoid sinus and posterior air cells of the ethmoid bone open into superior nasal meatus.

**The middle nasal meatus** passes between the middle and the inferior nasal conchae. The inferior and middle cells of the ethmoid bone, the maxillary and frontal sinuses open into it.

**The inferior nasal meatus** is between the inferior nasal concha and the floor of the nasal cavity. The nasolacrimal canal opens into its anterior part; through this canal the tears flow into the nasal cavity. The incisive canal also opens into the inferior nasal meatus. It communicates the oral cavity with the nasal cavity.

The space between the conchae and the nasal septum is known as **the common meatus of the nose**.

**The temporal fossa** is bounded superiorly and posteriorly by the superior temporal line, inferiorly – by the infratemporal crest, and anteriorly – by the zygomatic bone. Thus the frontal and parietal bones, the greater wings of the sphenoid bone, the squama of the temporal bone, and the zygomatic bone take part in its formation. The temporal fossa lodges the temporal muscle.

**The infratemporal fossa** is continuous downward with the temporal fossa, and their borderline is the infratemporal crest of the greater wing of the sphenoid bone.

The medial wall of the infratemporal fossa is formed by the lateral plate of the pterygoid process.

The anterior wall is formed by the infratemporal surface of the maxilla and the lower part of the zygomatic bone.

The superior wall is formed by the inferior surface of the greater wing of the sphenoid bone with the oval and spinous foramina in it.

It communicates with the orbit through the inferior orbital fissure and with the pterygopalatine fossa – through the pterygomaxillary fissure.

The pterygopalatine fossa is located between the back of the maxilla (anterior wall) and the front of the pterygoid process (posterior wall). Its

medial wall is formed by the perpendicular plate of the palatine bone isolating the pterygopalatine fossa from the nasal cavity. The superior wall is formed by the maxillary surface of the greater wing of the sphenoid bone.

**The following openings are found in the pterygopalatine fossa:**

1. The medial opening – the sphenopalatine foramen leading into the nasal cavity and transmitting the sphenopalatine nerve and vessels.

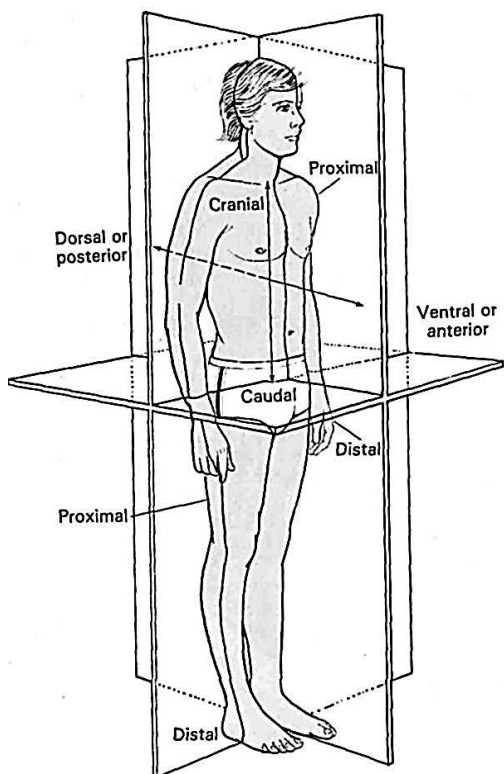
2. The round posterosuperior opening (foramen rotundum) leading into the middle cranial fossa and transmitting the second branch of the trigeminal nerve which leaves the cranial cavity.

3. The anterior opening – the inferior orbital fissure leading into the orbit and transmitting some nerves and vessels.

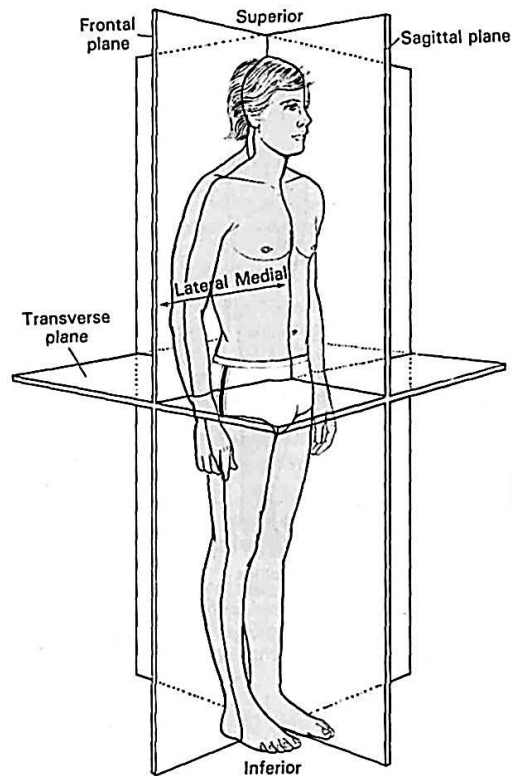
4. The inferior opening – the greater palatine canal leading into the oral cavity. It is formed by the maxilla and the greater palatine sulcus of the palatine bone. It is a funnel-shaped narrowing of the lower part of the pterygopalatine fossa and transmits the nerves and vessels.

5. The posterior opening – the pterygoid canal transmitting the vegetative nerves and leading to the base of the skull.

6. The lateral opening – pterygomaxillary fissure leading into the infratemporal fossa.

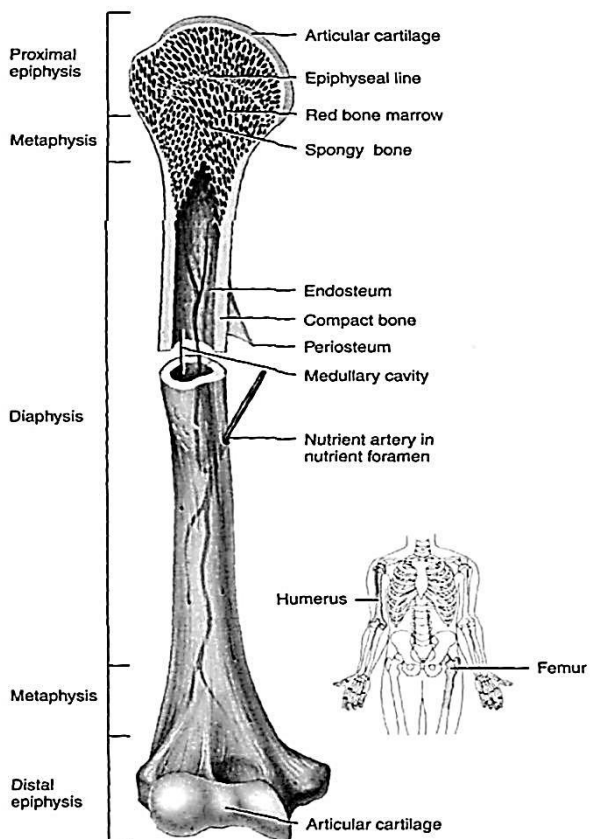


(a) Several important directional terms are indicated by the arrows

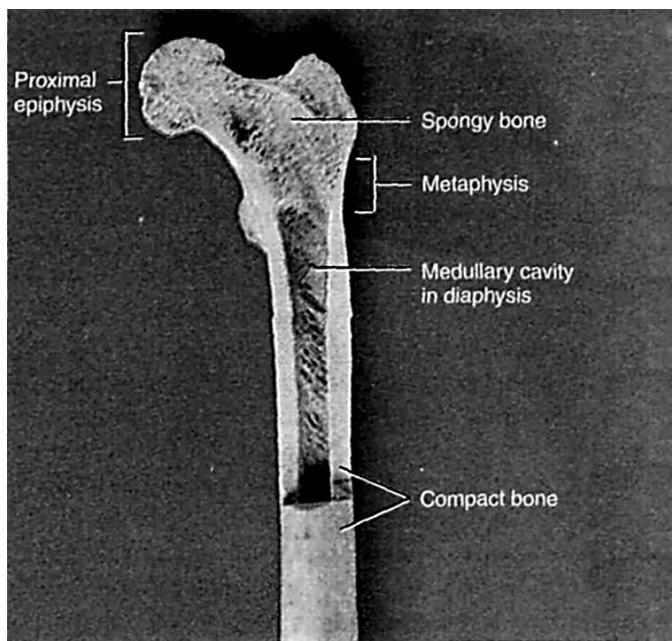


(b) The three planes of section intersect one another at right angles

**Figure 1 – Anatomical planes in a human body**



(a) Partially sectioned humerus (arm bone)



(b) Partially sectioned femur (thigh bone)

**Figure 2 – Parts of a long bone**

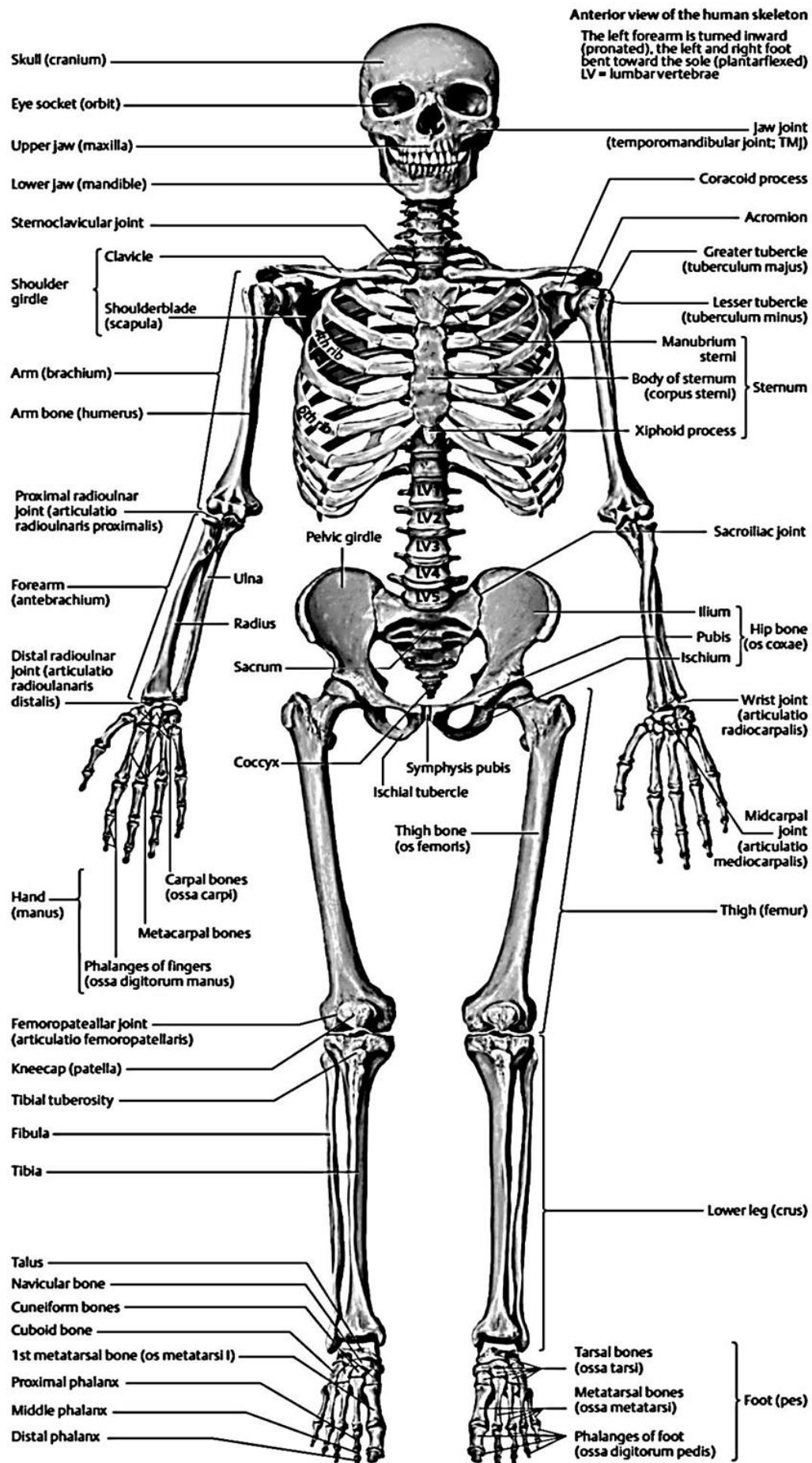
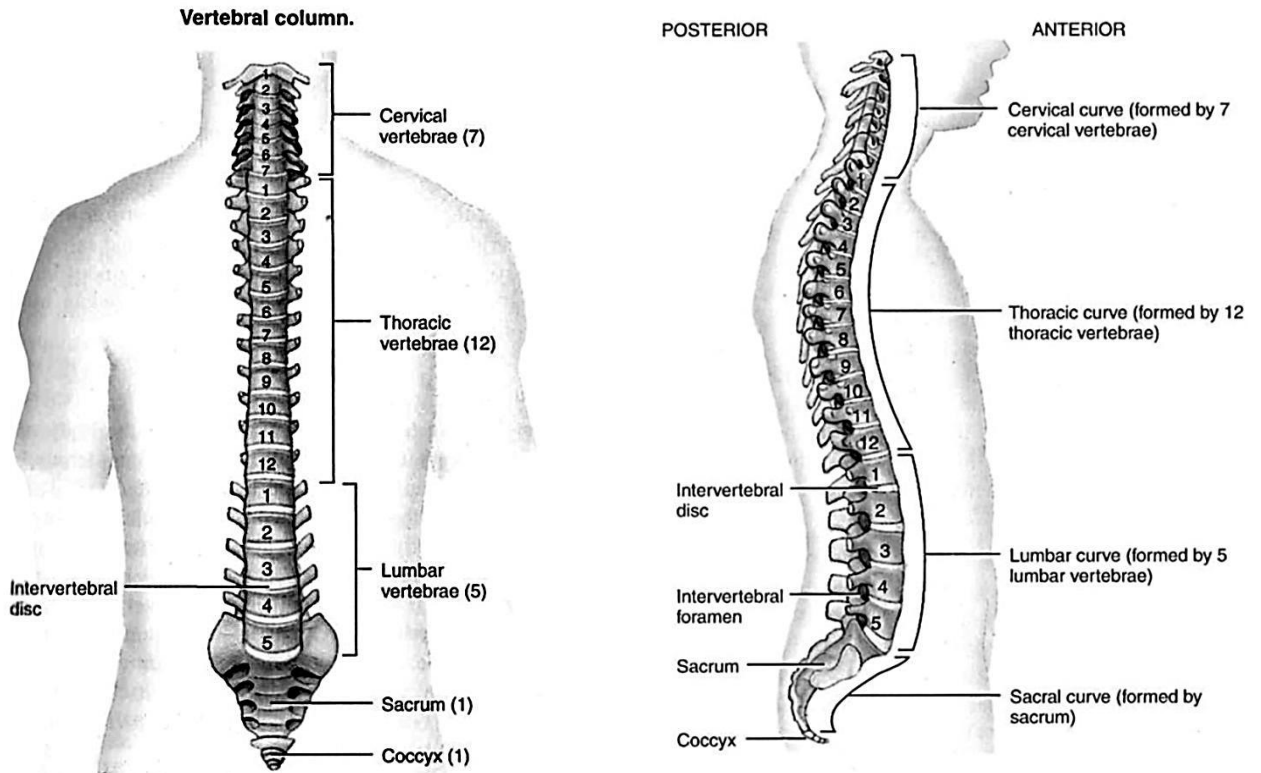
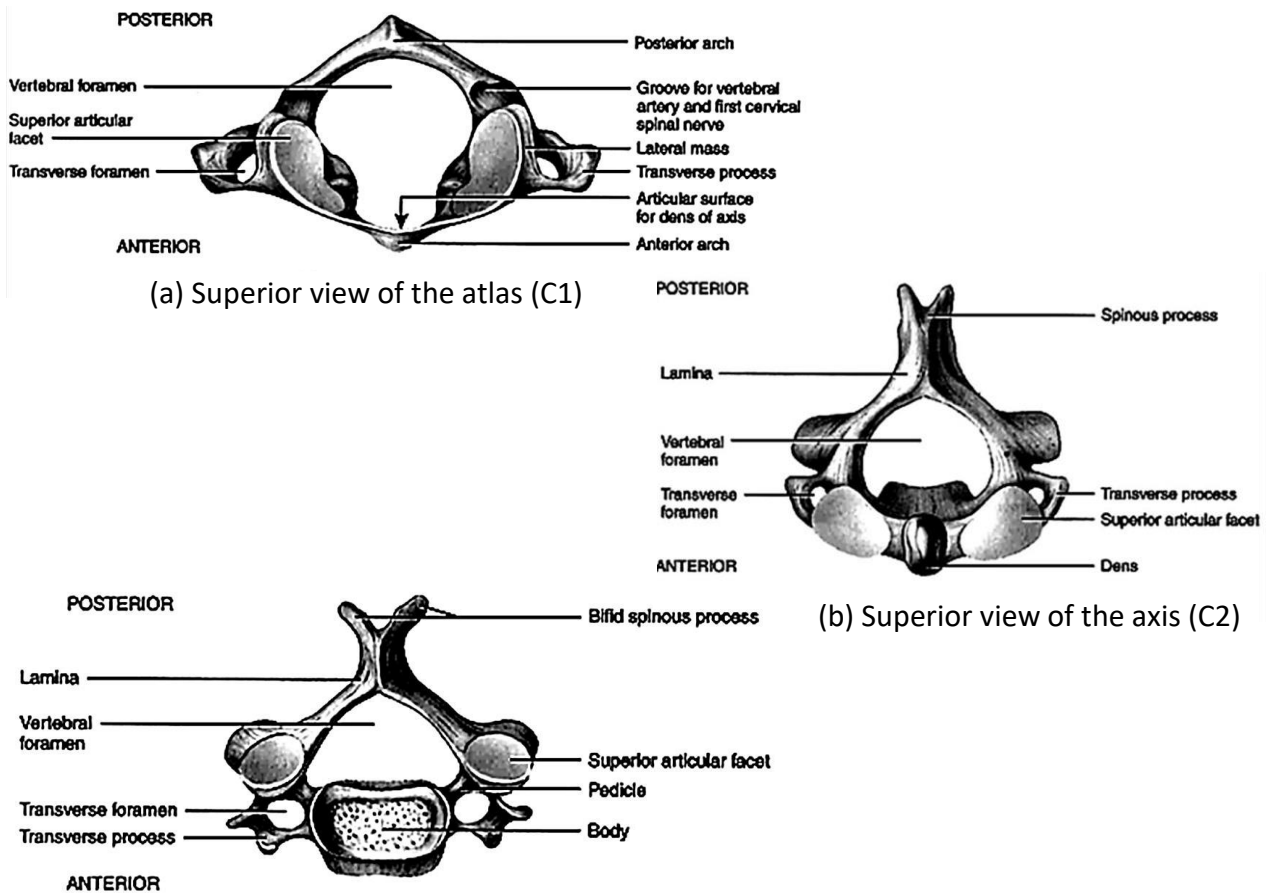


Figure 3 – Division of the human skeletal system



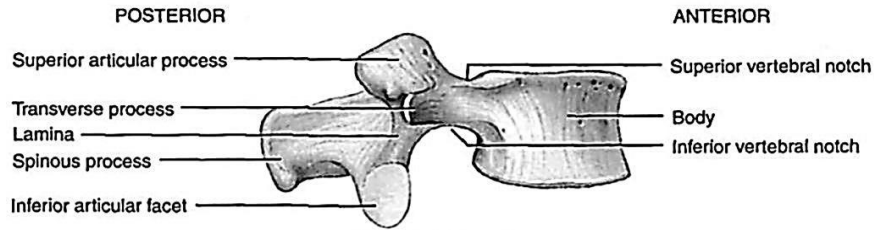
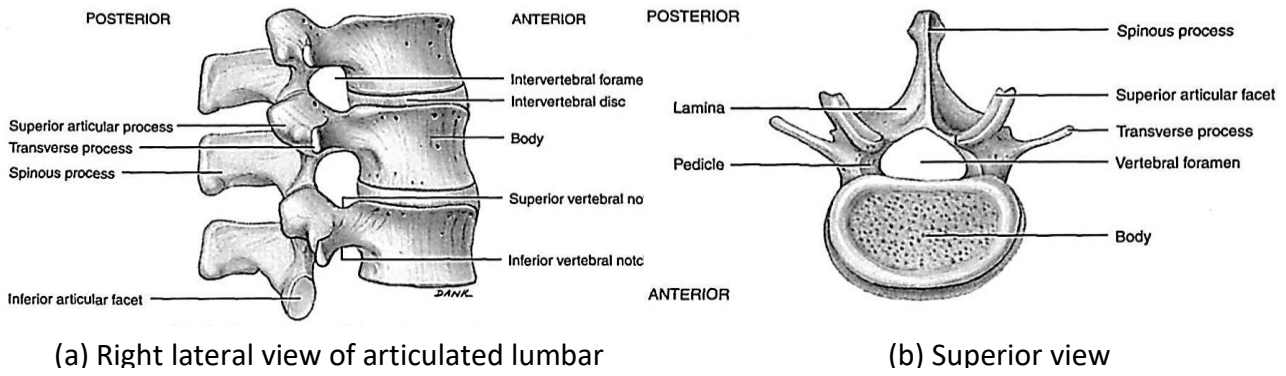
(a) Anterior view showing regions of the vertebral column (b) Right lateral showing four normal curves

**Figure 4 – Vertebral column**

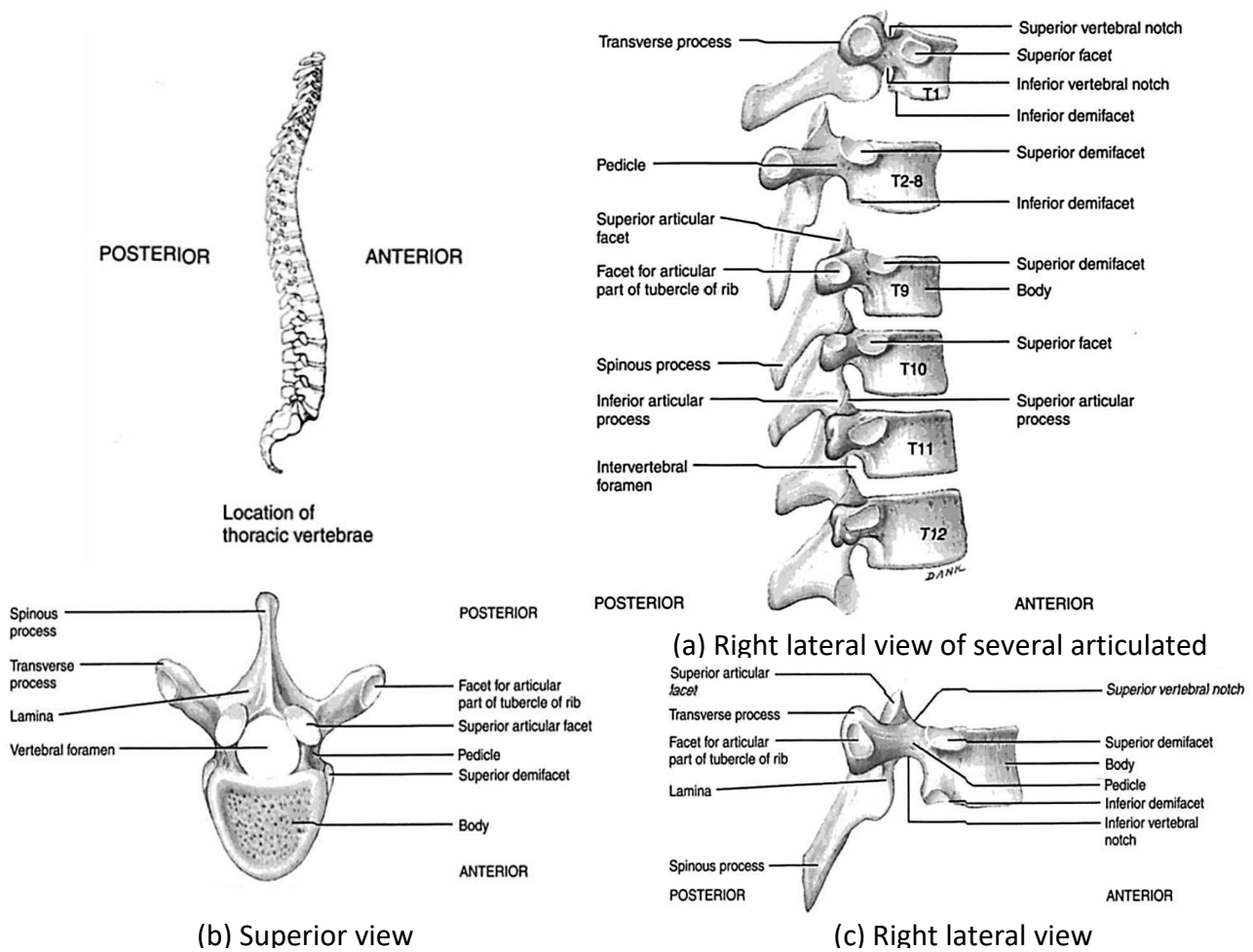


(c) Superior view of a typical cervical

**Figure 5 – Cervical vertebrae**



**Figure 6 – Lumbar vertebrae**



**Figure 7 – Thoracic vertebrae**

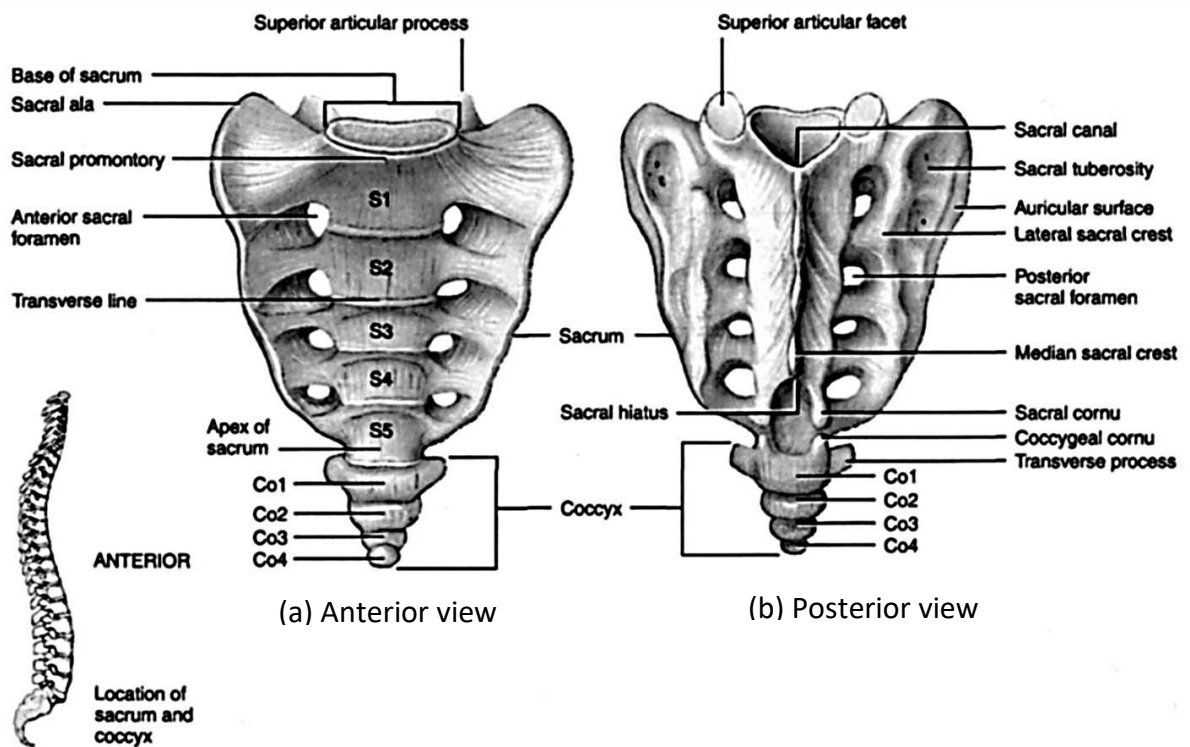


Figure 8 – Sacrum and coccyx

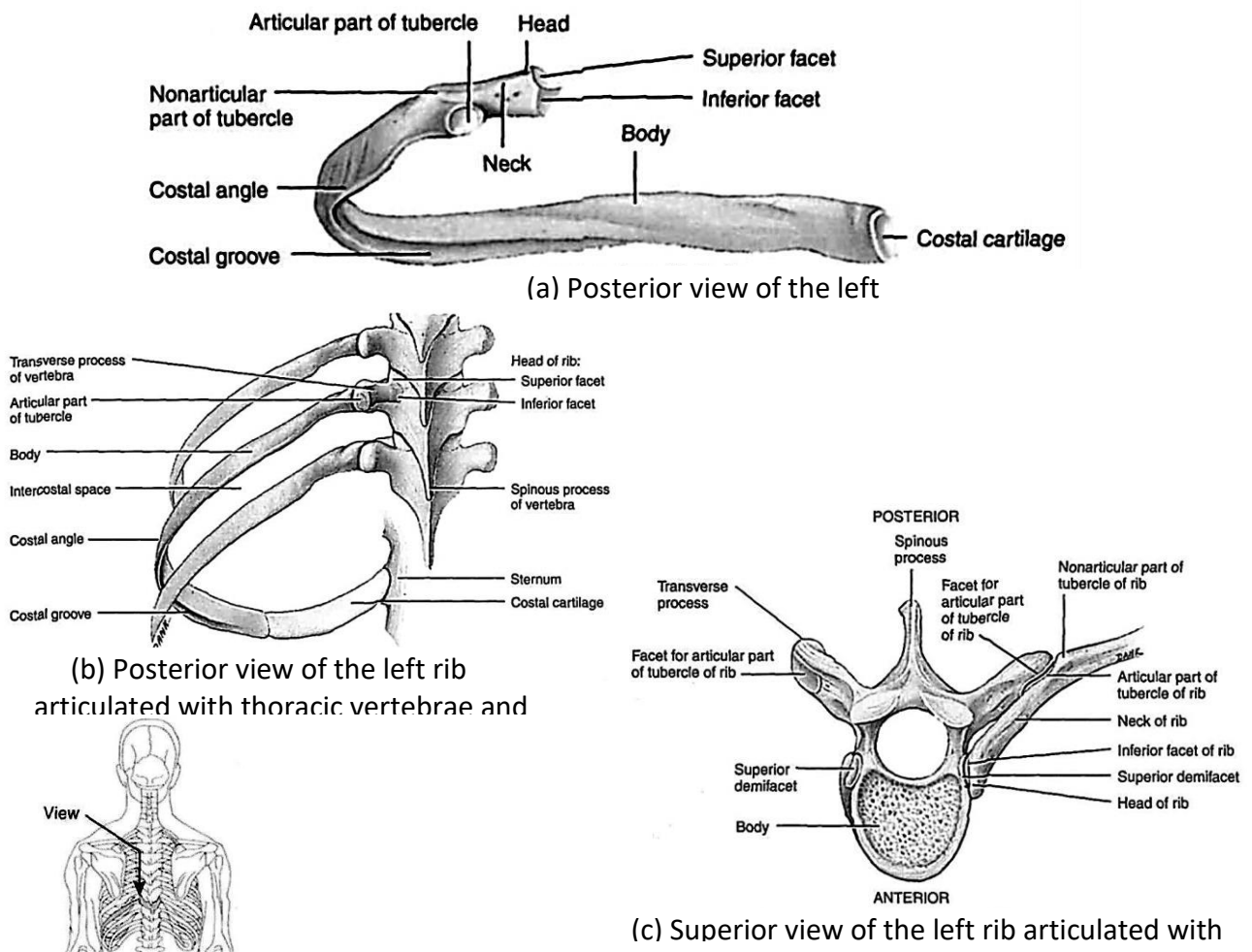


Figure 9 – The structure of the human rib cage. The parts of the rib



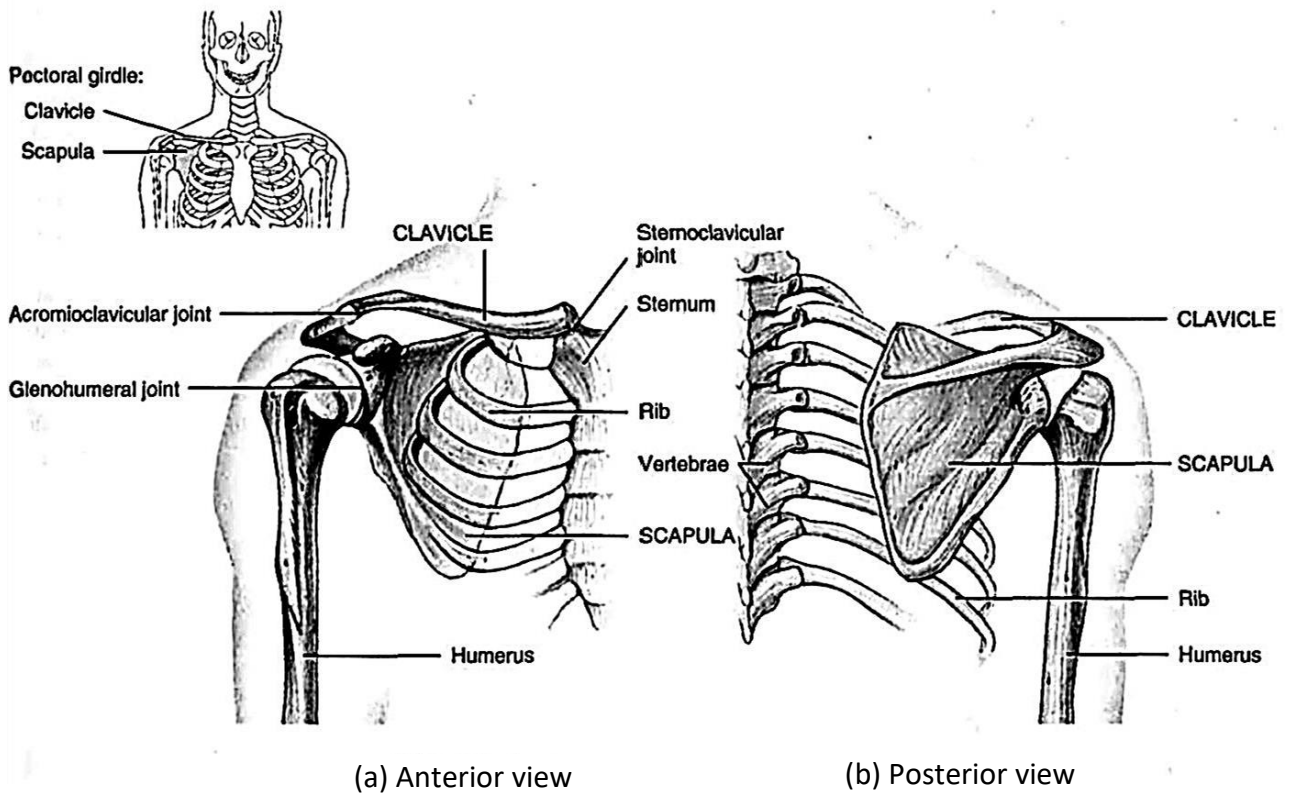


Figure 10 – Right pectoral girdle

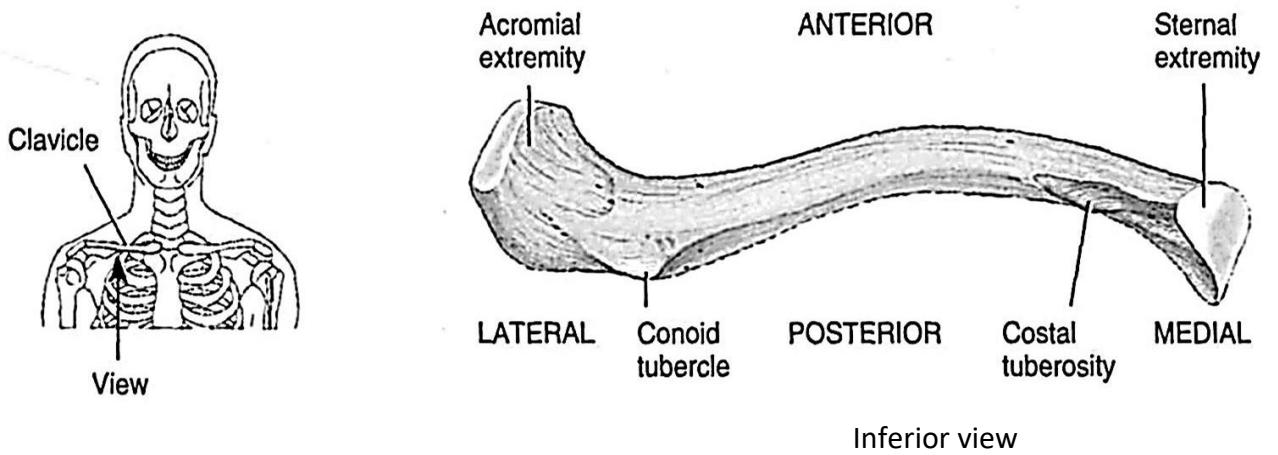
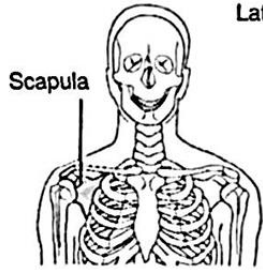
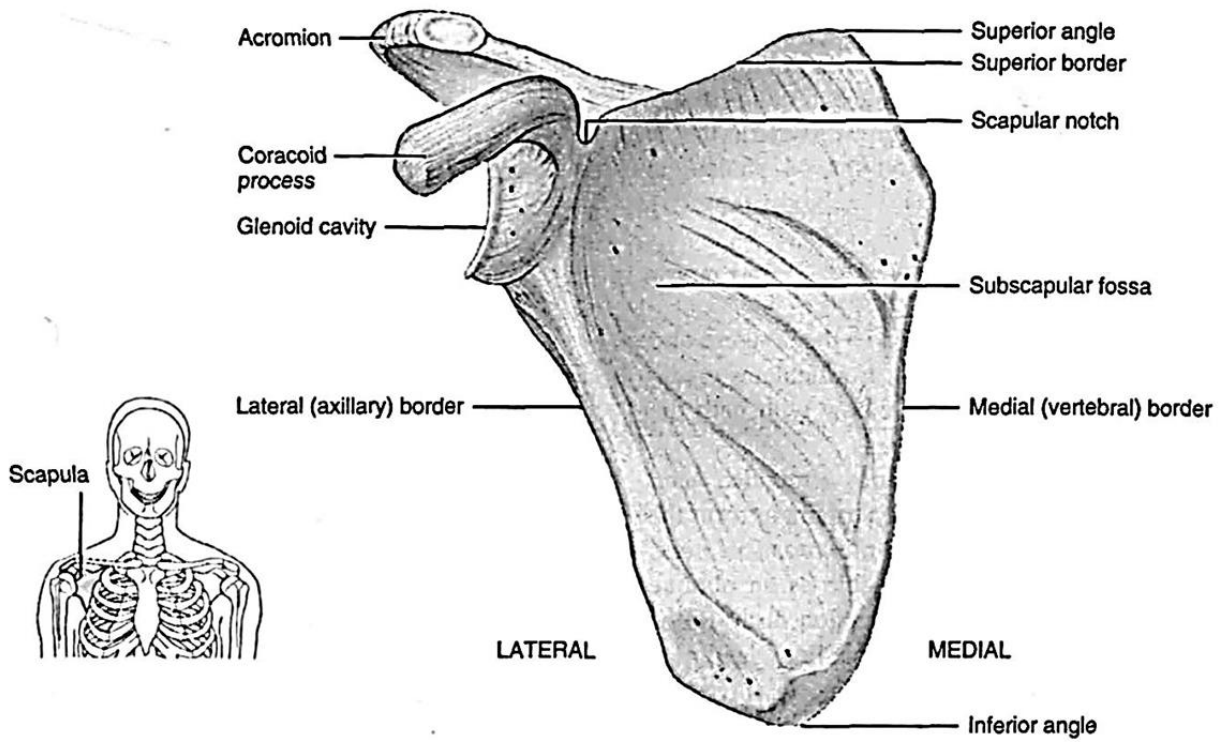
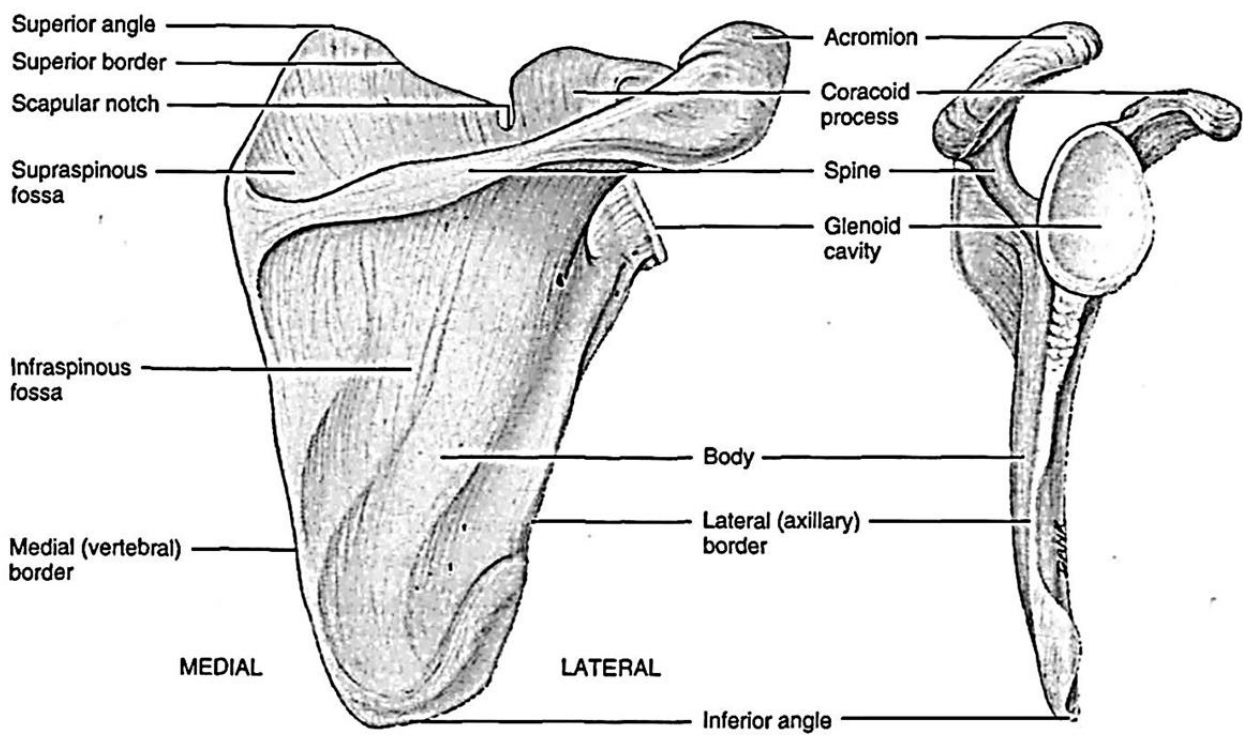


Figure 11 – Right clavicle



(a) Anterior view



(b) Posterior view

(c) Lateral view

Figure 12 – Right scapula

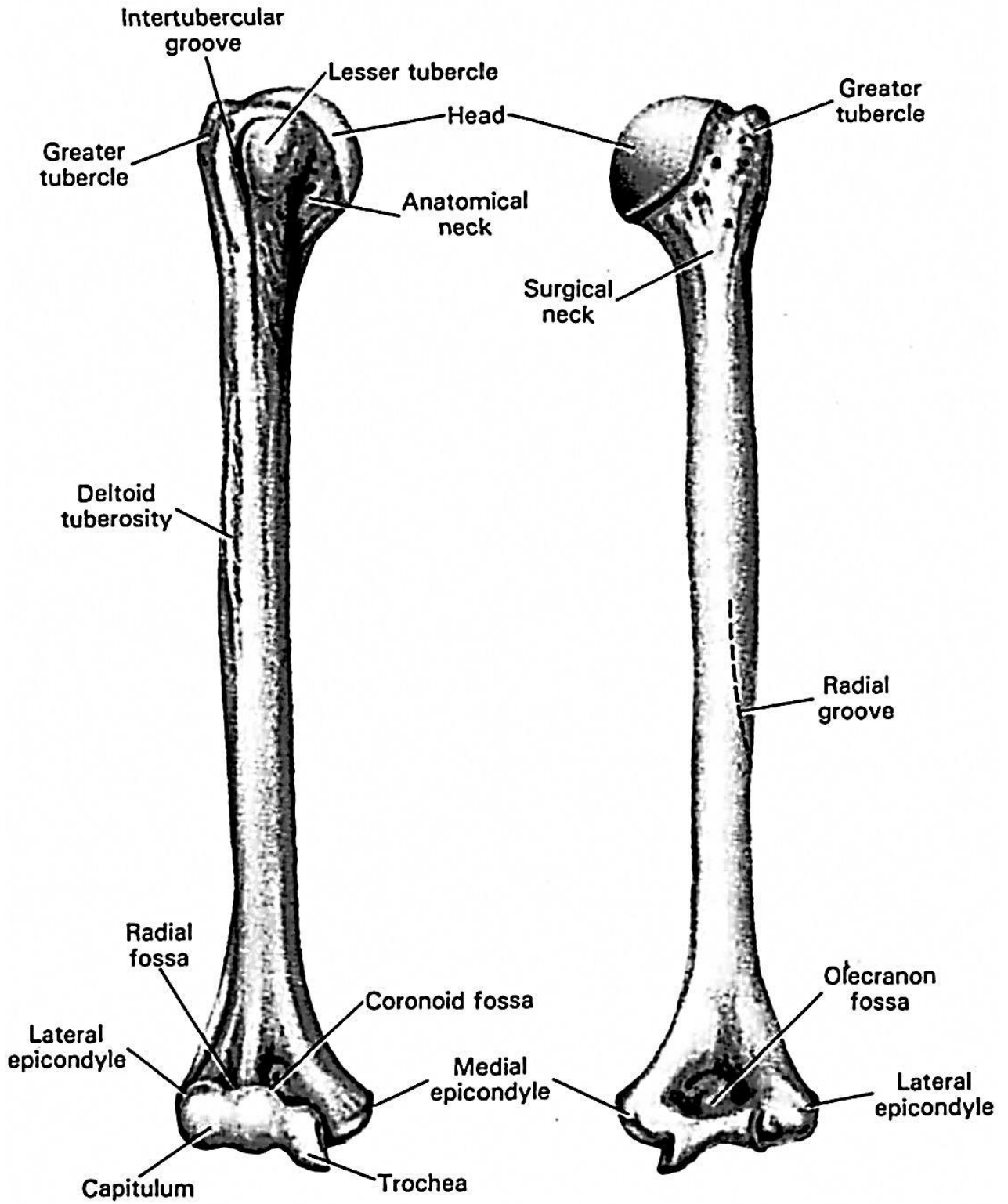


Figure 13 – Right humerus

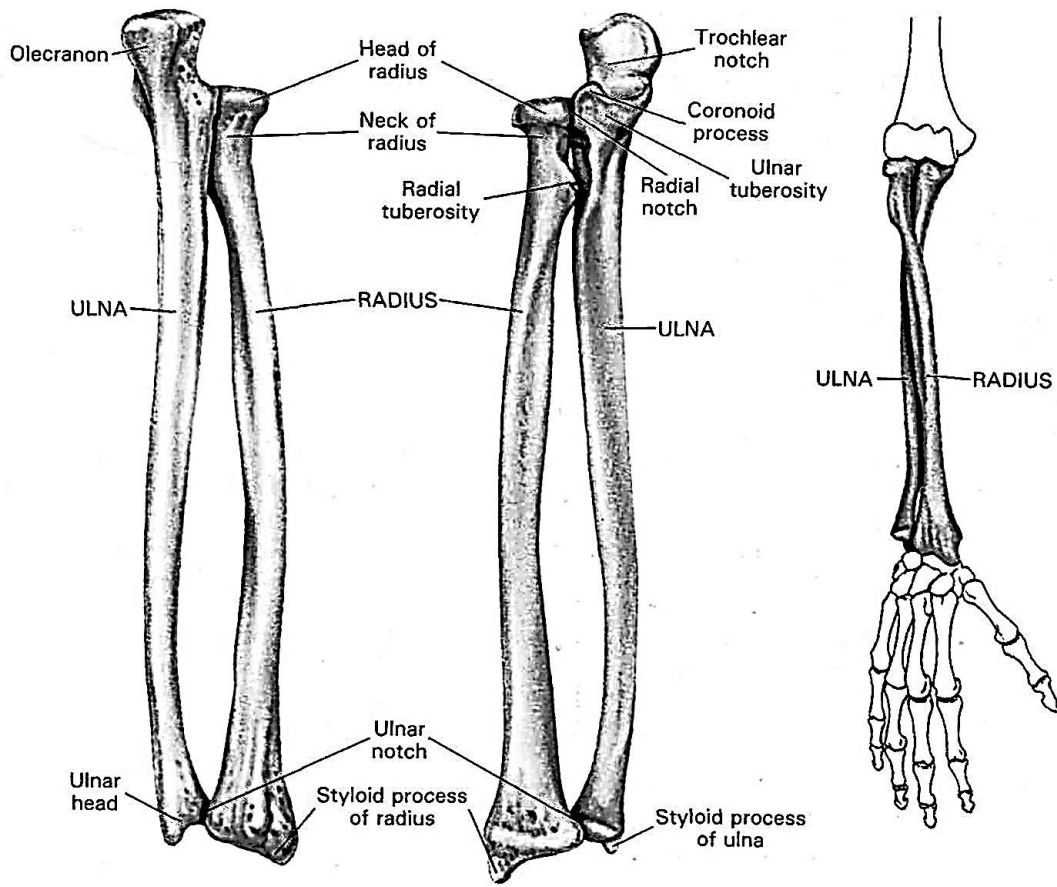


Figure 14 – Right ulna and radius

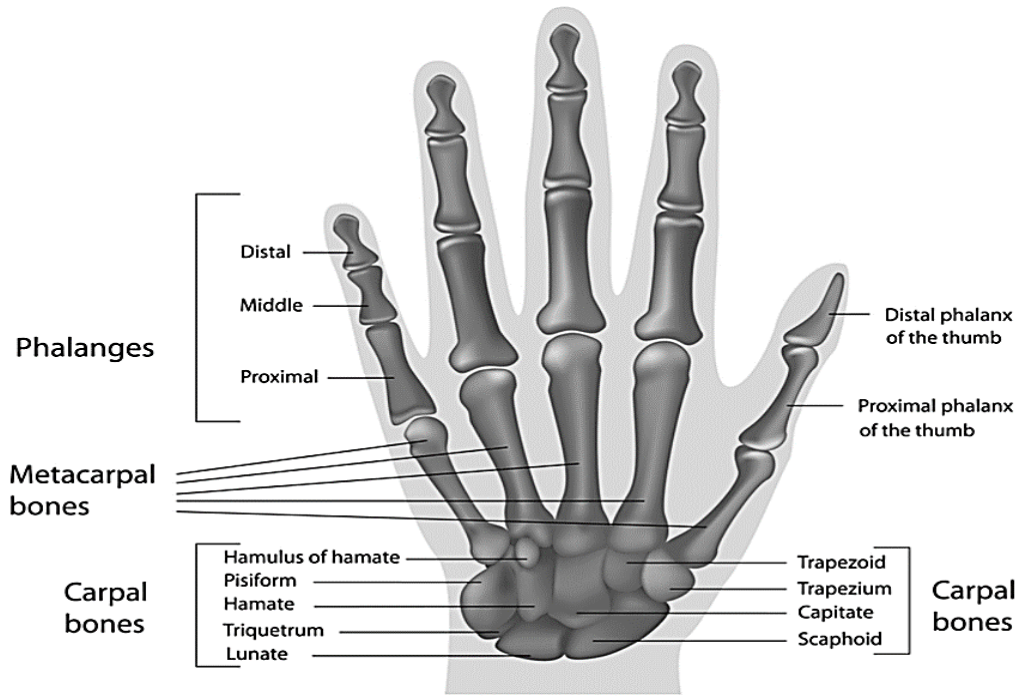
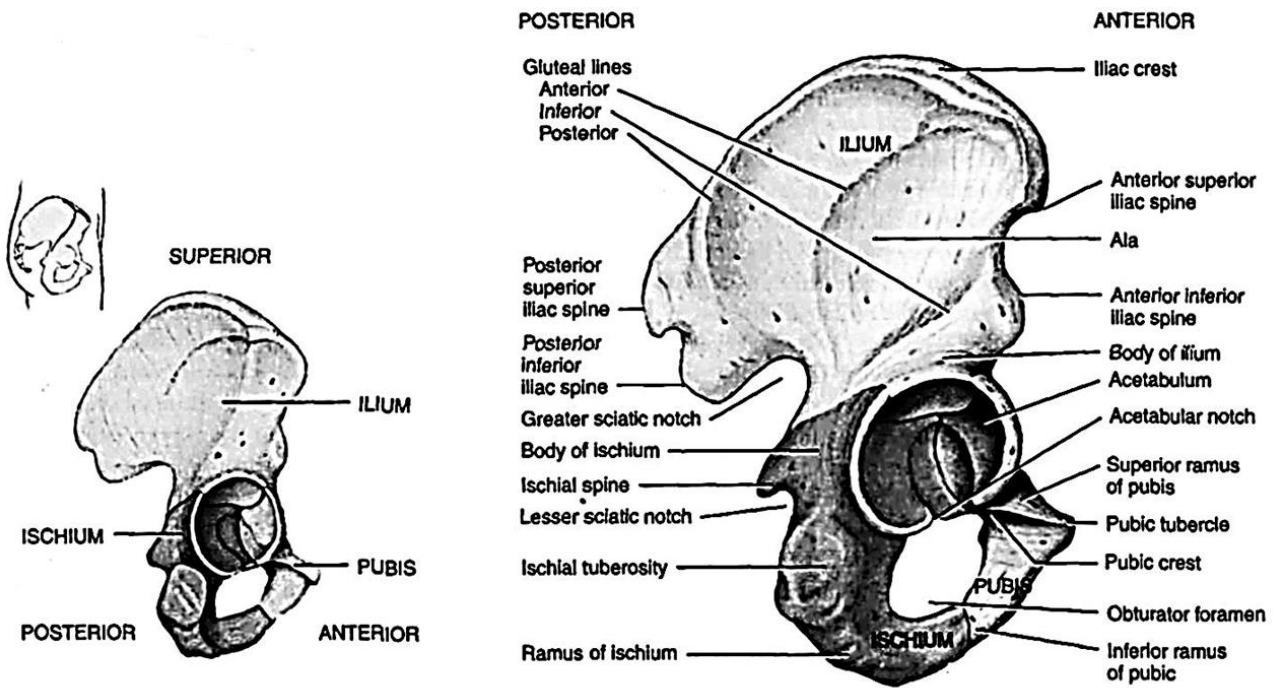
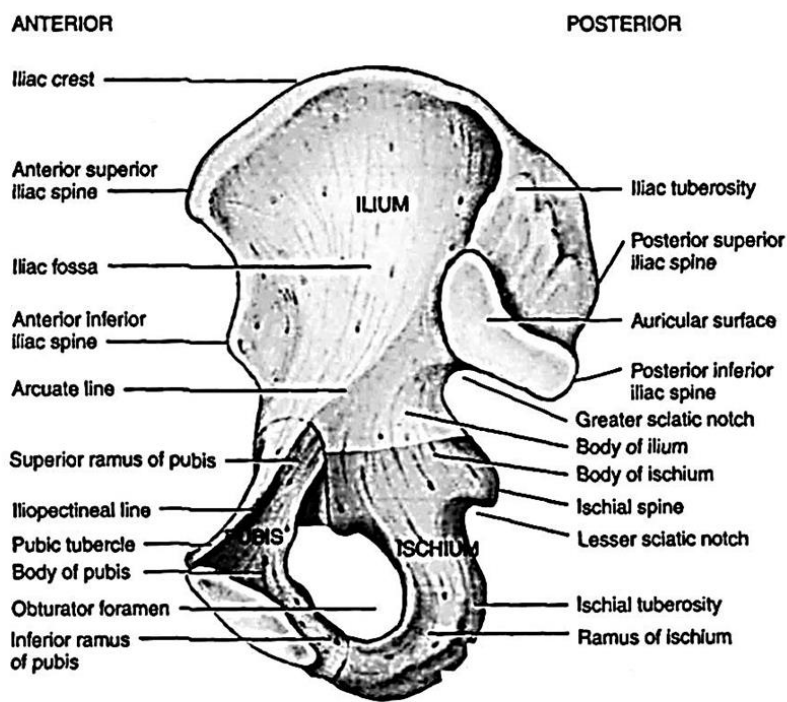


Figure 15 – Bones of the right hand



(a) Lateral view showing parts of hip

(b) Detailed lateral view



(c) Detailed medial

Figure 16 – Right hip bone

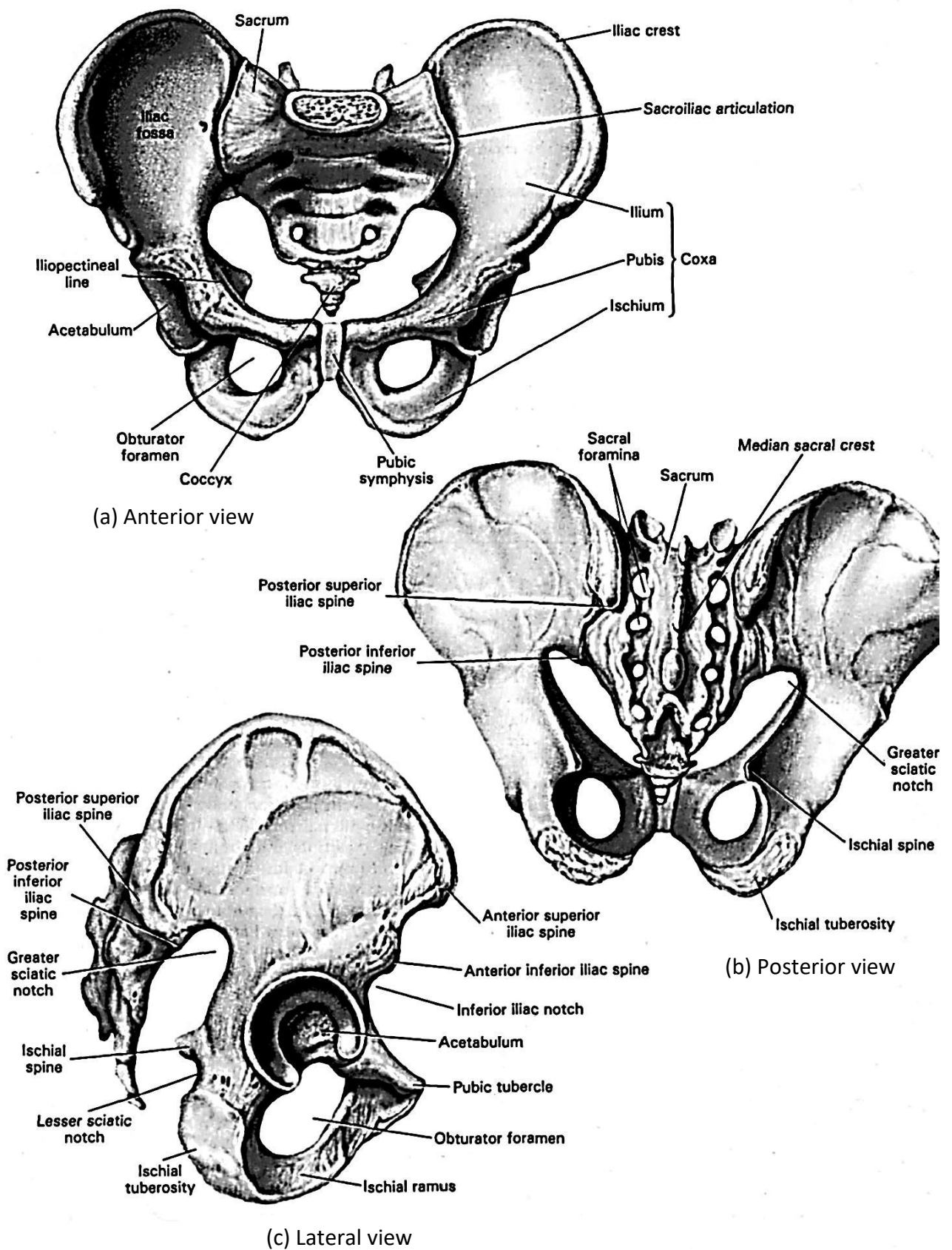


Figure 17 – True and false pelvis

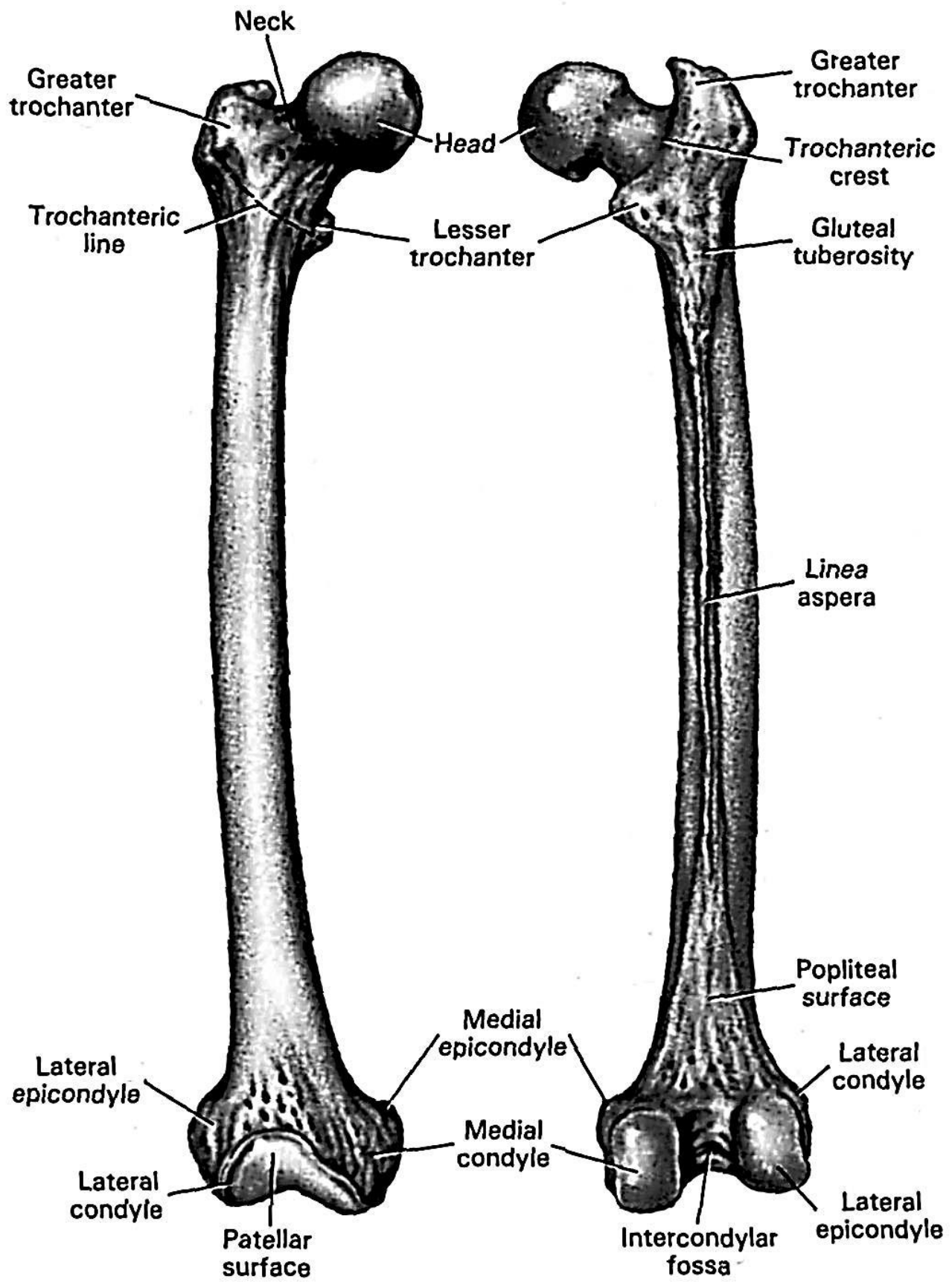


Figure 18 – Right femur

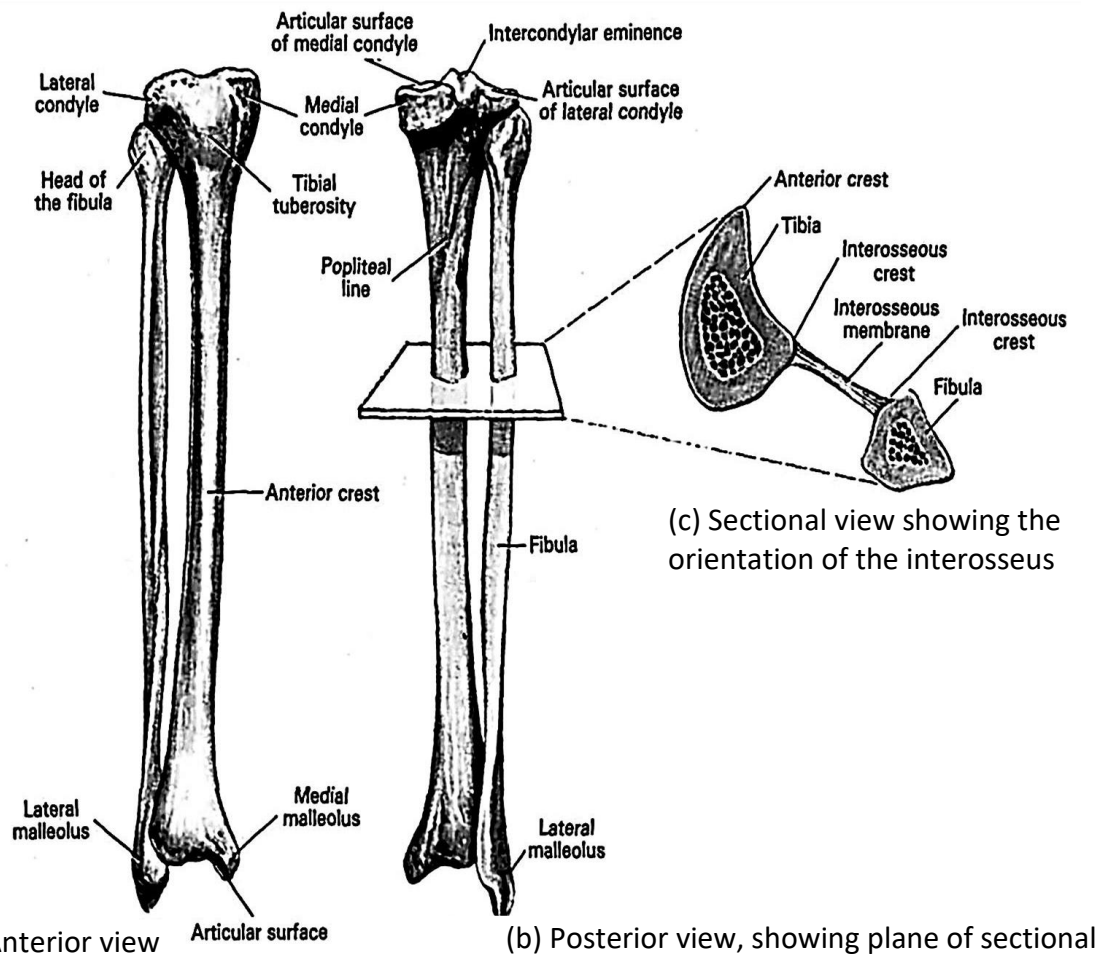


Figure 19 – Right fibula and tibia

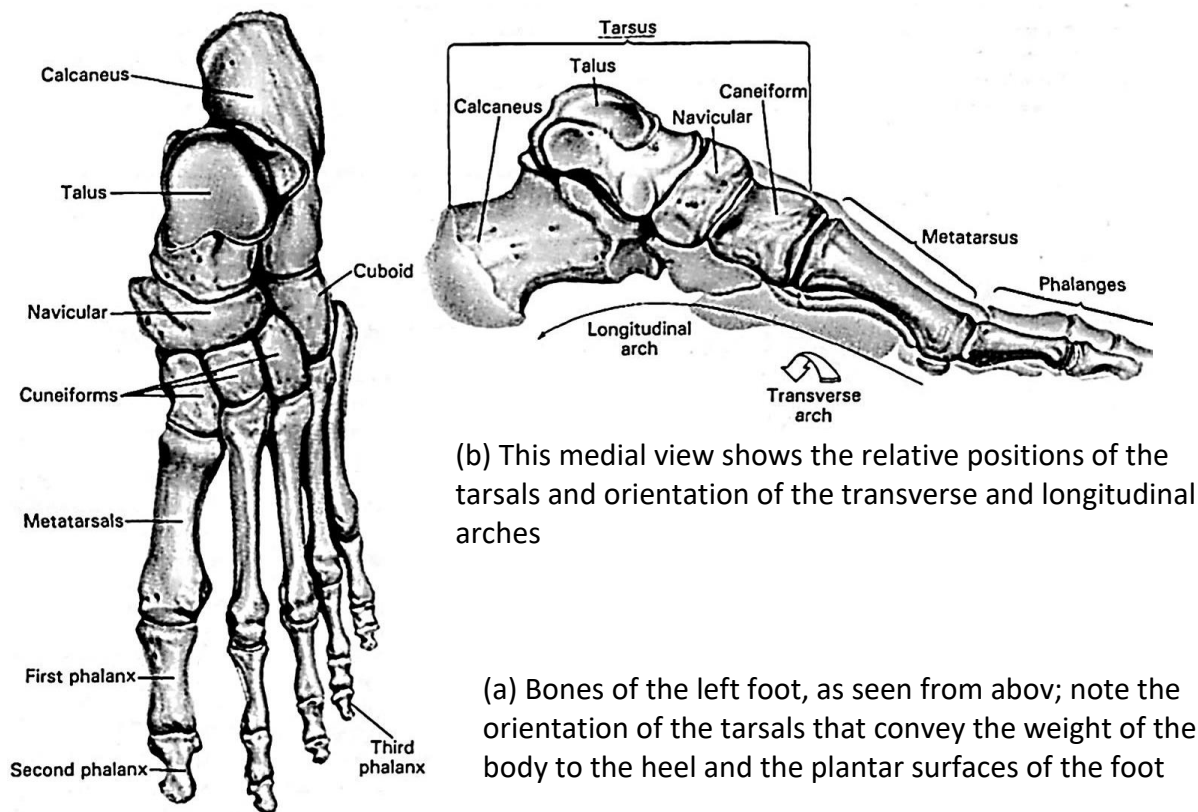


Figure 20 – Bones of the left foot



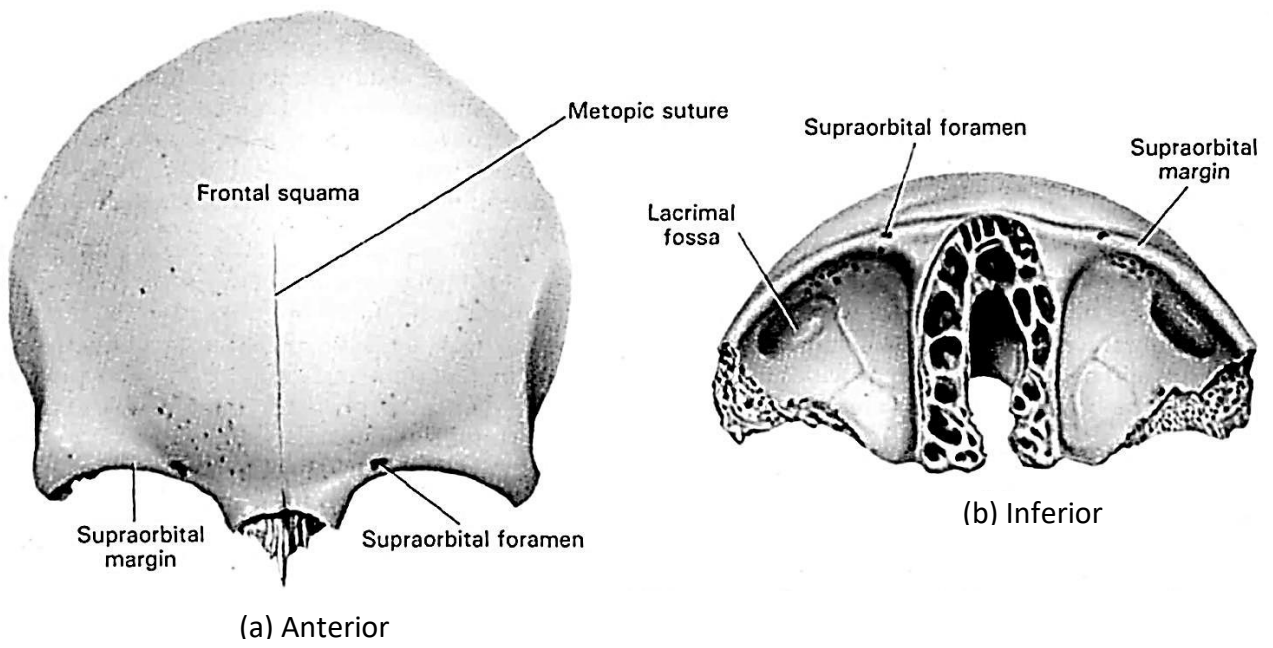


Figure 21 – The frontal bone

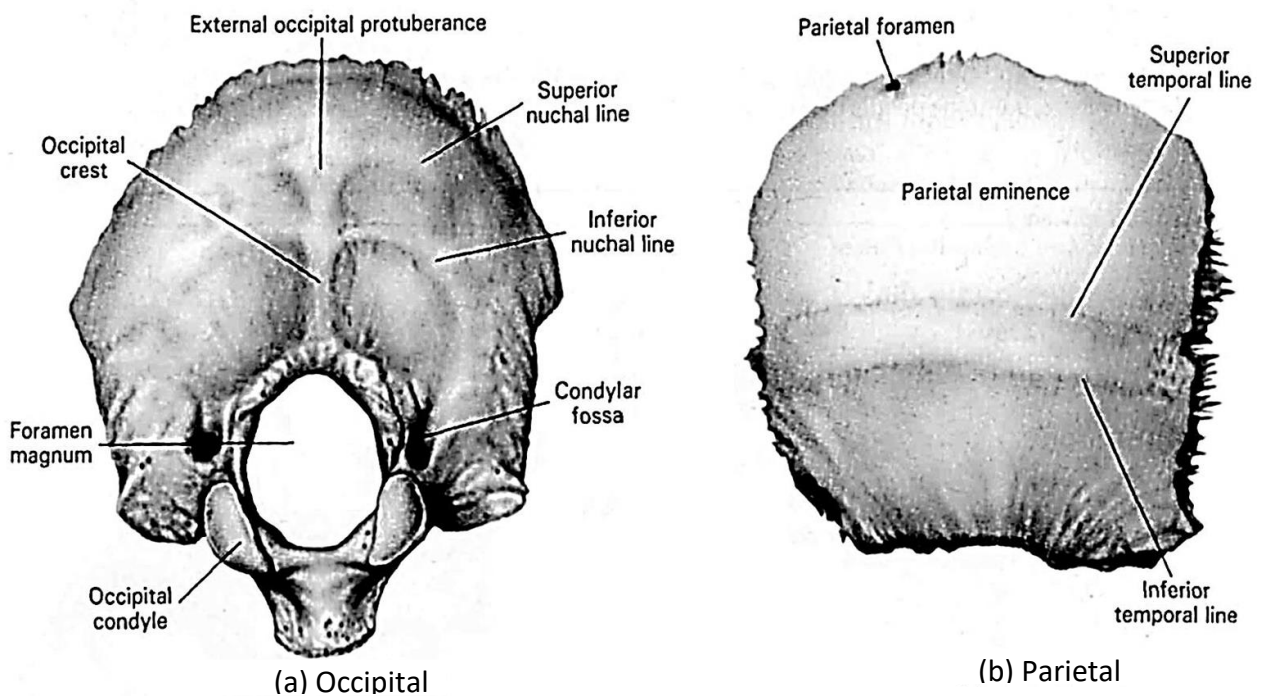
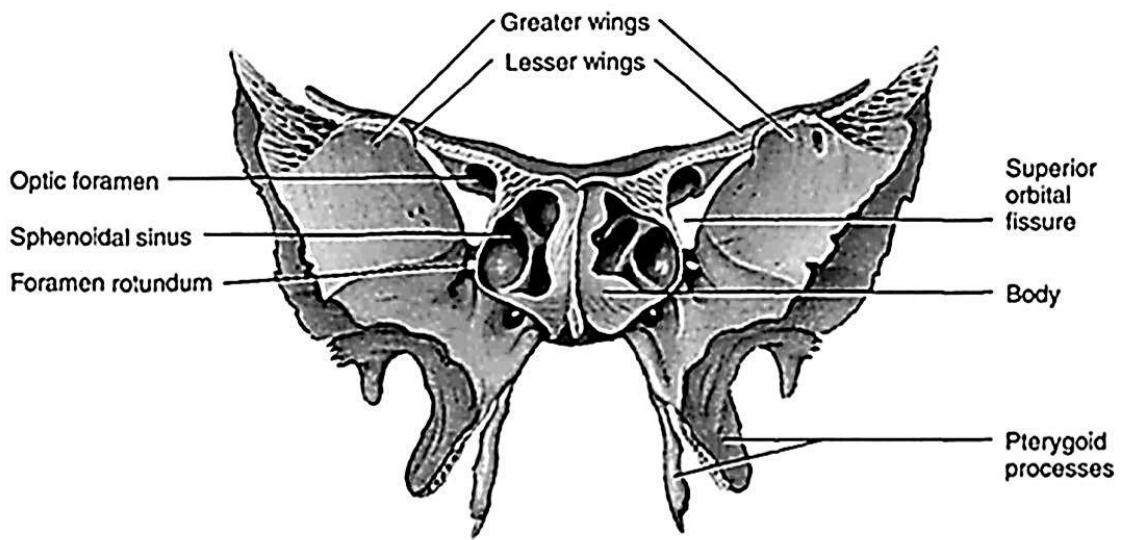
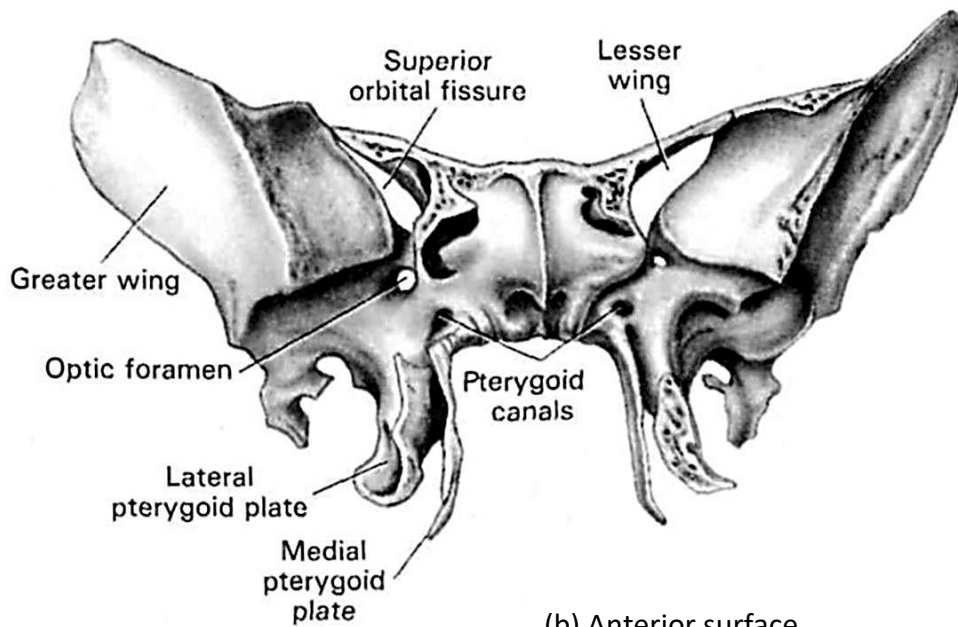


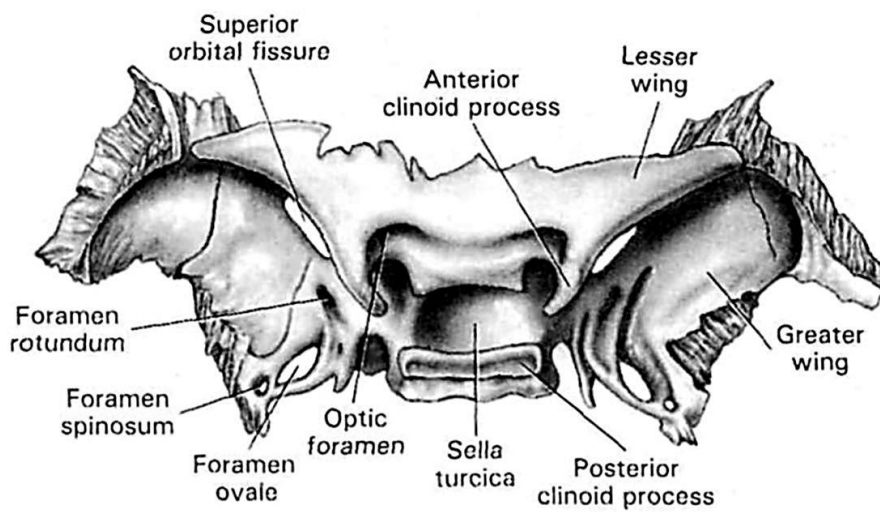
Figure 22 – The occipital and parietal bones



(a) Anterior view of sphenoid bone

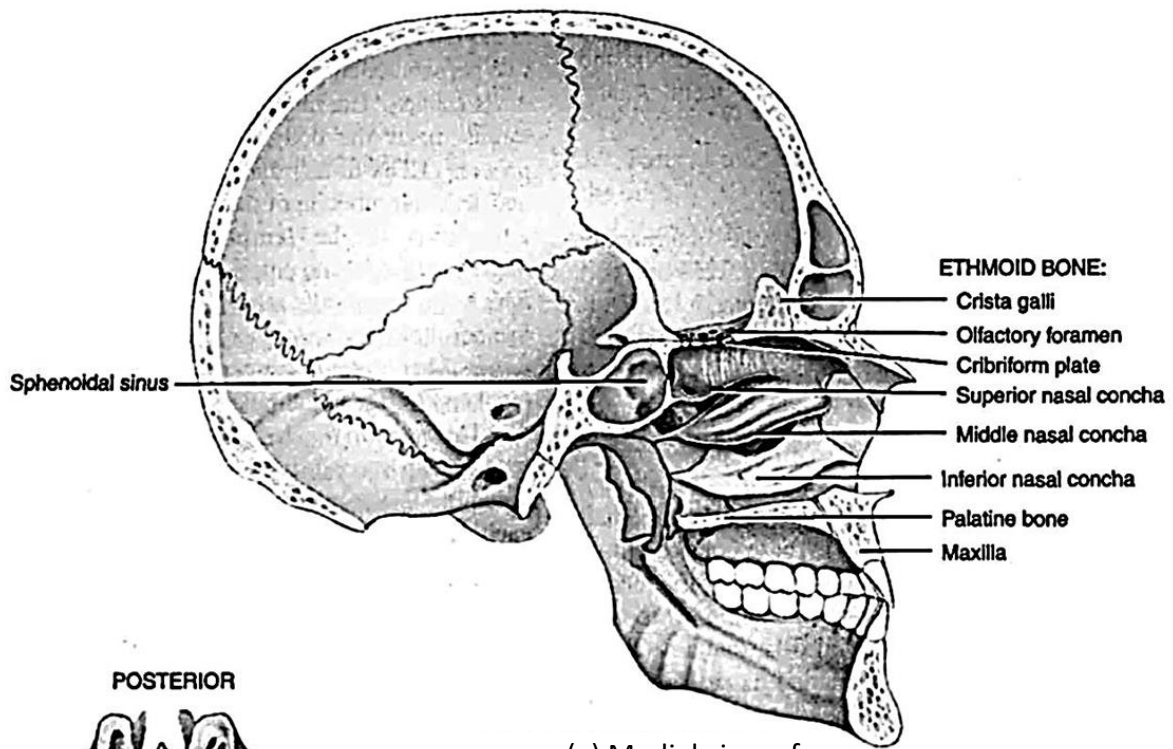


(b) Anterior surface

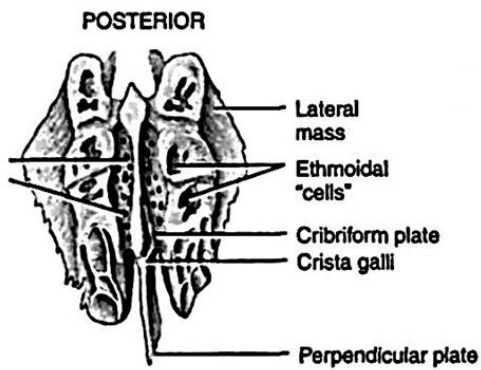


(c) Superior surface

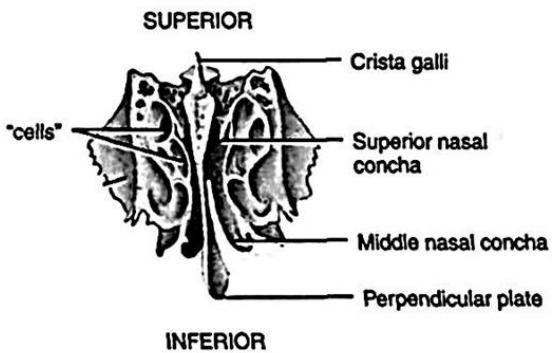
**Figure 23 – The sphenoid bone**



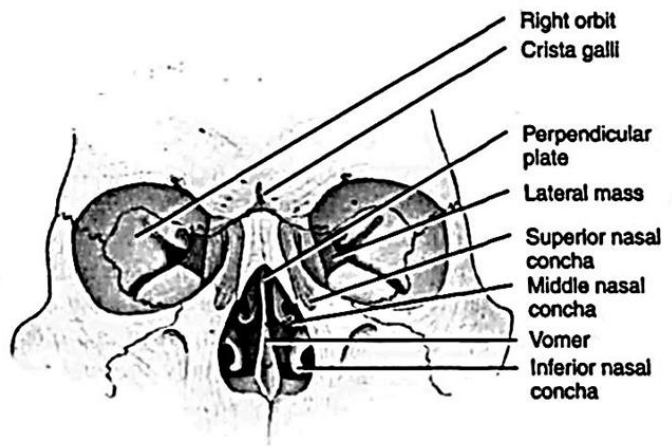
(a) Medial view of



(b) Superior view



(c) Anterior view



(d) Anterior view of position of ethmoid bone in skull

Figure 24 – The ethmoid bone

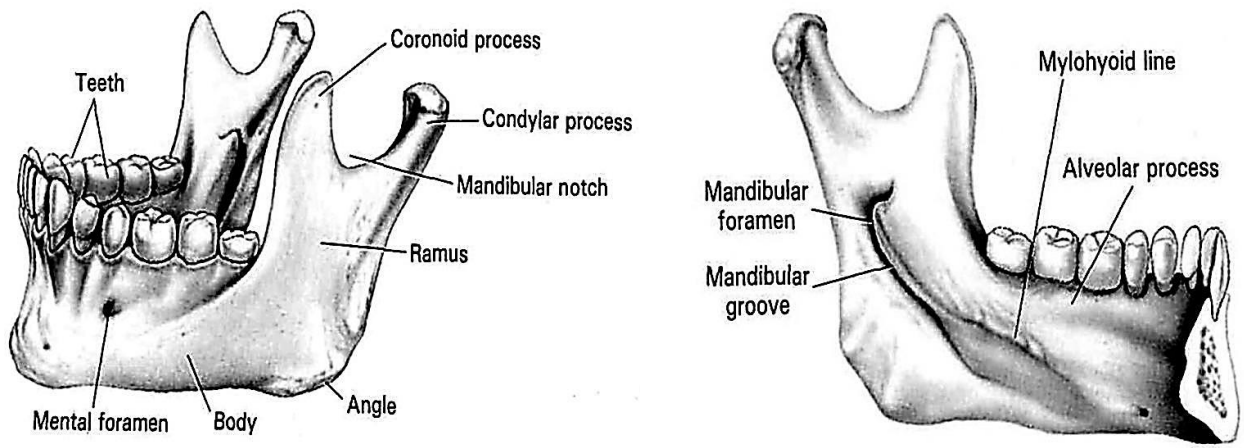


Figure 25 – The mandible

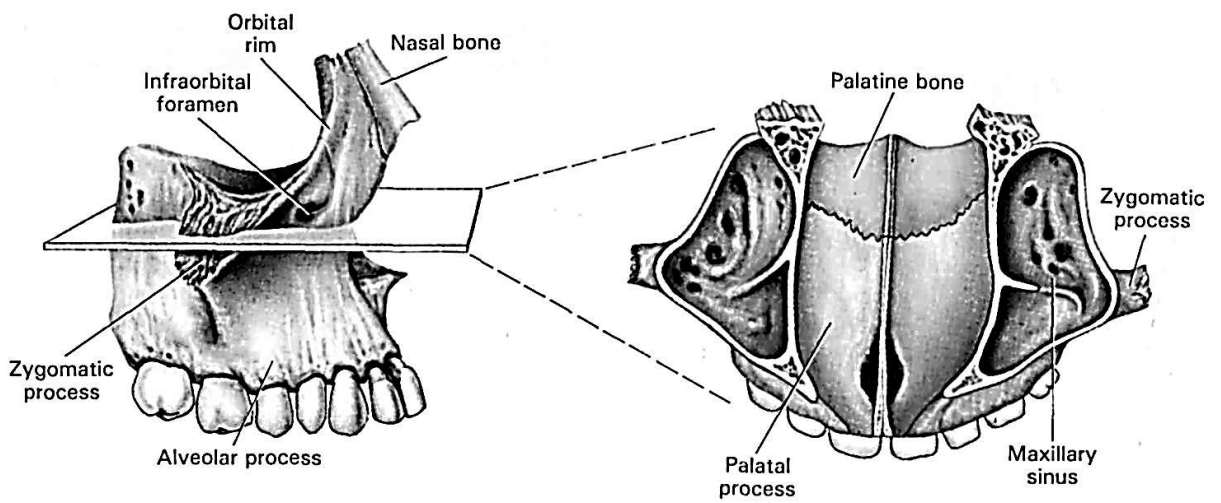


Figure 26 – The maxillae

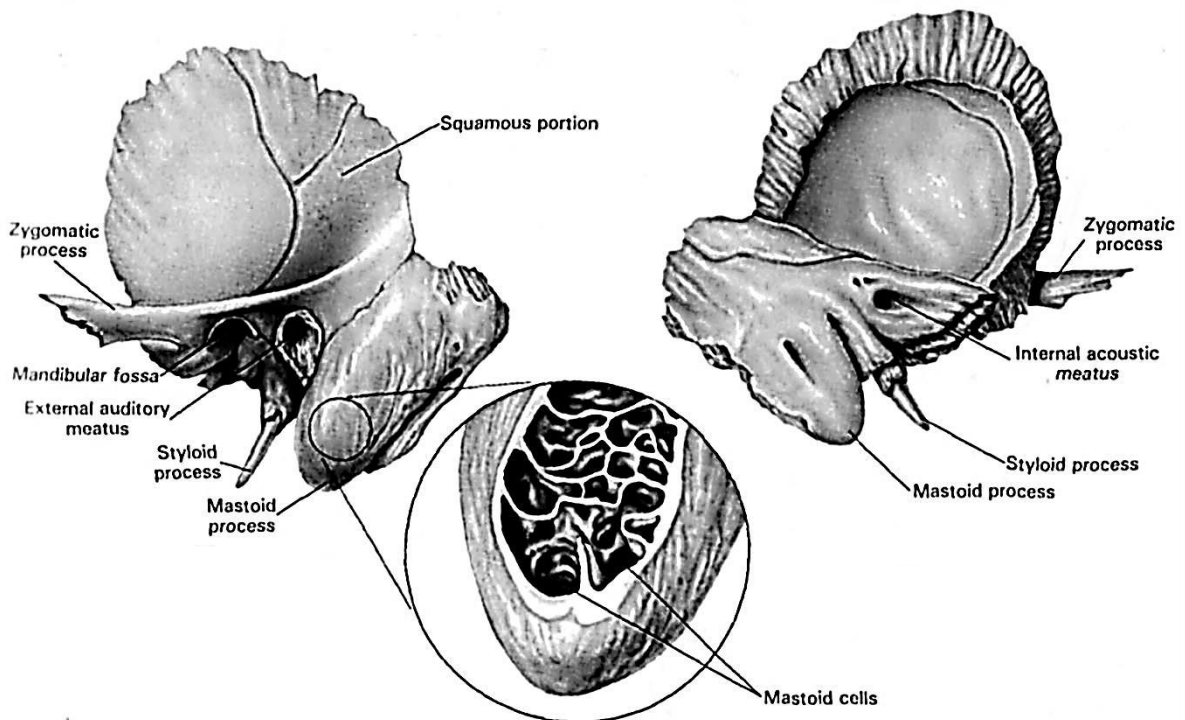


Figure 27 – The temporal bone

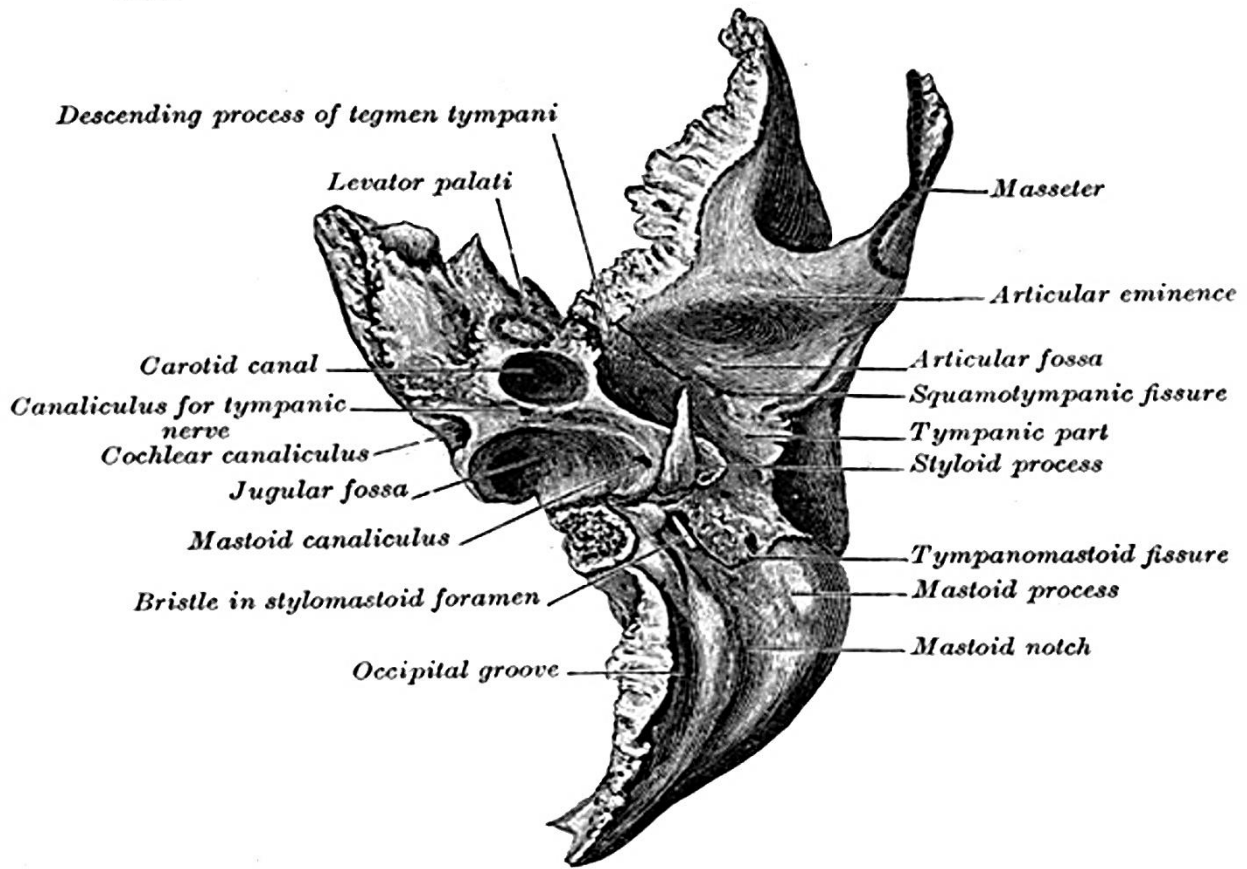
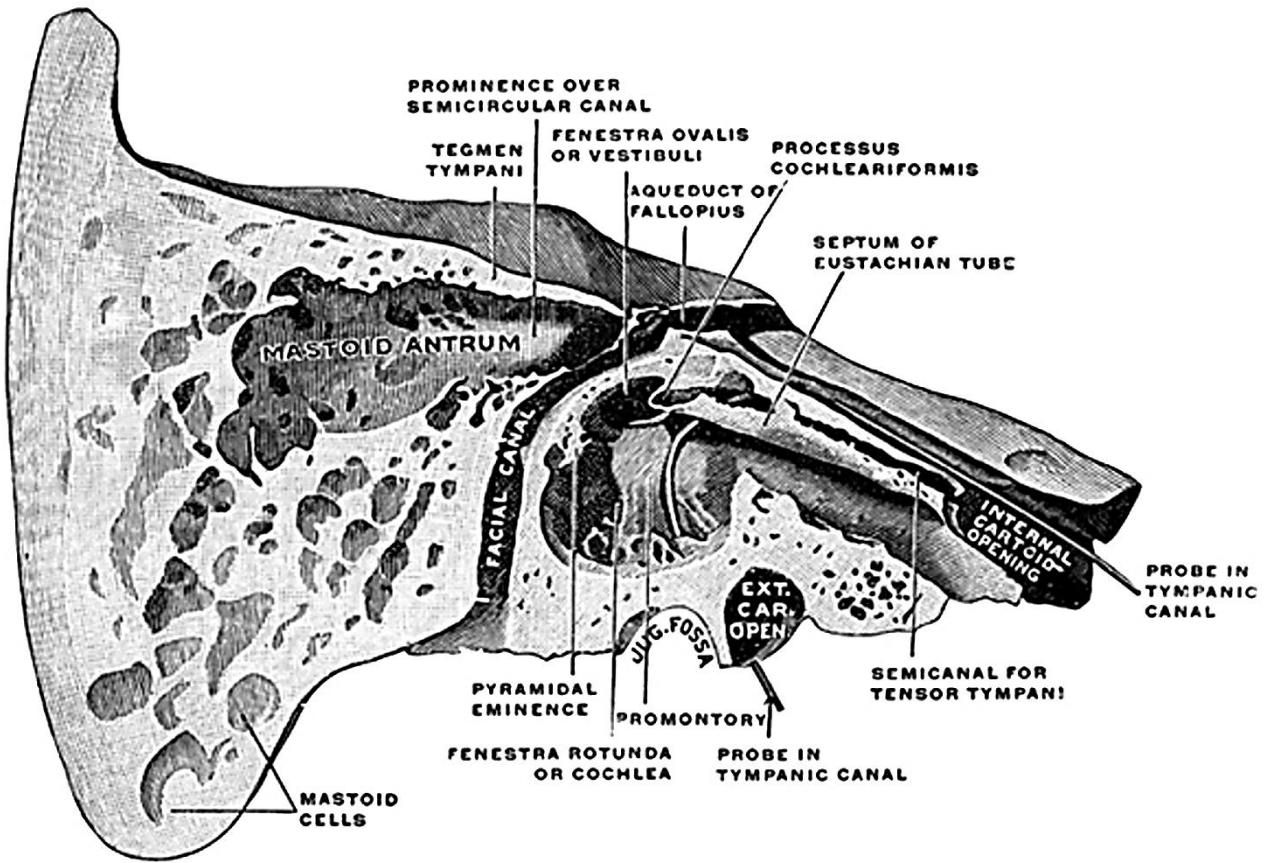


Figure 28 – Canals of the temporal bone

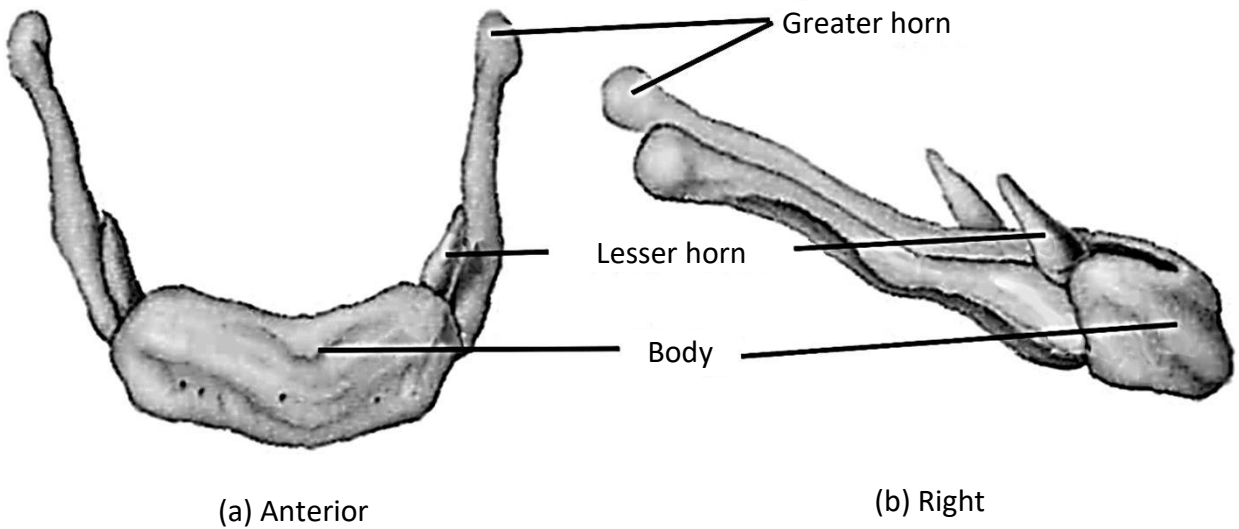


Figure 29 – The hyoid bone

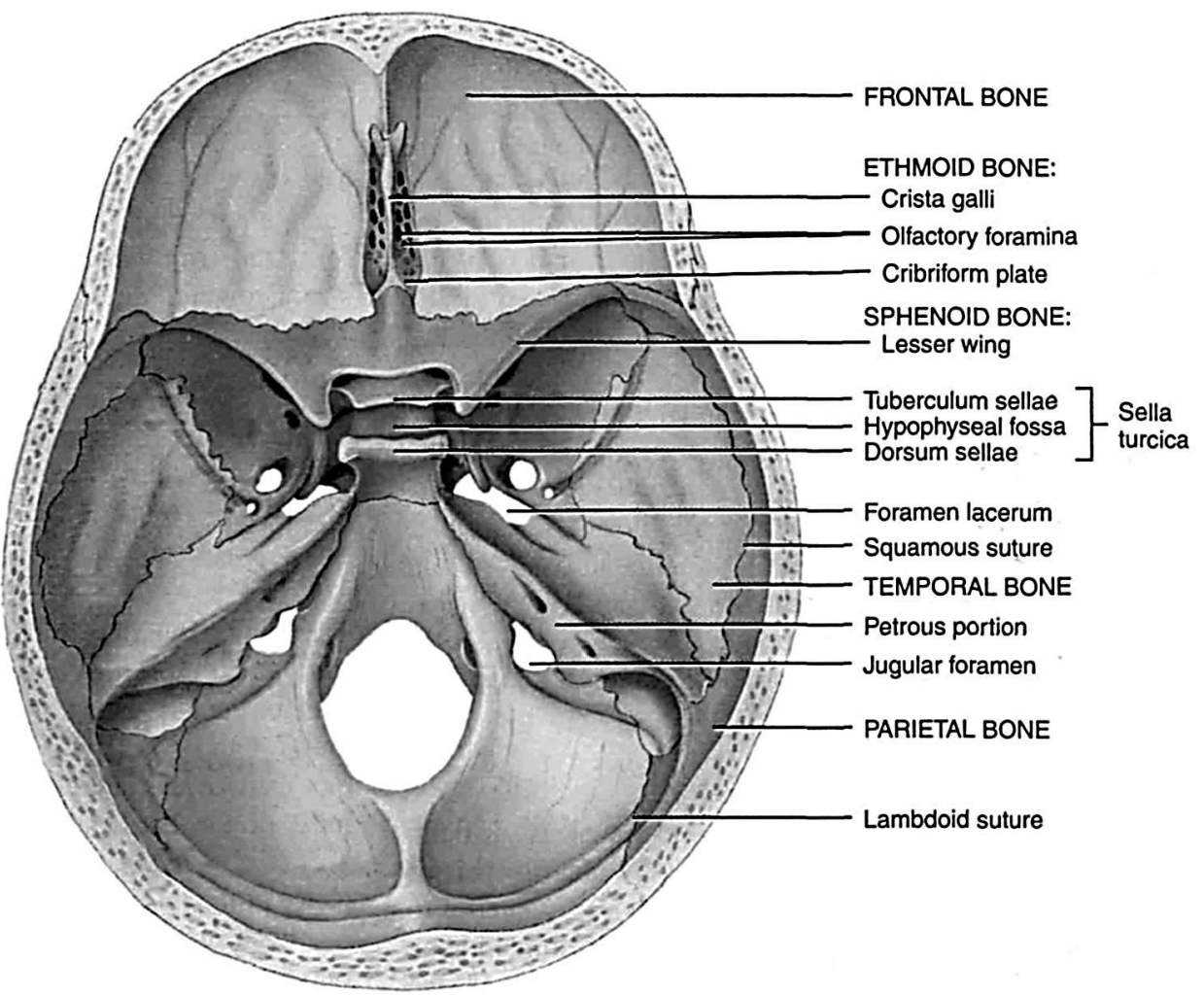


Figure 30 – The Skull. Superior view of the sphenoid bone in the cranial floor of cranium

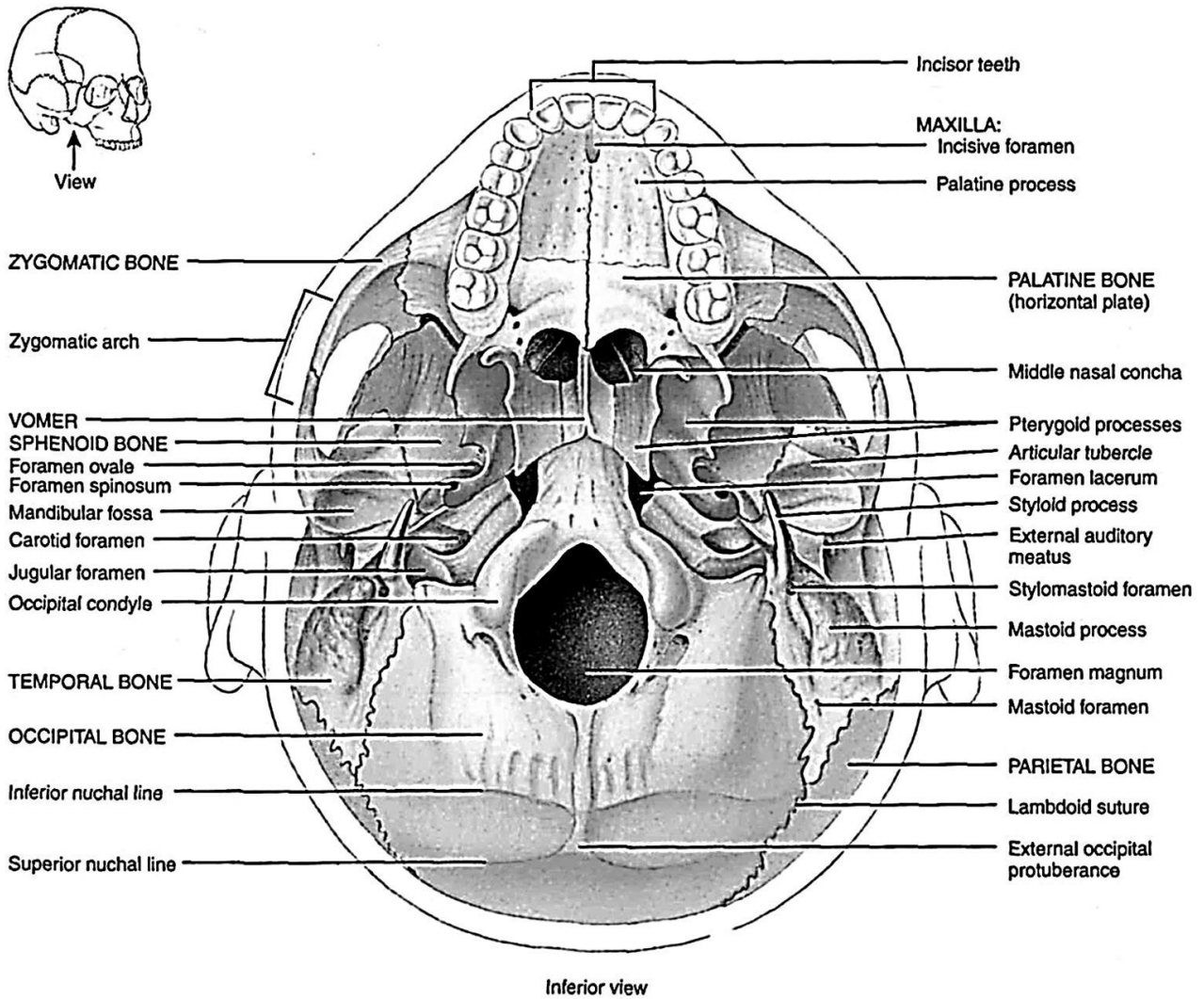
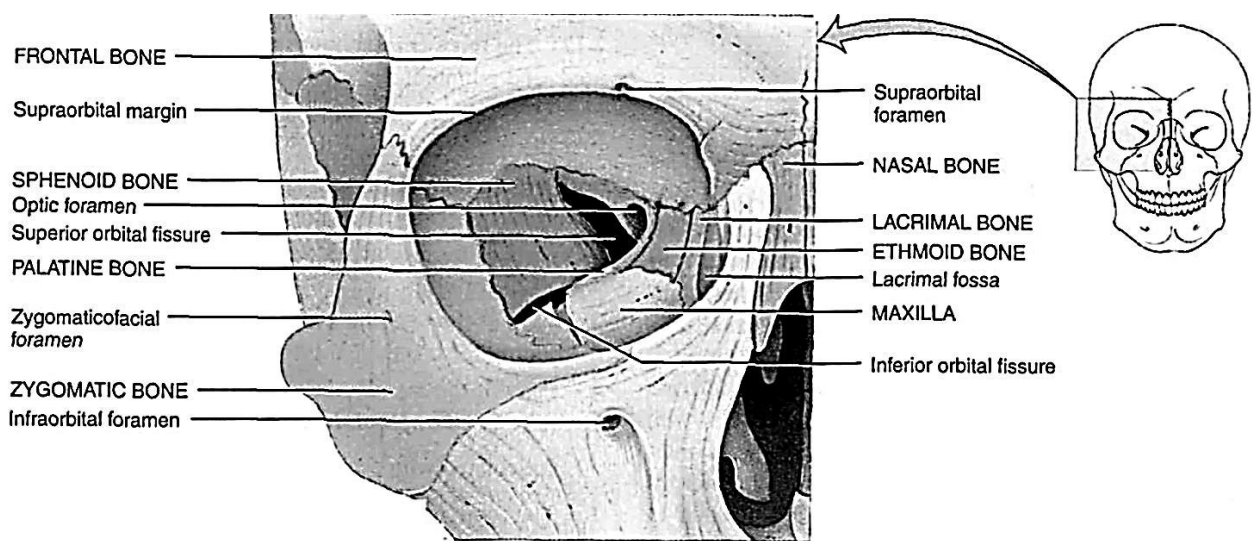


Figure 31 – Inferior view of the external surface of the base of the skull



Anterior view showing the bones of the right

Figure 32 – Details of the orbit (eye socket)

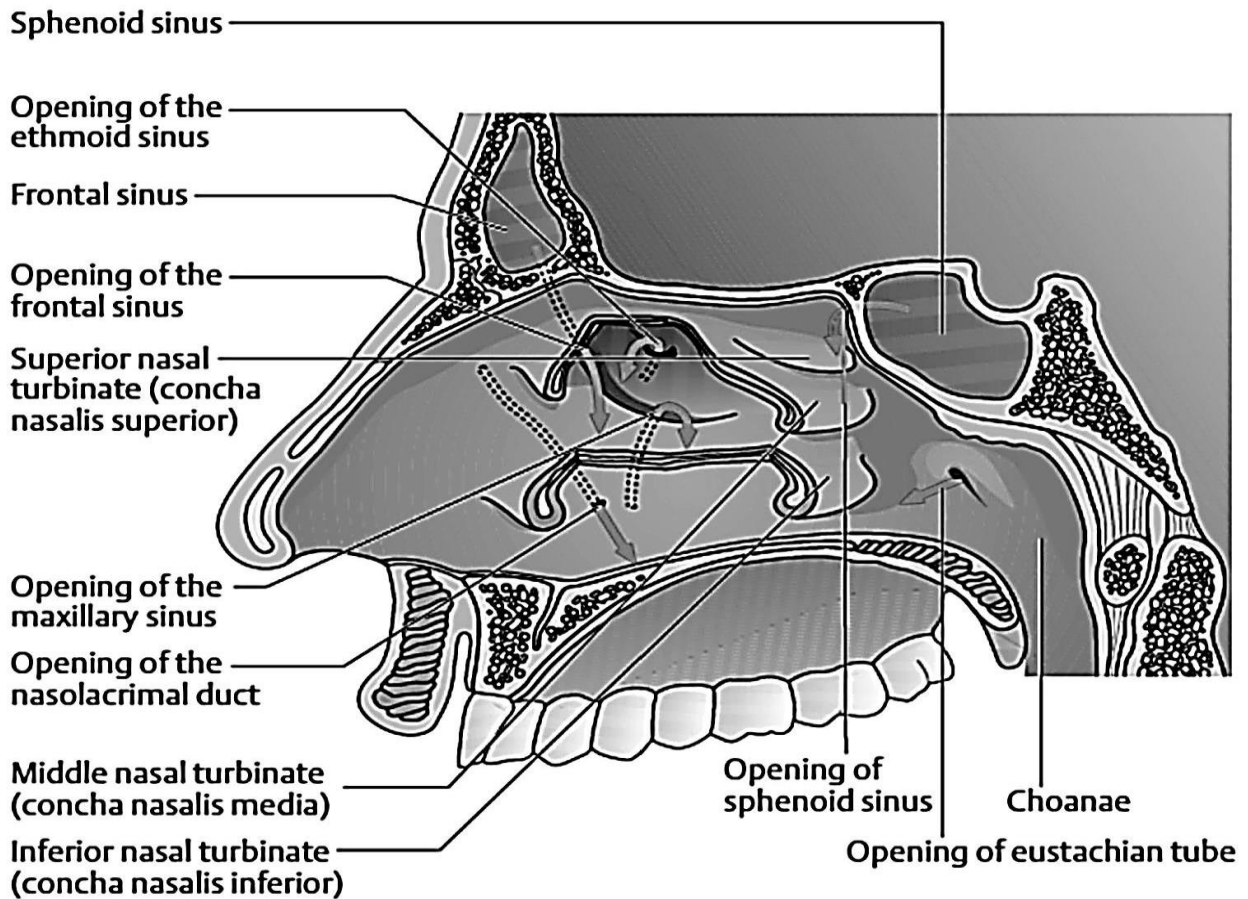


Figure 33 – Openings of the paranasal sinuses, the nasolacrimal duct, and the eustachial tube

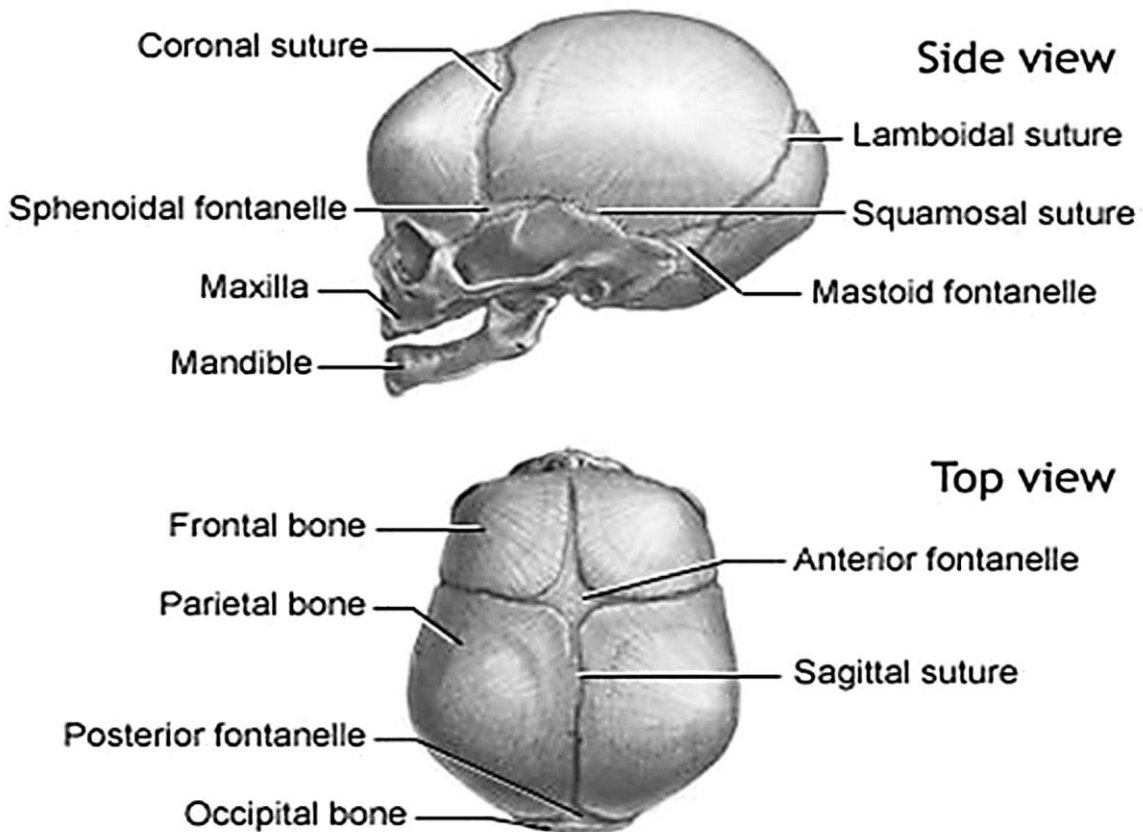


Figure 34 – (Left) Lateral view of the newborn skull. (Right) Superior view



## ARTICULAR SYSTEM

(see Figures 34 – 49)

A joint or articulation is the place of union or junction between two or more bones or parts of bones of the skeleton.

Science which studies the union of bones is called Arthrology.

### Classification of the articulations

According to development, structure and functions, all bone connections can be divided into two big and one lesser group:

1. Continuous or uninterrupted, or synarthrosis.
2. Interrupted or synovial, or diarthrosis.
3. Semi-interrupted or symphysis, or hemarthrosis (half-joint).

### Synarthrosis

According to the joint tissues, there are three types of the synarthroses: syndesmosis, synchondrosis, synostosis.

**I. Syndesmosis or fibrous articulations (*articulatio fibrosa*)** is a joint continuous joining of bones by joined means of the connective tissue.

This type of the articulation has five forms:

- 1) **the interosseous membrane**, for instance, between the bones of the forearm and bones of the leg;
- 2) **the fibrous ligaments**;
- 3) **the sutures** between the skull bones, where the intermediate connective tissue is;
- 4) **fontanelles** – between bones of the skull of the newborn;
- 5) **dento-alveolar syndesmosis or gomphosis** – an immovable articulation between the root of the tooth and the walls of the alveolar socket.

**II. Synchondrosis or a cartilaginous articulation (*junctura cartilaginea*)** is an almost immovable joint of bones by means of cartilaginous tissue. According to the duration of their existence there are two types of synchondrosis:

- 1) **a temporary synchondrosis** – **exists** during some period of time (for example, the period the ileum, pubic and ischial bones unite and form the hip bone);

- 2) **a permanent synchondrosis** – **existing** throughout the life (connection between the pyramid of the temporal and the sphenoid bones).

**III. Synostosis or bone articulation (*junctura ossea*)** is fusion of two or more bones by means of bone tissue (for example, synostosis between three bones of the hip bone in an adult).

### Diarthroses or synovial joints

The type of connection which is characterized by moveable connection of two or more bones. Synovial joints – the most common type of joints – provide free movement of bones that join and are typical for nearly all limb joints. The following components take part:

- obligate components;
- non obligate components.

#### **Obligate components:**

- 1) **the articular surfaces are covered by articular cartilage** which is hyaline or fibrous; it is smooth, reduces friction of the articular surfaces. The articular surfaces are usually congruent – they fit over each other with their size and shapes (for example, if the articular surface of one bone is convex, the articular surface of another articulating bone must be concave).

- 2) **the articular capsule** joins the bones and consists of two layers:

- fibrous membrane – external layer of synovial capsule;
- synovial membrane – internal layer of synovial capsule. It is formed by the special type of endothelial cells, which produce a special fluid – synovial fluid. It reduces friction between joint surfaces, takes part in metabolism of connecting surfaces and has an antibacterial effect. The synovial membrane often forms small projections called synovial villi. In some places it also forms synovial folds and synovial bursae, which are found around the tendons of the muscles and serve as a buffer;

- 3) **the joint cavity is closed**. It contains synovial fluid which moistens and lubricates the articular surfaces.

- 4) **the articular cartilage**. The articular surfaces are covered with articular cartilage. It acts as a

shock absorber and provides the bone ends with smooth surfaces between which there is very little friction. Their surfaces keep moist by synovial fluid which also provides nutrition to them.

**Non obligate components:**

1) **synovial membrane** of an articular capsule takes part in formation of small processes (piles) – synovial villi and synovial folds. Sometimes synovial folds contain fat tissue and form adipose folds (for example, plicae alares of the knee joint);

2) **discus or meniscus** articulares is a fibrocartilaginous articular disc that is present when the articular surfaces of the bones are incongruous. It also creates stability and complexity of joint movement (for example, lateral and medial menisci of the knee joint or the articular disc in the temporomandibular joint);

3) **synovial bursa** is a closed sac lined with a synovial membrane and filled with small amount of synovial fluid. It is usually formed in areas subject to friction, stress.

**Classification of joints**

The classification of joints can be based on the following principles:

I The number of articular surfaces.

II. The functions and the shapes of articular surfaces.

**I. According to the number of articular surfaces, there are four types of the joint** in the human skeleton:

1) **simple joint** is formed by two bones and has only two articular surfaces (for example, interphalangeal joints);

2) **compound joint** is formed by three or more bones (for example, elbow joint);

3) **complex joint** contains an intra-articular cartilage in the articular cavity. This cartilage divides the joint into two compartments (for example, temporomandibular joint);

4) **combined joint** is a combination of several isolated joints located separately, but functioning together (for example, two temporomandibular joints).

**II. The function of the joint** is determined by the number of axes on which the movement

occurs. The number of axes depends on the shape of the articulating surfaces. Proceeding from this law, the following common anatomophysiological classification of joints can be laid down:

**Uniaxial joints**

The uniaxial joints move in a single axis:

1) **pivot or trochoid joint** (articulatio trochoidea). This is a cylindrical or wheel-like joint. In pivot joints, the axis of the convex articular surface is parallel to the vertical body axis. These articulations allow rotation (for example, the median atlanto-axial joint);

2) **hinge-joint** (ginglymus). One articular surface of this joint has a guiding groove, and another articular surface has a crest, which is located in this guiding groove and facilitates movements along a single axis: flexion and extension on frontal axis (for example, the interphalangeal joints).

**Biaxial joints**

The biaxial joints move in two axes:

1) **ellipsoid joint** (articulatio ellipsoidea). The articular surfaces are segments of the ellipse: one of them is convex, another is concave. They allow movements in two horizontal axes which are perpendicular to each other: flexion and extension in the frontal axis, and abduction and adduction in the sagittal axis (for example, the radiocarpal or wrist joint);

2) **condyloid joint** (articulatio bicondylaris). One articular surface has a convex articular head in the form of a protruding rounded process, which resembles an ellipse in shape, and is called "a condyle". A depression on the articular surface of the other bone corresponds to the condyle, though the difference in their size may be considerable (for example, atlanto-occipital joint);

3) **saddle joint** (articulatio sellaris). Saddle joint is appropriately named because the opposing surfaces of the bones are shaped like a saddle (for example, the carpometacarpal joint of the thumb).

Biaxial joints also permit a change of movement from one axis to another, i.e., movement in a circular manner, circumduction.

### **Multiaxial joints**

These articulations move in a number of axes. In these highly movable joints, the spheroidal surface of one bone moves within the socket of another. Flexion and extension, abduction and adduction, medial and lateral rotation and circumduction can occur at multiaxial joints.

**Ball-and-socket** or spherical joints (articulatio spherioidea). One of the articular surfaces forms a convex spherical head, another – a correspondingly concave articular surface (for example, the shoulder joint).

**Cotyloid joint** (articulatio cotylica). A variety of the ball-and-socket joint is the cotyloid joint. The articular fossa of one bone is deep and embraces the greater part of the convex spherical head of another bone. As a result the movement at this joint is more restricted than at a typical ball-and-socket joint (for example, the hip joint).

**Plane joints** (articulatio plana). The opposite surfaces of the bones are flat or almost flat. They allow movements on all three axes, but the range of movements is very small because the articular surfaces differ only slightly. These articulations permit gliding or sliding movements (for example, the sacro-iliac joint).

### **Joint biomechanics**

Movements at the joints occur on three main axes. The following types of joint movements are distinguished:

1) **movements in the frontal axis:** flexion (flexio) and extension (extensio);

2) **movements in the sagittal axis:** adduction (adductio) (moving toward the median plane) and abduction (abduction) (moving away from it);

3) **movement in the vertical axis:** rotation (rotatio), inward rotation is called pronation (pronatio), and outward rotation is called supination (supinatio);

4) **movement in the circular** manner is called circumduction (circumductio).

### **Type of movement:**

<b>General terms</b>	
Extension (motion)	Movement increasing the angle between two body parts
Flexion	Movement decreasing the angle between two body parts
Abduction	Movement away from the midline
Adduction	Movement towards the midline
External rotation	Rotation away from the midline
Internal rotation	Rotation towards the midline
Elevation (motion)	Movement in a superior direction
Depression (motion)	Movement in an inferior direction
Anteversion	Forward inclination of an entire organ
Retroversion	Backward inclination of an entire organ
Circumduction	Circular motion of a limb
Pronation	<b>Hand/forearm:</b> with the arms extended at the sides, rotation so that the palms are facing posteriorly <b>Foot:</b> eversion + dorsiflexion
Supination	<b>Hand/forearm:</b> with the arms extended at the sides, rotation so that the palms are facing anteriorly. It is when the palm is turned upward, such as when carrying a bowl of <b>soup!</b> <b>Foot:</b> inversion + plantar flexion

### **Hemiarthrosis or semi-interrupted joints**

When a narrow gap that does not have the character of a true articular cavity with an articular surface and capsule is formed in the center of the synchondrosis, the articulation becomes transitional from the continuous to the interrupted types of joints. This articulation is called a half-joint or hemiarthrosis or symphysis (the joint between two pubic bones – the pubic symphysis).

### **Articulations of the vertebrae**

The human vertebral column has all types of bone articulations, which can be divided into articulations between the bodies and articulations between their arches: syndesmoses (ligaments between the arches and processes), synchondroses (cartilages between the bodies of the vertebrae), synostoses (bony articulations of sacral and coccygeal vertebrae), hemiarthroses (half-joint between the bodies of some vertebrae), and diarthroses (between the articular processes).

#### **Articulations of the vertebral bodies**

The vertebral bodies articulate with each other (and also with the sacrum) by means of synchondroses called intervertebral cartilages (discs) or by means of hemiarthroses, if there are clefts between them. Each disc is a plate of fibrocartilage which consists of two parts:

- **peripheral part is the fibrous ring** (annulus fibrosus);
- **central part is the gelatinous nucleus** (nucleus pulposus).

The column of the vertebral bodies is reinforced by two longitudinal ligaments:

- the anterior longitudinal ligament stretches on the anterior surface of the vertebral bodies and discs from the tubercle on the anterior arch of the atlas to the upper part of the pelvic surface of the sacrum;
- the posterior longitudinal ligament extends from the second cervical vertebra downward on the posterior surface of the vertebral bodies in the vertebral canal to the upper end of the canalis sacralis.

#### **Intervertebral articulations**

The arches and their processes are units by diarthroses and syndesmoses.

1. The spaces between the arches are filled with fibres of yellow colour which are called yellow ligaments (ligamenta flava).

2. The ligaments between spinous processes are the interspinous ligaments. The ligament stretches over apices of the spinous processes and is called supraspinous ligament. In the cervical part of the spine, it is called nuchal ligament.

3. Ligaments between transverse processes are the intertransverse ligaments.

### **Articulations of the skull bones**

The bones of the skull articulate mainly by syndesmoses, which are sutures on the skulls of adults and interosseous membranes (fontanelles) on the skulls of newborns. In the skull's sutures the fibres of the intermediate connective tissue are present, therefore, these articulations are related to the syndesmoses.

#### **Sutures of the skull are of the following:**

1) **the serrate sutures** (sutura serrata) are between bones of the cap (vault) of the skull. Following serrate sutures of the skull are present:

- sutura coronalis – between frontal and two parietal bones;
- sutura sagittalis – between two parietal bones;
- sutura lambdoidea – between occipital and two parietal bones;

2) **a squamous suture** (sutura squamosa) is between the squama of the temporal bone and the parietal bone;

3) **plane sutures** (sutura plana) are between the bones of the visceral skull.

The fontanelles of the skull of the newborn permit the bones of the vault of the skull to be displaced during delivery. They are:

1) **a rhomboid anterior fontanelle** (fonticulus anterior) located on midline at the intersection of four sutures (sagittal, frontal and two halves of the coronal sutures). It closes by the ending of the first year of life;

2) **a triangular posterior fontanelle** (fonticulus posterior) located at the posterior end of the sagittal suture between two parietal bones and the occipital bone. It closes in the second month of life;

3) **paired lateral fontanelles**: two sphenoidal and two mastoid. They close over on the skull of the infants by 18–24 months.

The base of the skull has synchondroses in the fissures between the bones: the petrooccipital synchondrosis (synchondrosis petrooccipitalis) is between the pyramid of the temporal bone and the basilar part of the occipital bone; the sphenopetrosal synchondrosis (synchondrosis sphenopetrosa) is between temporal and sphenoid bones; the sphenoccipital synchondrosis (synchondrosis sphenoccipitalis) is between the body of the sphenoid bone and the basilar part of the occipital bone.

### **The vertebral column**

Although the spine is a vertical column, it is not straight but curved in the sagittal plane. The curvatures in the thoracic and sacral parts are posteriorly convex, while those in the cervical and lumbar segments are anteriorly convex. A curvature posteriorly convex is called kyphosis; an anteriorly convex curvature is called lordosis.

The spine of a newborn is almost straight and the curvatures are hardly formed.

At old age the spine loses its curvatures, because of diminution of the intervertebral discs of the vertebrae and the loss of elasticity, the spine bends forward forming a single big curvature (kelso's hunchback or senile kyphosis). The vertebral column becomes much shorter. Its length at old age may reduce by 5 – 6 cm.

### **The thoracic cage as a whole**

The thoracic cage has two apertures: the superior (inlet) and the inferior (outlet), which is closed by a muscular partition, diaphragm.

The anterior border of the inferior aperture forms the infrasternal angle of the thorax. The vertebral column protrudes into the thoracic cavity on the midline and forms a wide pulmonary sulci to sides of the column between it and ribs. The spaces between the ribs are called intercostal spaces.

Three chest shapes are usually distinguished: flat chest, barrel chest, and conic chest.

Individuals with well-developed muscles and lungs have a wide but short thoracic cage, which acquires a conic shape. The infrasternal angle is large.

In contrast, individuals with weak muscles and lungs the chest acquires a flat shape. The infrasternal angle is acute.

The barrel chest occupies an intermediate position between the two forms described.

### **Joints of the pelvic bones**

There are all types of joints in the human pelvis.

#### **1. Syndesmoses:**

- the false ligaments of the pelvis – the sacrotuberal and sacrospinal ligaments – are two strong ligaments connecting on the hip bone with the sacrum each side. The sacrotuberal ligament stretches from the ischial tuberosity to the lateral borders of sacrum and coccyx. The sacrospinal ligament stretches from the ischial spine to the lateral borders of sacrum and coccyx. These ligaments transform the greater and lesser sciatic notches to the greater and lesser sciatic foramina (foramen ischiadicum majus et minor);

- the obturator membrane is a fibrous plate closing the obturator foramen of the pelvis, except in its superolateral part, where between this membrane and obturator groove of the pubis, the obturator canal (canalis obturatorius) is formed.

2. **Synchondroses** are between the separate parts of the hip bone in the acetabulum (under 18 years old), and synostoses after their fusion to form the hip bone (in adulthood).

3. **Hemiarthrosis:** the pubic symphysis (symphysis pubica) is on midline and joins the pubic bones. A fibrocartilaginous plate, the interpubic disc, is lodged between the facies symphysialis of these bones. A narrow synovial slit-like cavity is in this disc. The pubic symphysis is reinforced by the superior pubic ligament and the inferior pubic ligament.

4. **Diarthrosis:** the sacroiliac joint.

### **The pelvis as a whole**

Both hip bones are jointed with each other and to the sacrum to form a bony ring, the pelvis. The bony ring is divided into two parts:

- **a wide upper part**, the greater (false) pelvis (pelvis major);

- **a narrow lower part**, the lesser (true) pelvis (pelvis minor).

The greater pelvis is bounded only laterally by ilia, which are rather widely spread out. It has no bony wall in front. Posterior wall is formed by the body of the fifth lumbar vertebra.

**The terminal line (pelvic brim)**, which separates pelvis major and pelvis minor, is formed by:

- **the promontorium;**
- **arcuate line of the ilia;**
- **the pectines of the pubic bones;**
- **the superior border of the pubic symphysis.**

The opening, thus bounded, is called the pelvic inlet (apertura pelvis superior). Below the inlet, there is the cavity of the true pelvis (cavum pelvis).

**The walls of pelvic cavity** are formed:

- **anteriorly** – by the pubic bones and the pubic symphysis;
- **posteriorly** – by sacrum and coccyx;
- **laterally** – by area of the hip bones corresponding to the acetabuli; ischial tubers, sacrotuberal and sacrospinous ligaments.

Below the pelvic cavity ends as the pelvic outlet (apertura pelvis inferior).

The measurements of the pelvis are used by obstetricians for prediction of the child delivery process. The dimensions of the greater pelvis are:

1) **interspinous distance** is the distance between the two superior anterior iliac spines. Its length is about 25 – 26 cm;

2) **intercristal distance** (diameter) is the distance between the two iliac crista. Its length is about 28 – 29 cm;

3) **intertrochanteric distance** is a distance between two greater trochanters. Its length is about 30 – 32 cm.

The dimensions of the lesser pelvis are divided into dimensions of the pelvic inlet and pelvic outlet

The dimensions of pelvic inlet are:

1) **true conjugate or conjugata vera** seu gynaecologica is the distance between promontorium and projection on the internal surface of the pubic symphysis. Its length is about 11 cm;

2) **anatomical conjugate** – between the promontorium and superior border of the pubic symphysis. Its length is about 11.5 cm;

3) **diagonal conjugate** – between the promontorium and the inferior border of the pubic symphysis. Its length is about 12 cm;

4) **transverse diameter** – between the arcuate line of the ilia. Its length is about 13 cm;

5) **oblique diameter** – between the sacroiliac joint and opposite iliopubic eminence. Its length is about 12 cm.

The dimensions of pelvic outlet are:

1) **transverse diameter** of the pelvic outlet – between the medial borders of the ischial tuberosities. Its length is about 11 cm;

2) **the anteroposterior diameter** of the pelvic outlet – between the inferior border of the pubic symphysis and apex of the coccyx. Its length is about 9 – 11 cm.

**Sex differences of a pelvis are in the following:**

1) the iliac wings are spread out more widely in females;

2) the male sacrum is relatively narrow and more concave;

3) the female sacrum is relatively wider but at the same time flatter;

4) the promontory projects farther forward in a male pelvis;

5) a junction of the inferior pubic rami has the shape of an arch (arcus pubis) in a well developed female pelvis but forms an arcuate angle (angulus subpubicus) in a male pubis.

### **The foot as a whole**

Among small joints of the foot there are two specific Chopart's and Lisfranc's joints.

**Chopart's joint**, or transverse tarsal joint, or midtarsal joint, is formed by the articulation between the calcaneus and cuboid bones, and articulation between the talus and navicular bone. Chopart's joint is reinforced with *bifurcate ligament*. It serves as a "key" of Chopart's joint because its cutting leads to a wide divergence of the articular surfaces.

**Lisfranc's joint** is a complex joint formed by the tarsometatarsal and intermetatarsal joints.

The "key" of Lisfranc's joint is the medial cuneometatarsal ligament.

Partial amputations of the foot are carried out along the lines of the transverse tarsal joint or tarsometatarsal joints.

### **The arches of the foot**

The foot is constructed and functions as a resilient flexible arch. Five longitudinal arches and one transverse arch are distinguished in the whole arch structure of the foot. Each longitudinal arch is made up of one metatarsal bone and parts of the tarsal bones located between it and the tuberosity of the calcaneus. The longitudinal arches, joined in the anterior part in the form of a parabola, form the transverse arch of the foot. The bony arches are maintained by the shape of the bones, forming them and by the muscles and the fascia. The muscles are active "tightening devices". When the apparatus, described, loses its strength, the foot becomes flat.

## JOINTS OF THE BODY

No	Name	Articular surface	Type	Shape	Function	Axes of movement	Movement	Ligament
1	Temporo-mandibular joint	head of the mandible, mandibular fossa of a temporal bone	complex, combined	bicondylar	2 axes	frontal, sagittal	elevation, depression, retraction, protraction, side to side	lateral ligament reinforces the joint capsule; stylomandibular and sphenomandibular ligaments stabilize a mandible
2	Atlanto-occipital joint	occipital condyles, superior articular surfaces of the atlas	combined	bicondylar	2 axes	frontal, sagittal	bending forward, backward and laterally	anterior and posterior atlanto occipital membranes
3	Atlanto-axial joint: • middle atlantoaxial joint; • lateral atlantoaxial joint	anterior and posterior facets of the dens, facet of atlas for dens; transverse ligament;  inferior articular facets of atlas; superior articular facets of the axis	combined;  combined	cylindrical (pivot);  plane	1 axis;  3 axes	vertical;  vertical	rotation to the right and left;  slightly movable	apical ligament of the dens alar ligaments, cruciate ligament of the atlas (transverse lig. and longitudinal bands), tectorial membrane
4	Zygapophyseal (intervertebral) joints	articular surfaces of the superior and inferior articular processes	combined	plane	3 axes	frontal, vertical, sagittal	flexion, extension, rotation, bending side to side	anterior and posterior longitudinal ligaments; ligamenta flava; interspinous and supraspinous ligaments; intertransverse ligament
5	Costovertebral joints: • joint of the head of the rib;  • costovertebral joint	superior and inferior costal facets (demifacets) of adjacent thoracic vertebrae, head of the rib;  tubercle of the rib, and transverse costal facet	combined, complex (II – X);  combined	ball-and-socket (spherical);  cylindrical (pivot)	3 axes;  1 axis	sagittal;  sagittal	rotation;  rotation	radiate ligament of the head of the rib; intra-articular ligament (II – X joints); costovertebral ligament
6	Sternocostal joint	anterior end of the costal cartilage and costal notch of the sternum	simple	plane	3 axes	vertical, frontal, sagittal	limited	radiate sternocostal ligament, intra-articular ligament (for 2-nd joint)
7	Acromioclavicular joint	acromial end of the clavicle and the articular surface of the acromion	simple (1/3 complex)	plane	3 axes	vertical, frontal, sagittal	limited	acromioclavicular ligament; coracoclavicular ligament: trapezoid ligament; conoid ligament

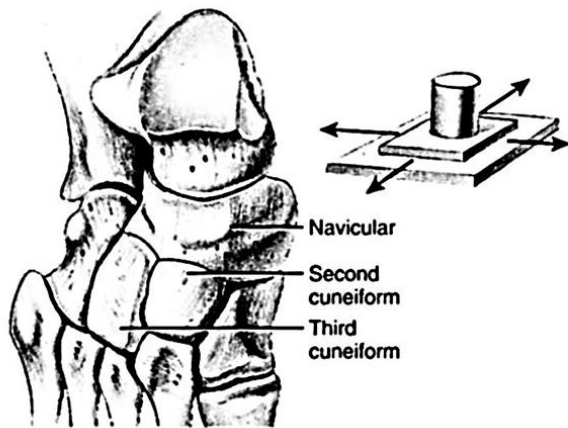
No	Name	Articular surface	Type	Shape	Function	Axes of movement	Movement	Ligament
8	Shoulder joint (art. humeri)	glenoid cavity of the scapular and the head of the humerus	simple	ball-and-socket (spherical)	3 axes	vertical, frontal, sagittal	rotation; flexion and extension; abduction and adduction	coracohumeral ligament
9	Elbow joint: • humeroulnar joint;  • humeroradial joint;  • proximal radioulnar joint	trochlea of the humerus and the trochlear notch of the ulna;  capitulum of the humerus and the head of the radius;  articular surface on the head of the radius and the radial notch of the ulnar	compound hinge;  spherical;  cylindrical	hinge	1 axis	frontal	flexion and extension	ulnar collateral ligament; radial collateral ligament; annular ligament, quadrata ligament
10	Distal radioulnar joint	head of the ulna and ulnar notch of the radius	combined	cylindrical	1 axis	vertical	supination, pronation	
11	Radiocarpal (wrist) joint	carpal articular surface of the radius, the articular disc; the proximal row of the carpus (the lunate, triquetral and scaphoid bones)	compound	ellipsoid	2 axes	frontal;  sagittal	flexion and extension; adduction and abduction circumduction	ulnar collateral ligament of the wrist; radial collateral ligament of the wrist; dorsal and palmar radiocarpal ligaments
12	Midcarpal joint  Intercarpal joint	articulating surfaces of the first and second rows of carpal bones  neighbouring bones of the wrist	compound  compound	combination of 2 balls (hinge)  plane	1 axis  3 axes	fronta  frontal, sagittal vertical	flexion, extension  limited	radiate carpal ligament; palmar intercarpal ligament; dorsal intercarpal ligament; interosseous intercarpal ligament
13	Carpometacarpal joints	articular surfaces on the second row of carpal bones and the bases of metacarpal bones	compound	plane	3 axes	frontal, sagittal, vertical	limited	dorsal carpometacarpal ligament; palmar carpometacarpal ligament



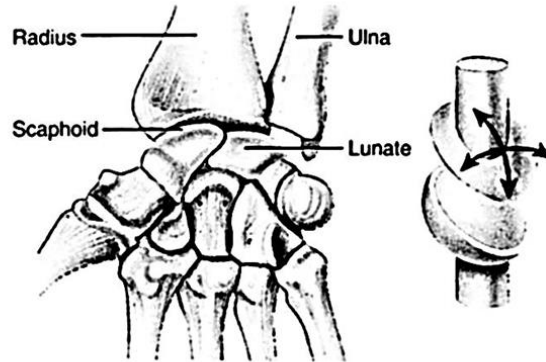
No	Name	Articular surface	Type	Shape	Function	Axes of movement	Movement	Ligament
14	Carpometacarpal joints of thumbs	articular surface of the trapezium and the I metacarpal bone	simple	saddle	2 axes	frontal sagittal	flexion, extension, abduction, adduction of the thumb, circumduction	dorsal carpometacarpal ligament; palmar carpometacarpal ligament
15	Intermetacarpal joints	adjoining sides of the bases of II – V metacarpal bones	compound	plane	3 axes	frontal, sagittal, vertical	limited	dorsal metacarpal ligament; palmar metacarpal ligament; interosseous metacarpal ligament
16	Metacarpophalangeal joint	head of the metacarpal bone and the base of the proximal phalanx	simple	ball-and-socket (spherical)	2 axes	frontal, sagittal	flexion, extension, abduction, adduction, circumduction	palmar ligament; collateral ligament; deep transverse metacarpal ligament
17	Interphalangeal joint	head and base of the adjacent phalanges	simple	hinge	1 axis	frontal	flexion, extension	palmar ligament; collateral ligament
18	Sacroiliac joint	auricular surfaces of the sacrum and hip bone	simple	plane	3 axes	frontal, sagittal, vertical	limited	anterior sacroiliac ligament; posterior sacroiliac ligament; interosseous sacroiliac ligament
19	Coxal or hip joint	semilunar surfaces of the acetabulum and the head of the femur	simple	cotyloid (cup)	3 axes	frontal, sagittal, vertical	flexion, extension, abduction, adduction, rotation, circumduction	transverse acetabular ligament; orbicular zone; iliofemoral ligament; ischiofemoral ligament; pubofemoral ligament; ligament of the head of the femur

No	Name	Articular surface	Type	Shape	Function	Axes of movement	Movement	Ligament
20	Knee joint	medial and lateral condyles of the femur; superior articular surfaces of the tibia; patellar surfaces of the femur and patella	complex	condyloid	2 axes	frontal, vertical	flexion, extension, rotation (when the leg is bent)	intraarticular ligament: transverse ligament of the knee, anterior cruciate ligament; posterior cruciate ligament; extra-articular ligament; fibular collateral ligament, tibial collateral ligament, oblique popliteal ligament, arcuate popliteal ligament, patellar ligament, medial patellar ligament, lateral patellar ligament
21	Tibiofibular joint	fibular articular surface of the tibia; articular surface of the head of the fibular	simple	plane	3 axes	frontal, sagitta, vertical	limited	anterior and posterior ligaments; fibular head
22	Ankle or talocrural joint	inferior articular surfaces of the tibia; articular surfaces of the trochlea of the talus; medial and lateral malleoli	compound	hinge	1 axis	fronta	flexion (plantar flexion); extension (dorsal flexion) when the foot is flexed there are movements to the sides	anterior talofibular ligament; posterior talofibular ligament; calcaneofibular ligament; medial (deltoid) ligament: tibionavicular, tibiocalcaneal; anterior and posterior tibiotalar parts
23	Subtalar joint	posterior talar articular surface of the calcaneus; posterior calcaneal articular surface of talus	simple	cylindrical (pivot)	1 axis	sagittal	pronation and supination	
24	Talocalcaneonavicular joint	articular surface of the head of talus; the navicular bone; anterior and middle talar articular surfaces of the calcaneus; anterior and middle calcaneal articular surfaces of talus	compound	ball-and-socket (spherical)	3 axes	frontal, sagitta, vertical	adduction with supination and plantar flexion; abduction with pronation and dorsiflexion	
25	Calcaneocuboid joint	articular surfaces of the calcaneus and cuboid bones	simple	plane	3 axes	frontal, sagitta, vertical	limited	long plantar ligament; calcaneocuboid ligament

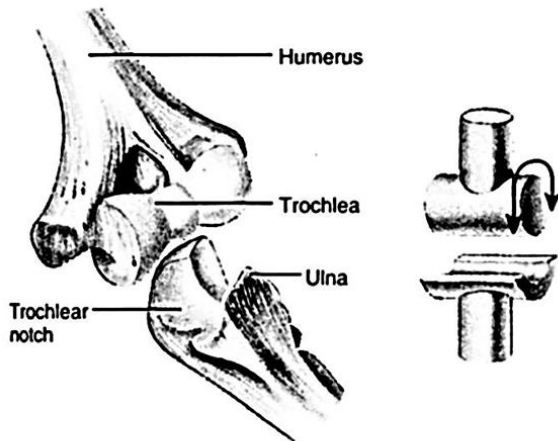
No	Name	Articular surface	Type	Shape	Function	Axes of movement	Movement	Ligament
26	Transverse tarsal joint or Chopart's joint	consists of the talonavicular and the calcaneocuboid joints						bifurcate ligament: calcaneocuboid ligament; calcaneonavicular ligament
27	Cuneonavicular joint	articular surfaces of the navicular bone; lateral, medial and intermediate cuneiform bones	compound	plane	3 axes	frontal, sagittal, vertical	limited	plantar dorsal cuneiform ligaments; interosseous; intercuneiform ligaments; plantar and dorsal intercuneiform ligaments
28	Tarsometatarsal joint	articular surfaces of the navicular and cuneiform bones and the bases of the metatarsal bones	compound	plane	3 axes	frontal, sagittal, vertical	limited	dorsal and plantar tarsometatarsal ligaments; interosseous cuneometatarsal ligament
29	Intermetatarsal joint	adjacent bases of the metatarsal bones	compound	plane	3 axes	frontal, sagittal, vertical	limited	dorsal and plantar metatarsal ligaments; metatarsal interosseous ligament
30	Metatarsophalangeal joint	heads of the metatarsal bones and bases of the proximal phalanges	simple	ball-and-socket (spherical)	2 axes	frontal, sagittal	flexion and extension; abduction and adduction	deep transverse metatarsal ligament; collateral ligament; plantar ligament
31	Interphalangeal joint	bases and heads of the neighbouring phalanges of the foot	simple	hinge	1 axis	frontal	flexion and extension	collateral ligament; plantar ligament



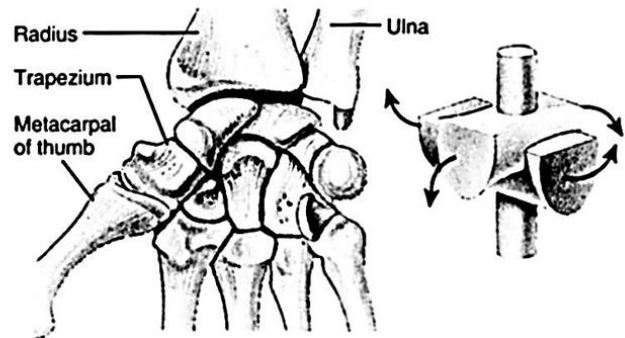
(a) Planar joint between the navicular and second and third cuneiforms of the tarsus in the foot



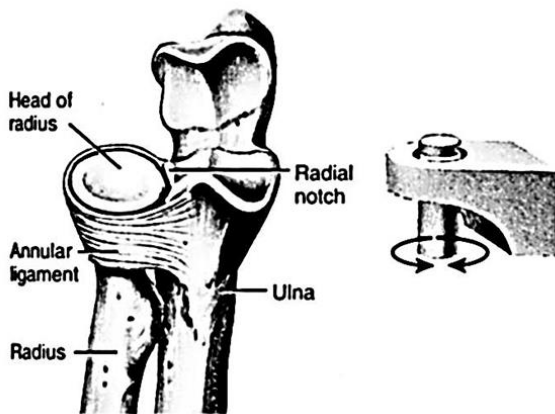
(d) Condyloid joint between radius and scaphoid and lunate bones of the carpus (wrist)



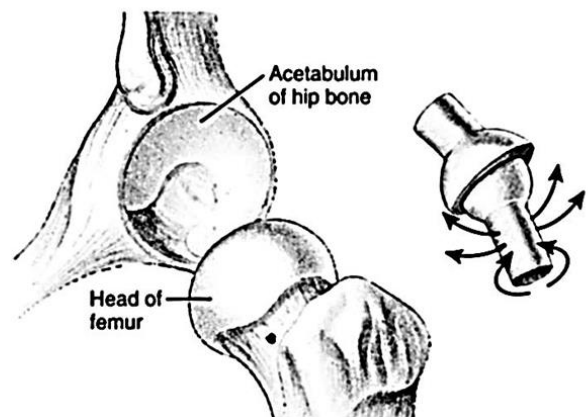
(b) Hinge joint between trochlea of humerus and trochlear notch of ulna at the elbow



(e) Saddle joint between trapezium of carpus (wrist) and metacarpal of thumb



(c) Pivot joint between head of radius and radial notch of ulna



(f) Ball-and-socket joint between head of the femur and acetabulum of the hip bone

Figure 35 – Functional classification of synovial joints

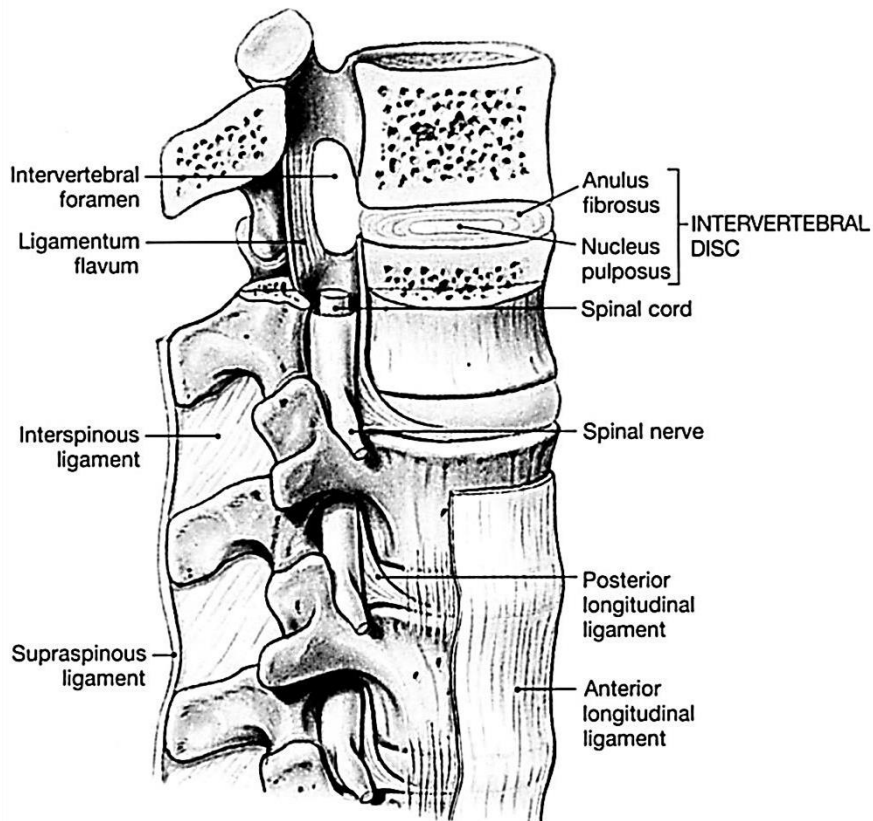


Figure 34 – Articulated vertebrae

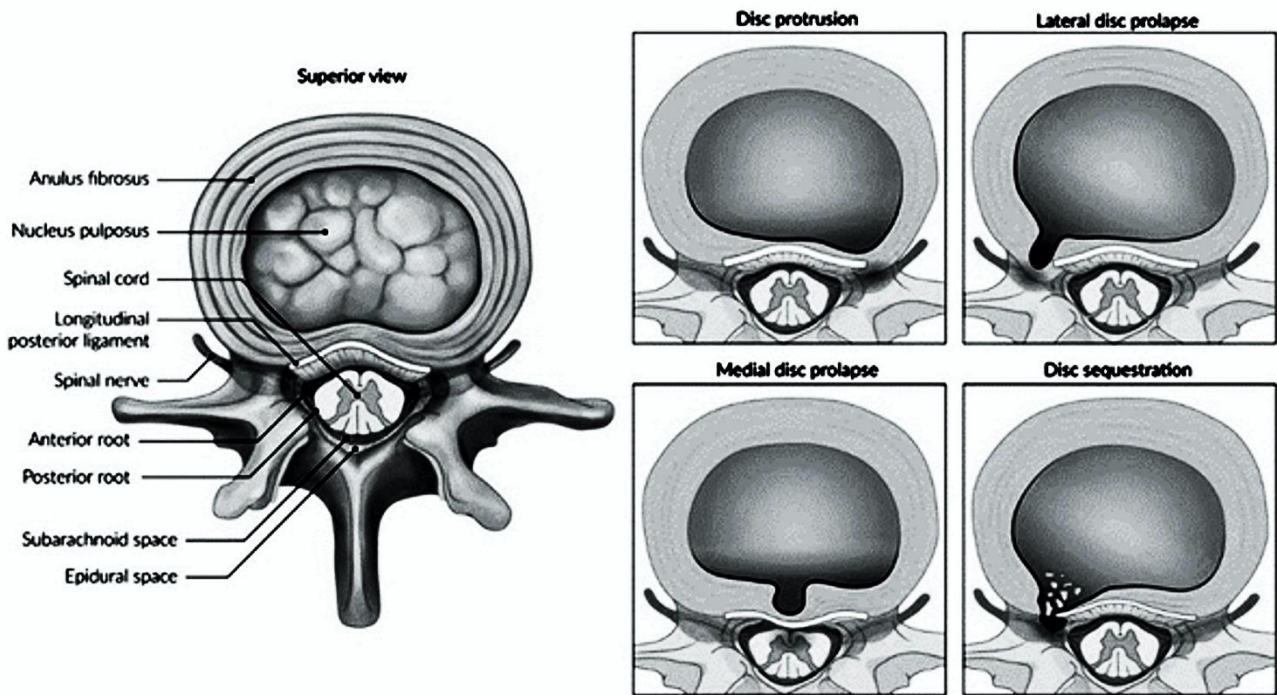


Figure 36 – Intervertebral disc

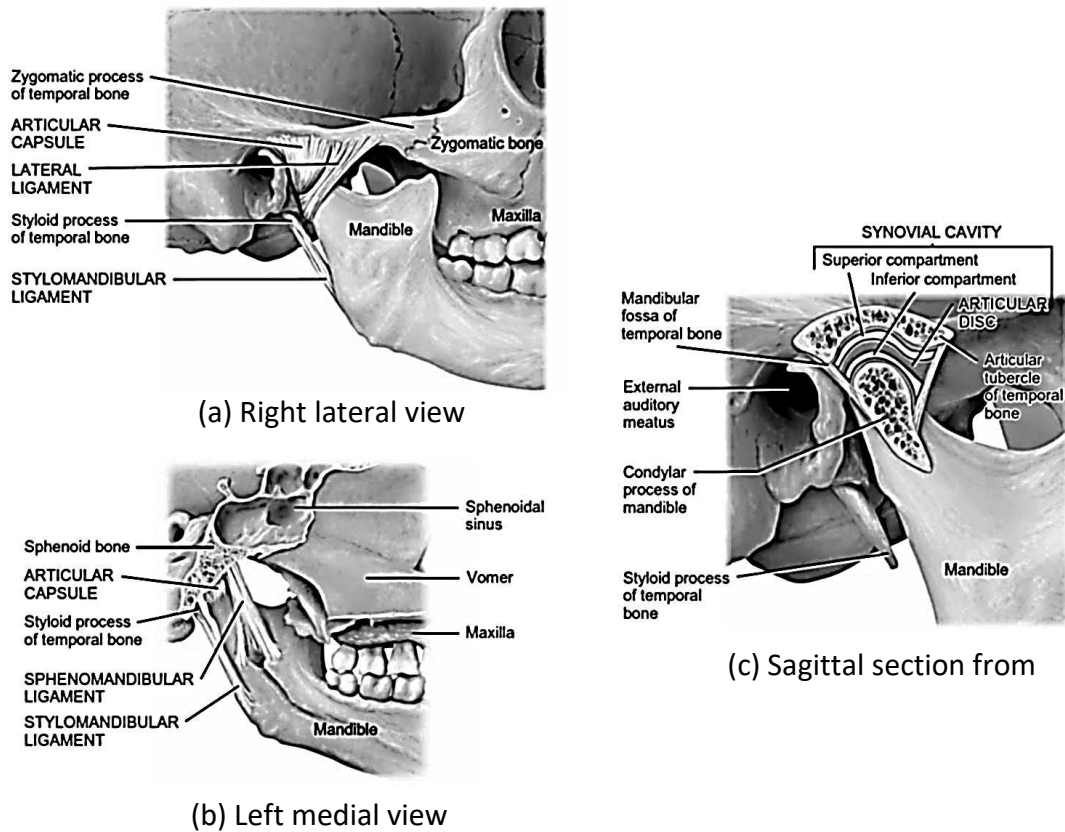


Figure 37 – The temporomandibular joint

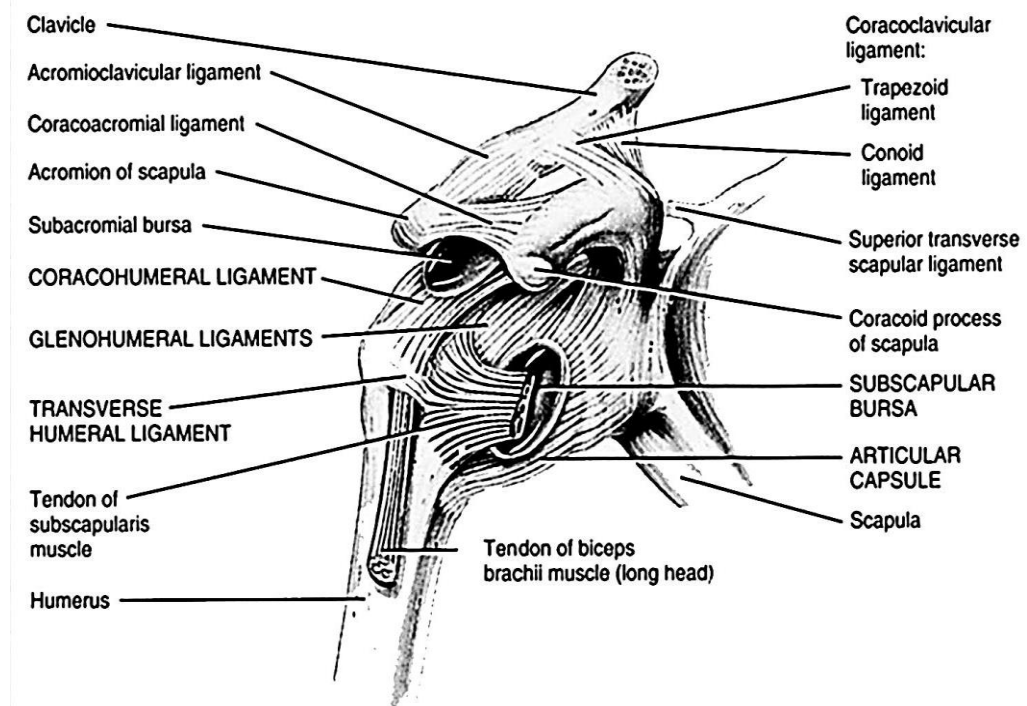
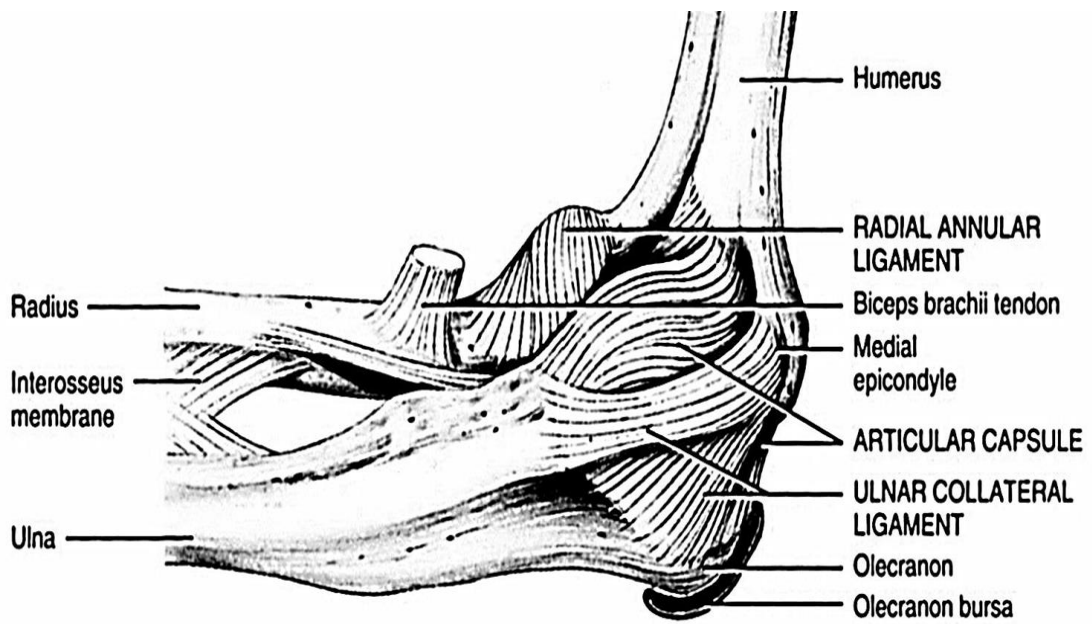
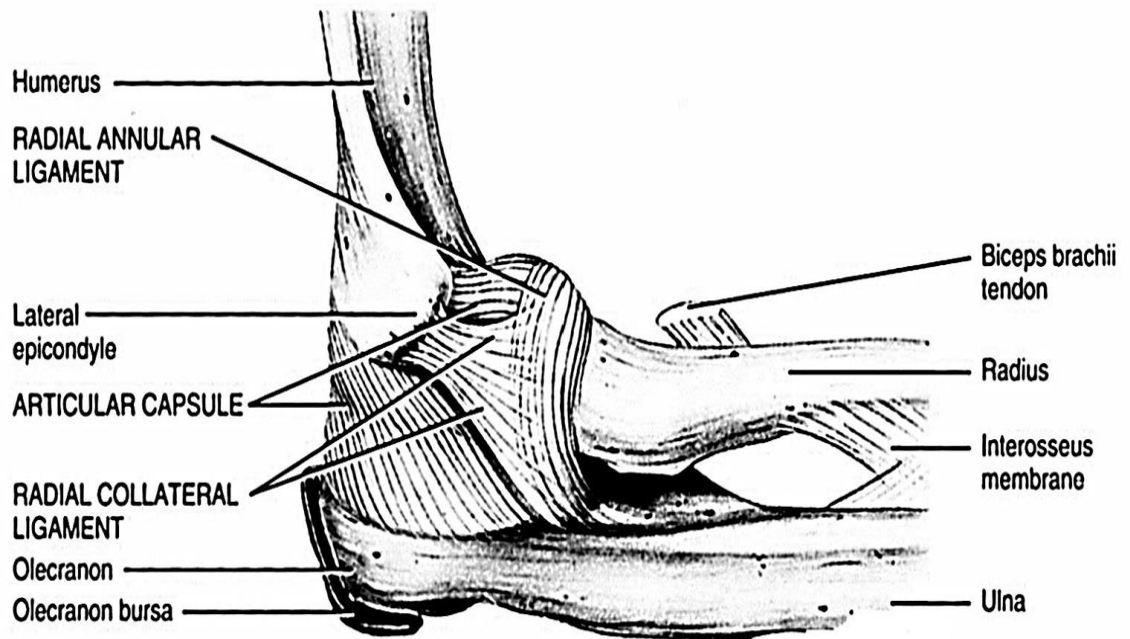


Figure 38 – The ligament of the shoulder joint

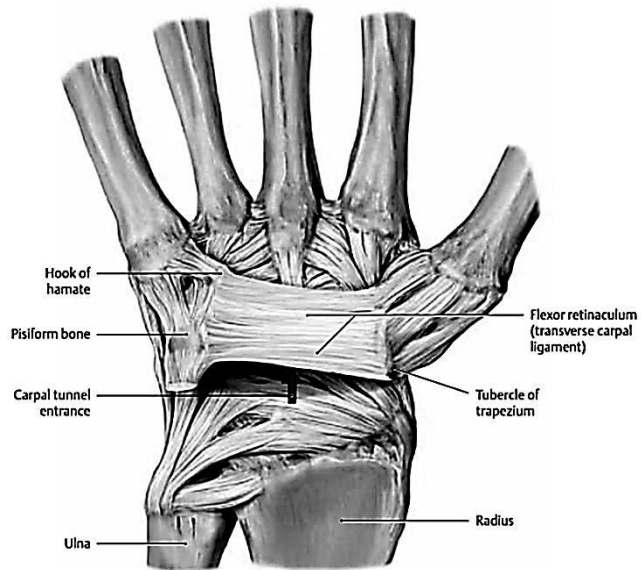


(a) Medial aspect

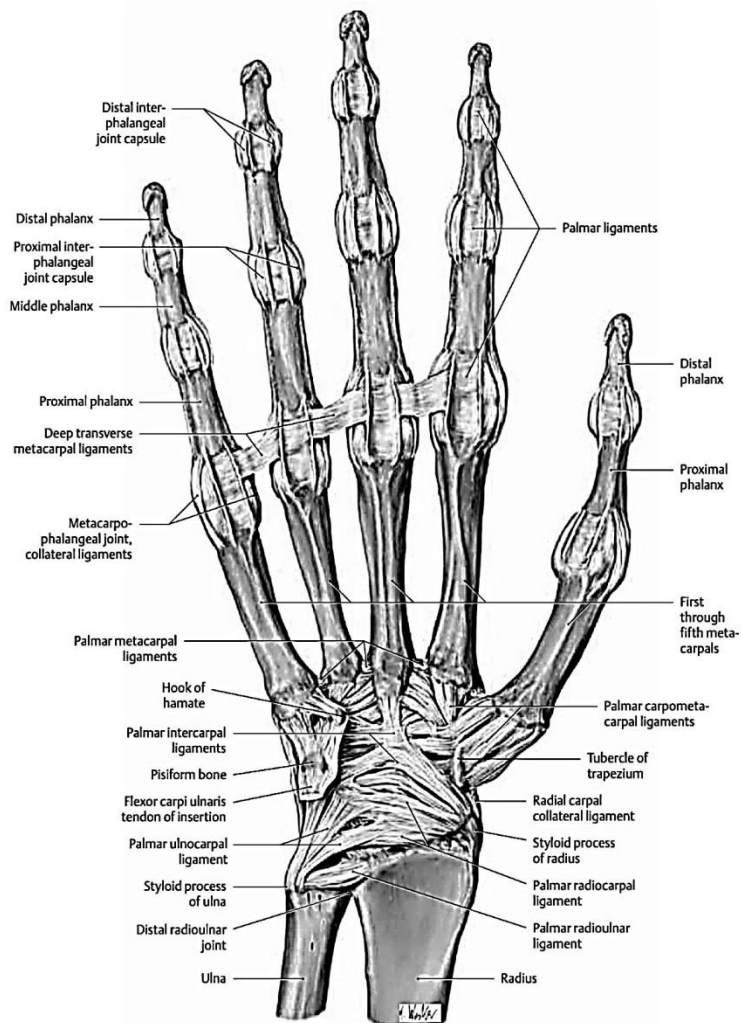


(b) Lateral aspect

**Figure 39 – The ligament of the olecranal (elbow) joint**

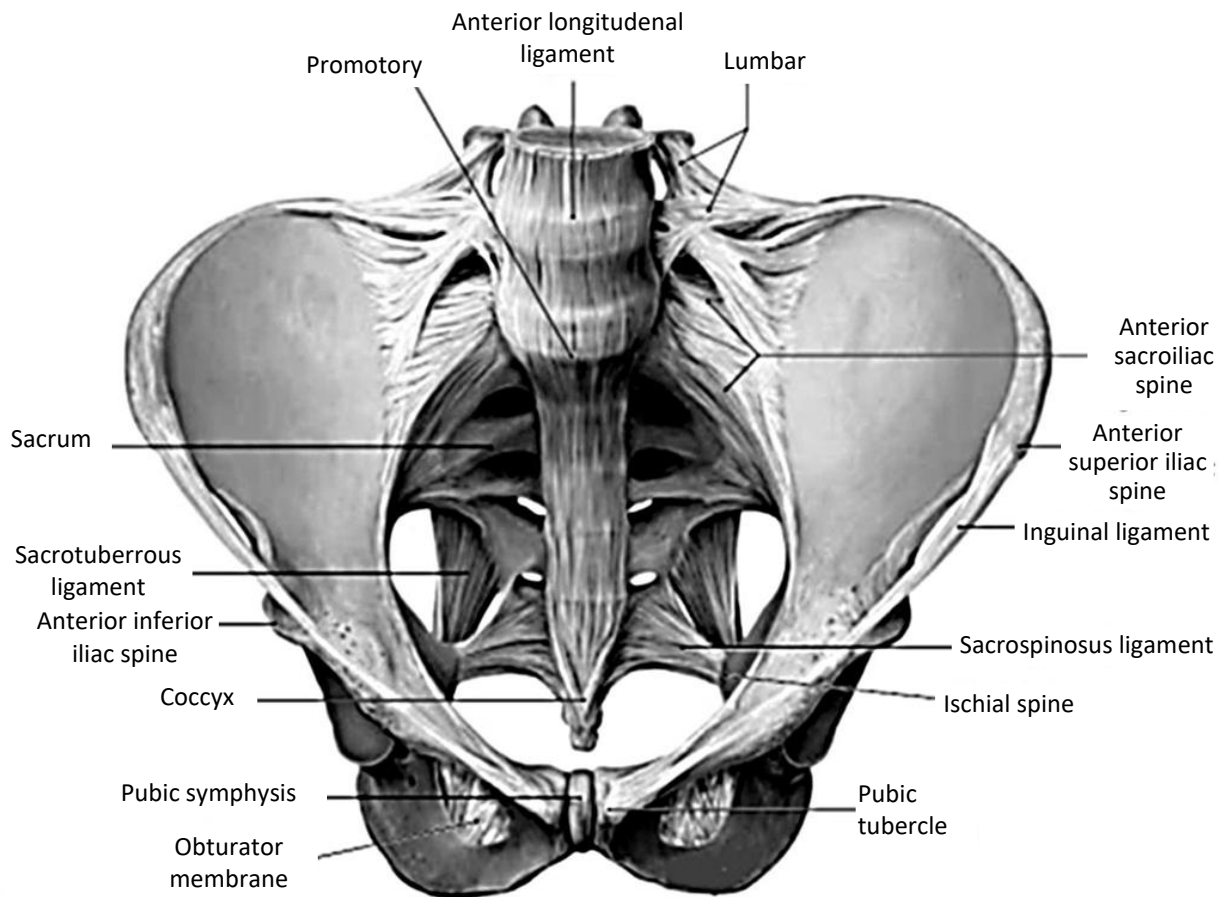


**Figure 40 – Flexor retinaculum and the carpal tunnel of the right hand**

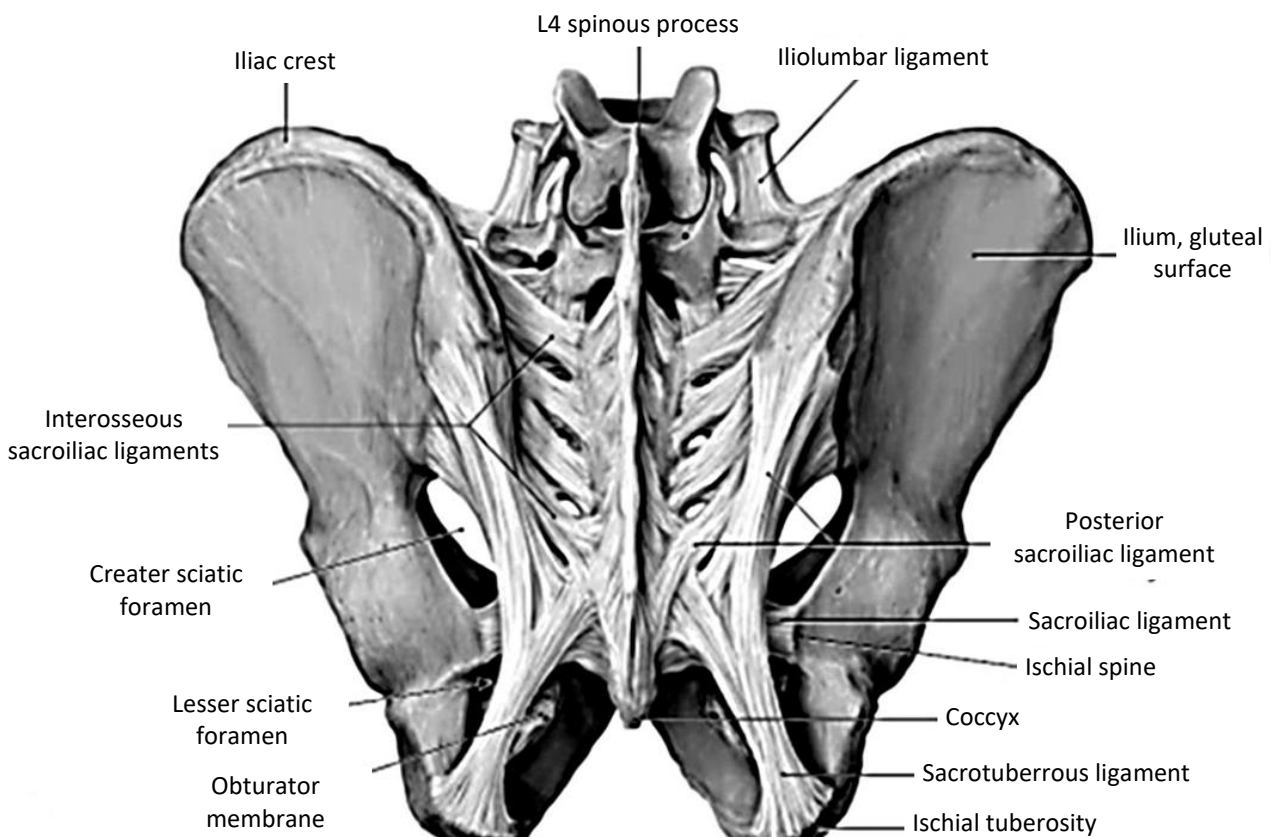


**Figure 41 –The ligament of the right hand. Anterior view**



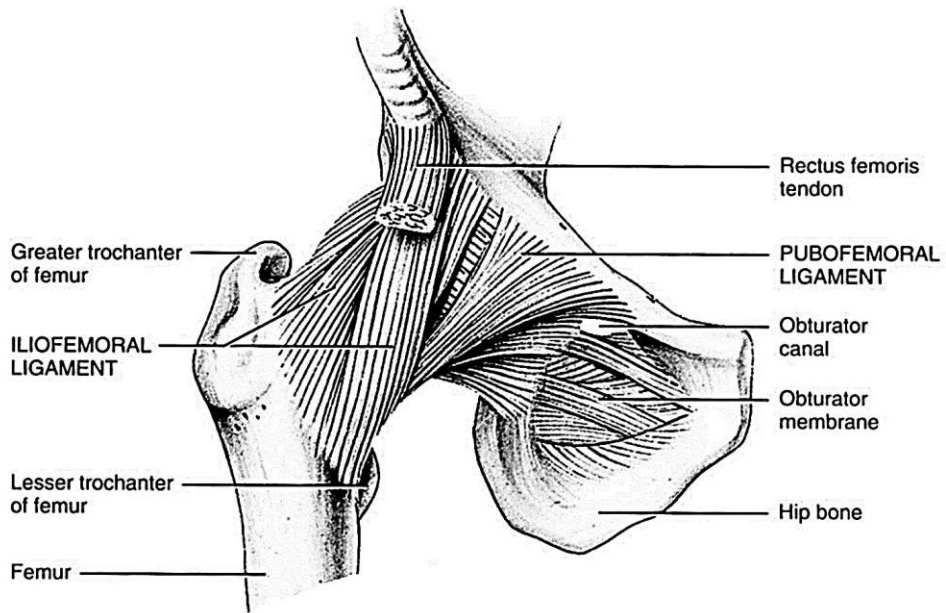


(a)

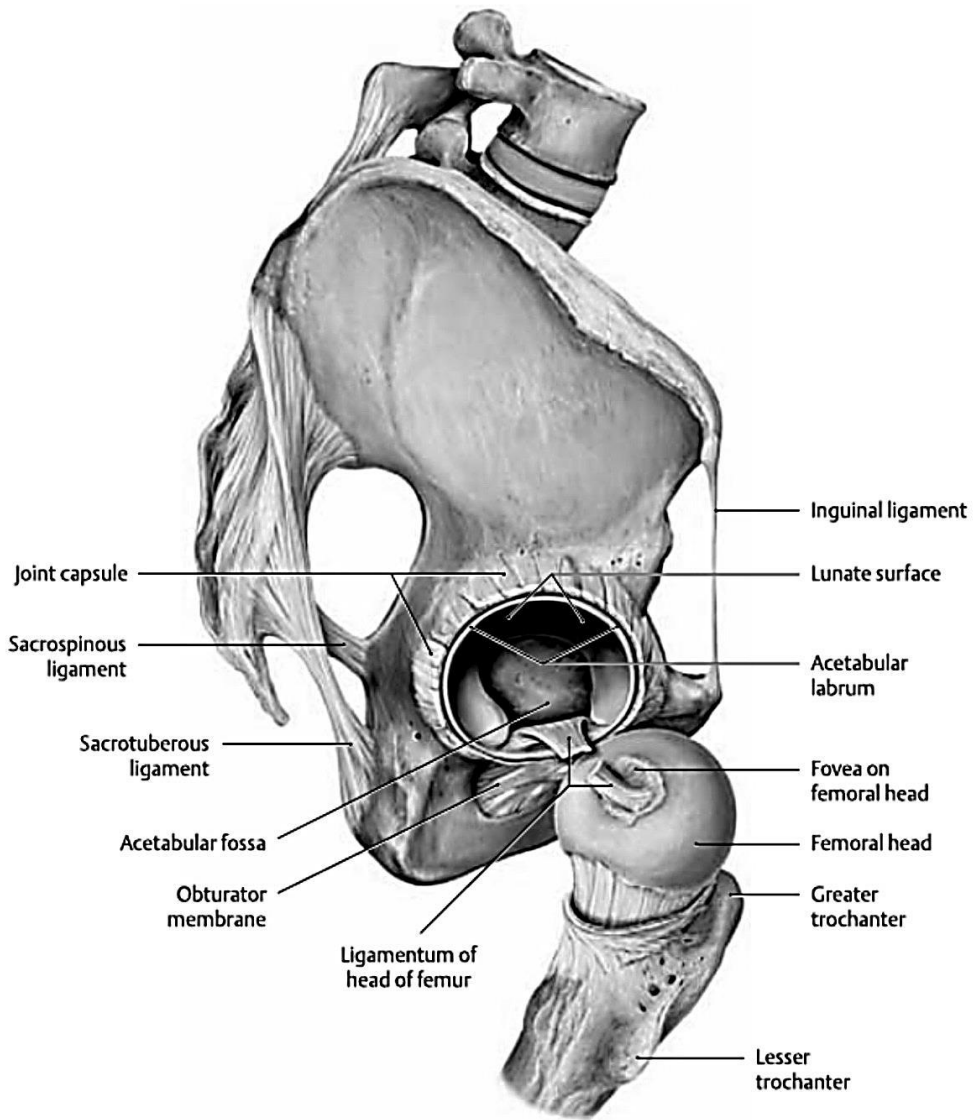


(b)

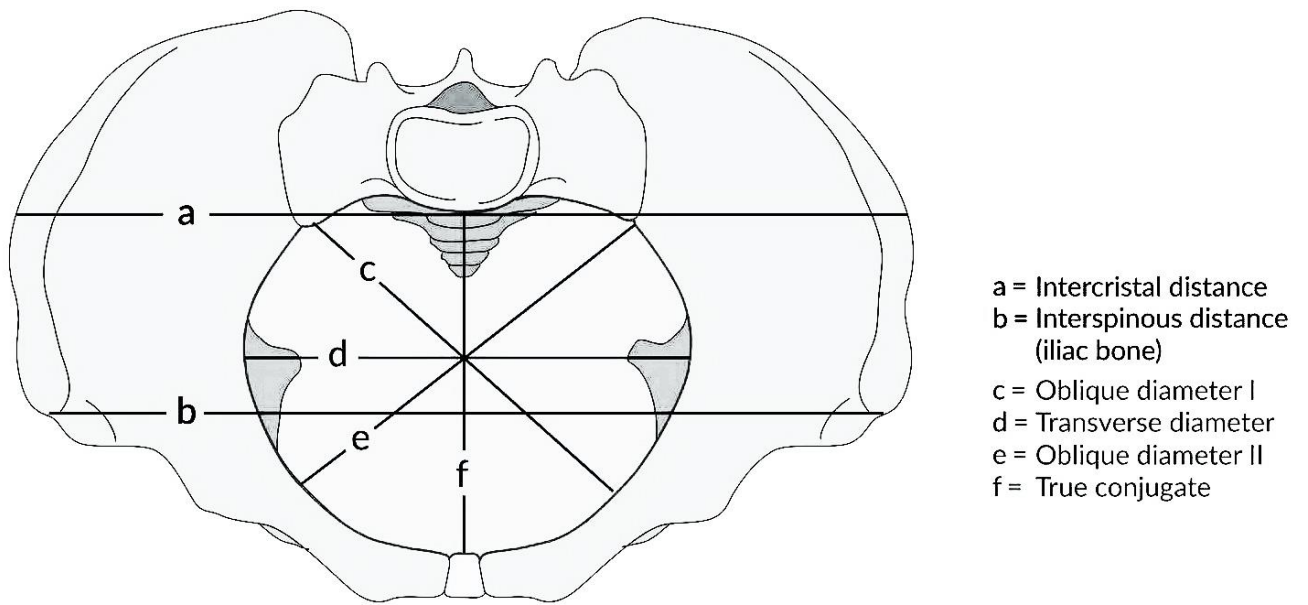
**Figure 42 – The pelvic ligaments: (a) – anterosuperior view; (b) – posterior view**



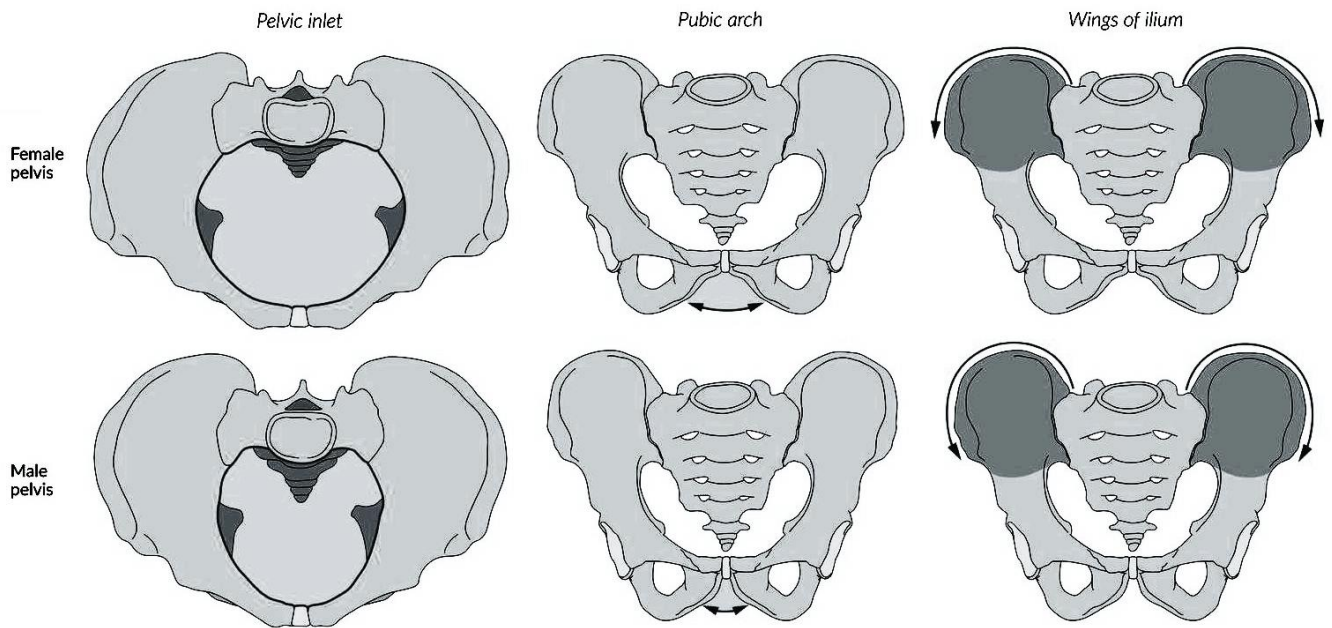
**Figure 43 – The ligament of the hip joint. Anterior view**



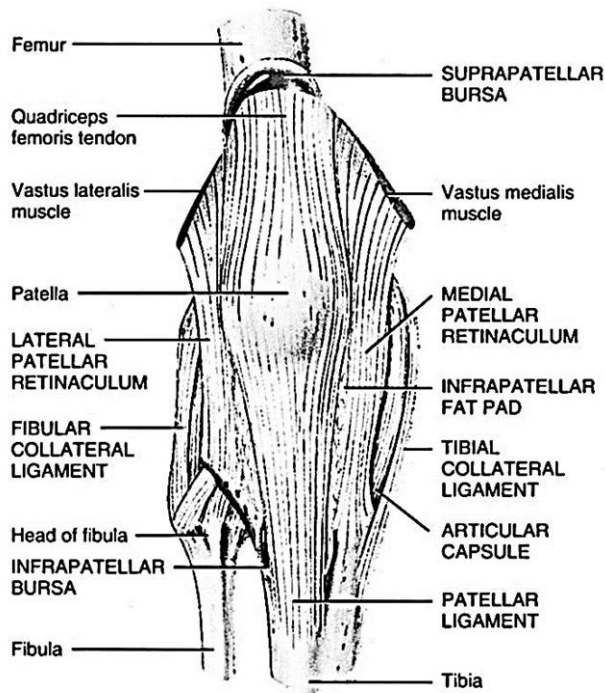
**Figure 44 – The ligament of the right hip joint. Lateral view**



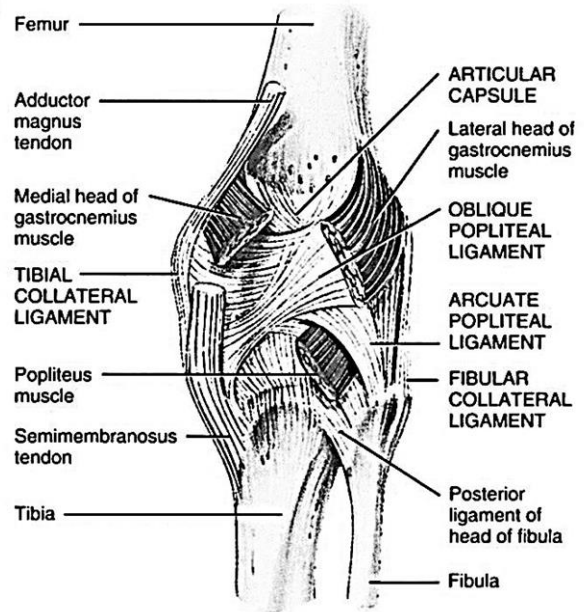
**Figure 45 – The dimension lines of the pelvis**



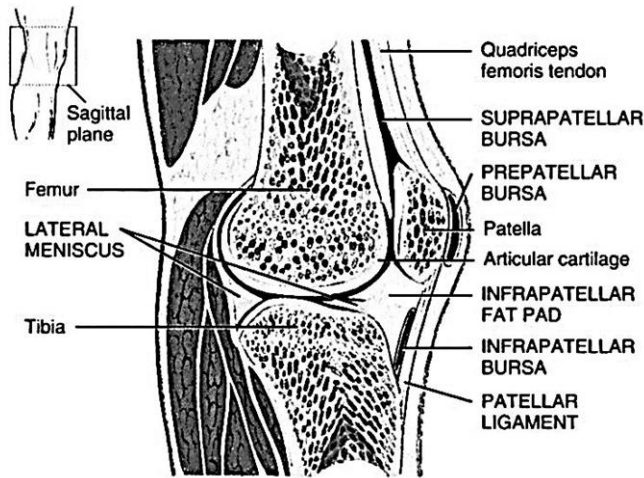
**Figure 46 – Differences between the male and female pelvis**



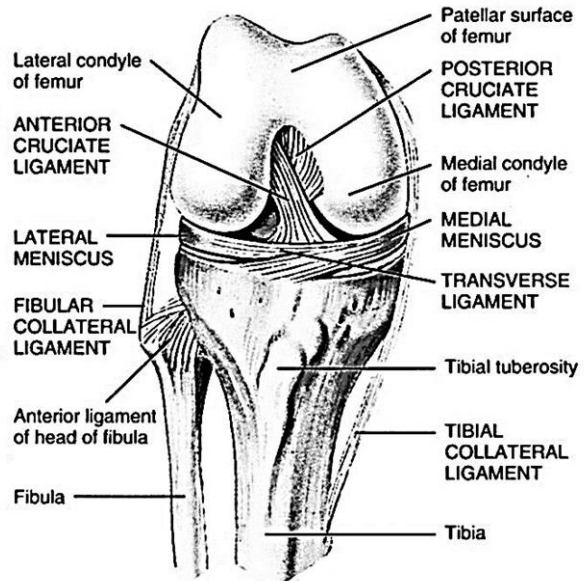
(a) Anterior



(b) Posterior deep



(c) Sagittal section



(d) Anterior deep

**Figure 47 –The ligament of the right knee joint**

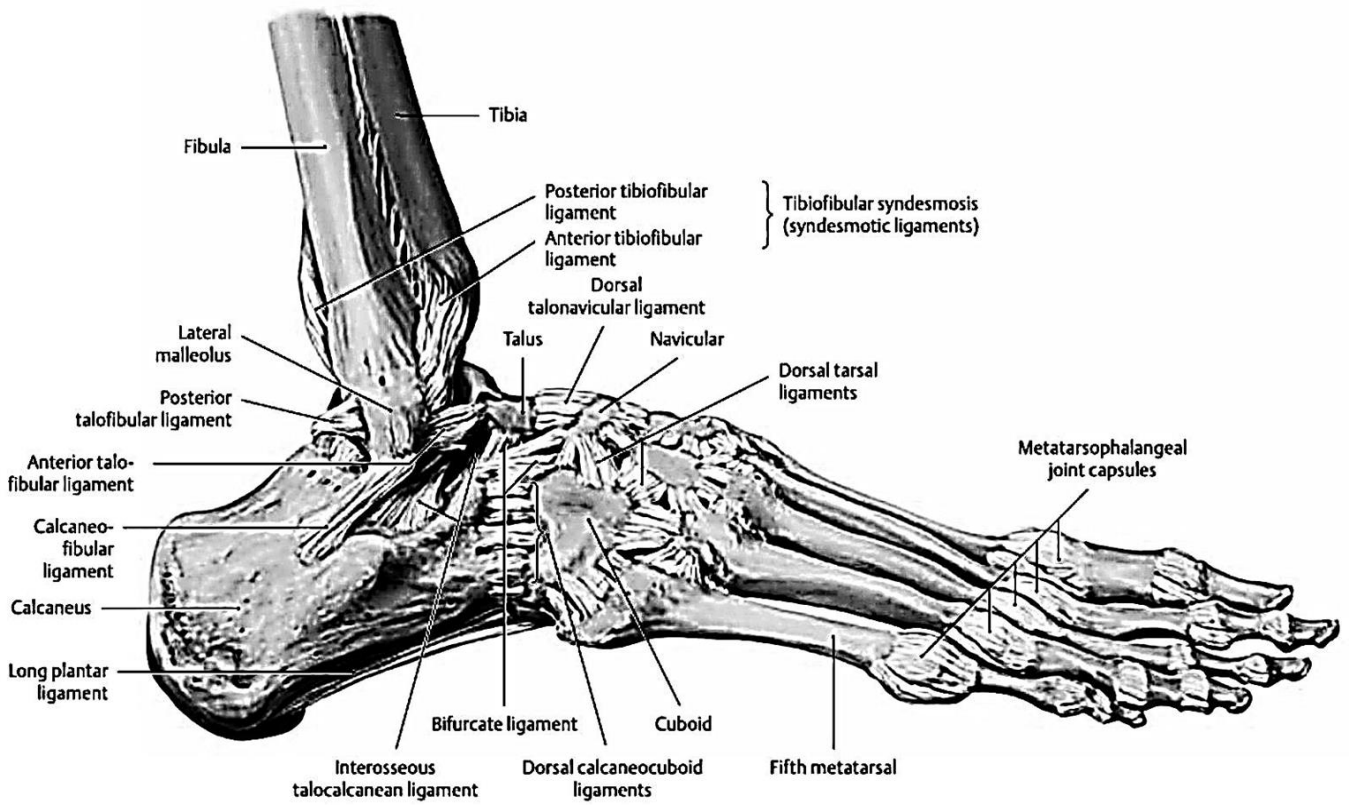


Figure 48 – The ligament of the right foot. Lateral view

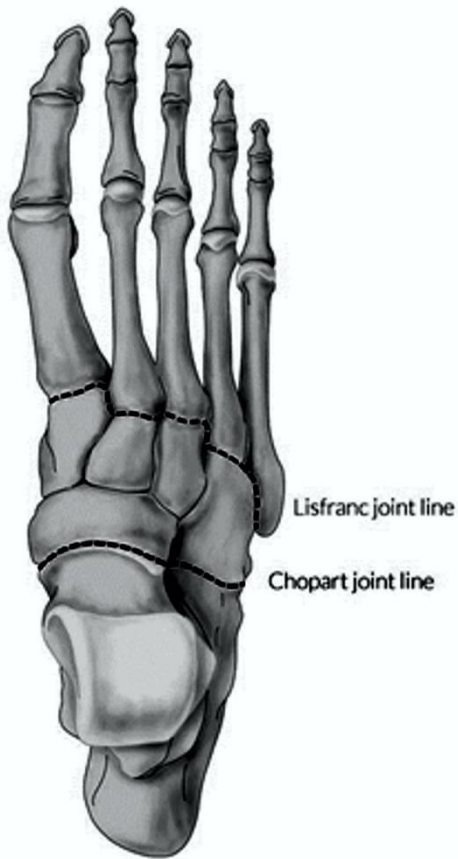


Figure 50 – Surgical Joints of the foot

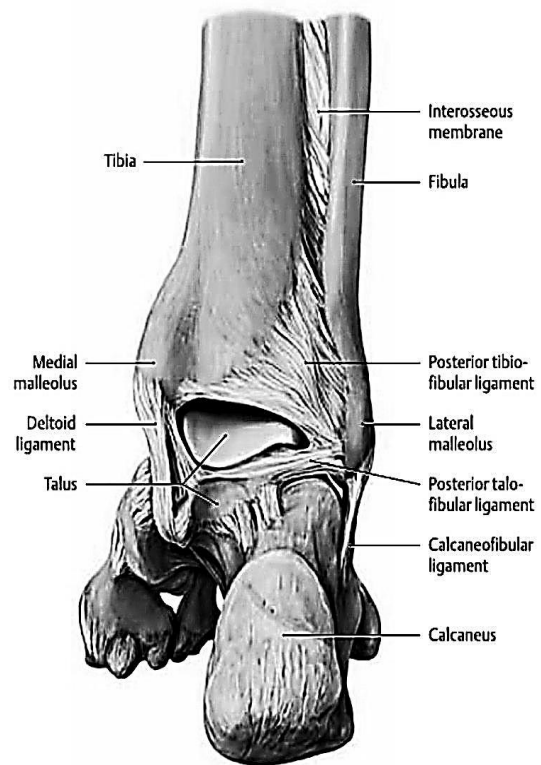


Figure 49 – The ligament of the right foot. Posterior view

## THE MUSCULAR SYSTEM

(see Figures 51 – 58)

The structure and function of the muscular system play an important role in the field of healthcare and fitness.

The term **muscular system** refers only to skeletal muscles. The study of this system is called **myology**.

### Muscle types and functions

**Skeletal muscle** may be defined as a voluntary striated muscle that is usually attached to one or more bones. Skeletal muscle cells are usually called muscle fibers or myofibers. Skeletal muscle is called voluntary because it is usually subject to conscious control.

**Cardiac muscle** is striated but involuntary – its contractions not normally, under conscious control. Its cells are not fibrous in shape and therefore, are called myocytes or cardiocytes.

**Smooth muscles** contain the same contractile proteins as skeletal and cardiac muscle, but they are not arranged in a regularly overlapping way, so, there are no striations in smooth muscle. Smooth muscles are involuntary.

## GENERAL ANATOMY OF MUSCLES

### Connective Tissues and Fascicles

A skeletal muscle is more than muscular tissue. It also contains connective tissue, nervous tissue, and blood vessels. In this section, we will examine the connective tissue components of a skeletal muscle.

They differ from the smallest to largest, and from deep to superficial.

**Endomysium** is a thin sleeve of areolar connective tissue that surrounds each muscle fiber.

**Perimysium** is a thicker connective tissue sheath that wraps muscle fibers together in bundles called **fascicles**.

**Epimysium** is a fibrous sheath that surrounds the entire muscle. The epimysium extends beyond the ends of many muscles as a fibrous band, the tendon, connecting it to the periosteum of a bone.

**Deep fascia** is a layer of fibrous connective tissue that separates neighbouring muscles from each other.

**Superficial fascia** is a layer of connective tissue that separates the muscles from the overlying skin.

### Fascicles and Muscle Shapes

The strength of a muscle and the direction of its pull are determined partly by the orientation of its fascicles. Differences in fascicle orientation are the basis for classifying muscles into five types:

1. **Fusiform muscles** are thick in the middle and tapered at each end. Their contractions are moderately strong. The **biceps brachii** of the arm and **gastrocnemius** of the calf are examples of this type.

2. **Parallel muscles** are long, straplike muscles of uniform width and parallel fascicles. Examples are the **rectus abdominis** of the abdomen, **sartorius** of the thigh, and **zygomaticus major** of the face.

3. **Convergent muscles** are fan-shaped – broad at the origin and converging toward a narrower insertion. These muscles are relatively strong because all of their fascicles exert their tension on a relatively small insertion. The **pectoralis major** in the chest is a muscle of this type.

4. **Pennate muscles** are feather-shaped. Their fascicles insert obliquely on a tendon that runs the length of the muscle, like the shaft of a feather. There are three types of pennate muscles: **unipennate**, in which all fascicles approach the tendon from one side (for example, the **palmar interosseous muscles** of the hand and **semimembranosus** of the thigh); **bipennate**, in which fascicles approach the tendon from both sides (for example, the **rectus femoris** of the thigh); and **multipennate**, shaped like a bunch of feathers with their quills converging on a single point (for example, the **deltoid** of the shoulder).

5. **Circular muscles (sphincters)** form rings around body openings. These include the **orbicularis oris** of the lips and **orbicularis oculi** of the eyelids.

### Muscle Attachments

Most skeletal muscles are attached to different bones at each end, so either the muscle or its tendon spans at least one joint. When the muscle contracts, it moves one bone relative to another. The muscle attachment at the relatively stationary

end is called its origin or head. Its attachment at the more mobile end is called its insertion.

The middle region between the origin and insertion is called the belly. There are two ways a muscle can attach to a bone.

### Functional Groups of Muscles

The movement, produced by a muscle, is called its action. Skeletal muscles seldom act independently; instead, they function in groups, whose combined actions produce the coordinated motion of a joint. Muscles can be classified into at least four categories according to their actions, but it must be stressed that a particular muscle can act in a certain way during one joint action and in a different way during other actions of the same joint. The following examples are illustrated in Figures 46 – 47:

1. **The prime mover (agonist)** is the muscle that produces most of the force during a particular joint action. In flexing the elbow, for example, the prime mover is the biceps brachii.

2. **A synergist** is a muscle that aids the prime mover. Several synergists acting on a joint can produce more power than a single larger muscle. The **brachialis**, for example, lies deep to the biceps brachii and works with it as a synergist to flex the elbow. The actions of a prime mover and its synergist are not necessarily identical and redundant. If the prime mover worked alone at a joint, it might cause rotation or other undesirable movements of a bone. A synergist may stabilize a joint and restrict these movements, or modify the direction of a movement, so that the action of the prime mover is more coordinated and specific.

3. **An antagonist** is a muscle that opposes the prime mover. In some cases, it relaxes to give the prime mover almost complete control over an action. More often, however, the antagonist maintains some tension on a joint and thus limits

the speed or range of the agonist, preventing excessive movement and joint injury. The biceps and triceps brachii represent an antagonistic pair of muscles that act on opposite sides of a joint.

### Muscles, Bones, and Levers

Many bones, especially the long bones, act as levers on which the muscles exert their force. A lever is any elongated, rigid object that rotates around a fixed point called the fulcrum. Familiar examples are a seesaw and a crowbar. Rotation occurs when an effort applied to one point on the lever overcomes a resistance (load) located at some other point. The part of a lever from the fulcrum to the point of effort is called the effort arm, and the part from the fulcrum to the point of resistance is the resistance arm. In the body, a long bone acts as a lever, a joint serves as the fulcrum, and the effort is generated by a muscle attached to the bone.

There are three classes of levers that differ with respect to which component – the fulcrum, effort, or resistance – is in the middle. A first-class lever is one with the fulcrum in the middle, such as a seesaw. An anatomical example is the atlanto-occipital joint of the neck.

A second-class lever is one in which the resistance is in the middle. Lifting the handles of a wheelbarrow, for example, makes it pivot on its wheel at the opposite end and liftload in the middle.

In a third-class lever, the effort is applied between the fulcrum and resistance. Most levers in the human body are third-class levers. At the elbow, the fulcrum is the joint between the ulna and humerus; the effort is applied by the biceps brachii muscle, and the resistance can be provided by any weight in the hand or the weight of the forearm itself.

## MUSCLES OF THE BACK

№	Muscle	Origin	Insertion	Action
<b>THE SUPERFICIAL MUSCLES OF THE BACK</b>				
<b>The First Layer</b>				
1	Trapezius	Superior nuchal line of the occipital bone, ligamentum nuchae, and spines of seventh cervical and all thoracic vertebrae	Clavicle, acromion and spine of scapula	Superior fibers elevate scapula and can help to extend the head; middle fibers adduct scapula; inferior fibers depress scapula; superior and inferior fibers, together, rotate scapula upward; stabilizes scapula
2	Latissimus dorsi	Spines of the inferior six thoracic vertebrae, lumbar vertebrae, crests of sacrum and ilium, inferior four ribs	Intertubercular sulcus of humerus	Extends, adducts, and medially rotates arm at the shoulder joint; draws arm inferiorly and posteriorly
<b>The Second Layer</b>				
3	Levator scapulae	Transverse processes of superior four cervical vertebrae	Superior angle of scapula	Elevates scapula
4	Rhomboid major	Spinous processes of the second to fifth thoracic vertebrae	Medial border of scapula inferior to spine	Elevates and adducts scapula; stabilizes scapula
5	Rhomboid minor	Spinous processes of the seventh cervical and the first thoracic vertebrae	Medial border of scapula superior to spine	Elevates and adducts scapula
<b>The Third Layer</b>				
6	Serratus posterior superior	Spinous processes of the lower two cervical and upper two thoracic vertebrae	Four slips attach to the II– V ribs	Elevates the ribs
7	Serratus posterior inferior	Spinous processes of the lower two thoracic and upper two lumbar vertebrae	Four slips are attached to the lower four ribs	Pulls the ribs downward



No	Muscle	Origin	Insertion	Action
<b>DEEP MUSCLES OF THE BACK</b>				
<b>The First Layer of Deep Muscles of the Back</b>				
1	Splenius capitis	Ligamentum nuchae and spinous processes of seventh cervical vertebra and the first three or four thoracic vertebrae	Occipital bone and mastoid process of the temporal bone	Acting together, extends the head; acting singly, laterally flexes and rotates the head to the same side as the contracting muscle
2	Splenius cervicis	Spinous processes of the third through sixth thoracic vertebrae	Transverse processes of the first two or four cervical vertebrae	Acting together, extends the head; acting singly, laterally flexes and rotates the head to the same side as the contracting muscle
3	Erector spinae: • iliocostalis (cervicis, thoracis, lumborum) • longissimus (capitis, cervicis, thoracis) • spinalis (capitis, cervicis, thoracis)	Dorsal surface of sacrum, external lip of iliac crest, spinous processes of lumbar and lower thoracic vertebrae and thoracolumbar fascia	Angles of ribs and transverse processes of C4– C7 vertebrae, mastoid process of temporal bone; transverse processes of cervical, thoracic and lumbar vertebrae and angles of ribs (2 – 12); spinous processes of thoracic and cervical vertebrae	Holds the trunk in a vertical (erect) position; extends the vertebral column
<b>The Second Layer of Deep Muscles of the Back</b>				
1	Transversospinalis: • semispinalis (capitis, cervicis, thoracis); • multifidus; • rotatores	Transverse processes of vertebrae. Transverse processes of five or six thoracic vertebrae	Spinous processes of thoracic and cervical vertebrae	Extension, rotation and bending of the vertebral column
<b>The Third Layer of Deep Muscles of the Back</b>				
1	Interspinalis	Spinous processes of vertebrae	Spinous processes of above-lying vertebrae	Acting together, extend vertebral column; acting singly, stabilize vertebral column during movements
2	Intertransversarii	Transverse processes of vertebrae	Transverse process of above-lying vertebrae	Acting together, extend vertebral column; acting singly, laterally flex vertebral column and stabilize it during movements

## MUSCLES OF THE CHEST

№	Muscle	Origin	Insertion	Action
<b>Superficial muscles of the chest</b>				
1	Pectoralis major	Clavicle, sternum, and costal cartilages of the second to sixth ribs	Crest of greater tubercle of humerus	As a whole, adducts and medially rotates the arm at shoulder joint; clavicular head acting alone flexes arm, and sternocostal head alone extends arm at shoulder joint
2	Pectoralis minor	Anterior surface of ribs 3 through 5	Coracoid process of scapula	Abducts scapula and rotates it downward; elevates third through fifth ribs during forced inhalation when scapula is fixed
3	Subclavius	Cartilage of the first rib	Acromial end of clavicle	Depresses and moves clavicle anteriorly and helps to stabilize the pectoral girdle
4	Serratus anterior	Superior nine ribs	Medial border and inferior angle of scapula	Abducts scapula and rotates it upward; elevates ribs when scapula is stabilized; known as "boxer's muscle"
<b>Deep muscles of the chest</b>				
1	Diaphragm: • the sternal part; • the costal part; • the lumbar part	Xiphoid process of the sternum, costal cartilages of inferior six ribs, and lumbar vertebrae	Central tendon	Contraction of the diaphragm causes it to flatten and increase the vertical dimension of the thoracic cavity, resulting in inhalation; relaxation of the diaphragm causes it to move superiorly and decreases the vertical dimension of the thoracic cavity, resulting exhalation
2	External intercostal	Inferior border of the rib above	Superior border of the rib below	Contraction elevates the ribs and increases the anteroposterior and lateral dimensions of the thoracic cavity, resulting in inhalation; relaxation depresses the ribs and decreases the anteroposterior lateral dimensions of the thoracic cavity, resulting in exhalation
3	Internal intercostal	Superior border of the rib below	Inferior border of the rib above	Contraction draws adjacent ribs together to further decrease of the anteroposterior and lateral dimensions of the thoracic cavity during forced exhalation

4	Subcostales	On the internal surface of the lower (10 – 12) ribs in the area of their angles	Inner surface of above-lying ribs	The direction of their fibers is the same as that of the internal intercostal muscles. However, the subcostales cross over from one to two ribs. The subcostales depress the ribs
5	Transversus thoracis	Xiphoid process and border of the inferior part of sternum	Ribs 2 – 6	Depresses the ribs
6	Levatores costarum	Transverse process of C7 and T1 – T11 vertebrae	Angles of closest ribs	These muscles have no part in elevating ribs. Mostly, the levatores costarum reinforce the ribs

### MUSCLES OF THE ABDOMEN

No	Muscle	Origin	Insertion	Action
<b>Anterior Muscles of the Abdomen</b>				
1	Rectus abdominis	Pubic crest and pubic symphysis	Cartilage of fifth to seventh ribs and xiphoid process	Flexes vertebral column, especially lumbar portion, and compresses abdomen to help in defecation, urination, forced exhalation, and childbirth
2	Pyramidalis	Superior pubic ramus	Linea alba	Tensor of the linea alba
<b>Lateral Muscles of the Abdomen</b>				
3	External oblique	Inferior eight ribs	Iliac crest and linea alba	Acting together (bilaterally), compress abdomen and flex vertebral column; acting singly (unilaterally), laterally flex vertebral column to the side opposite contracting muscle, especially lumbar portion, and rotate vertebral column
4	Internal oblique	Iliac crest, inguinal ligament, and thoracolumbar fascia	Cartilage of the last three or four ribs and linea alba	Acting together (bilaterally), compress abdomen and flex vertebral column; acting singly (unilaterally), laterally flex vertebral column to the same side of the contracting muscle, especially lumbar portion, and rotate vertebral column
5	Transversus abdominis	Iliac crest, inguinal ligament, thoracolumbar fascia, and cartilages of inferior six ribs	Xiphoid process, linea alba, and pubis	Compresses abdomen
<b>Posterior Muscles of the Abdomen</b>				
6	Quadratus lumborum	Iliac crest and iliolumbar ligament	Inferior border of the twelfth rib and transverse processes of the first four lumbar vertebrae	Acting together, extend lumbar portion of vertebral column; acting singly, laterally flex vertebral column, especially lumbar portion

## MUSCLES OF THE NECK (NECK MUSCLES)

№	Muscle	Origin	Insertion	Action
<b>The Superficial Muscles of the Neck</b>				
1	Platysma	Fascia over deltoid and pectoralis major muscles	Mandible, muscles around the angle of the mouth and skin of the lower face	Draws outer part of lower lip inferiorly and posteriorly as in pouting; depresses mandible
2	Sternocleidomastoid	Sternum and clavicle	Mastoid process of temporal bone	Acting together (bilaterally), flex cervical portion of vertebral column, extend head, and elevate sternum during forced inhalation; acting singly (unilaterally), laterally flex and rotate head to side opposite contracting muscle
<b>Muscles Located Above Hyoid Bone (Suprahyoid Muscles)</b>				
1	Digastric	Anterior belly arises from the digastric fossa of mandible; posterior belly – from mastoid process	Body of hyoid bone via an intermediate tendon	Elevates hyoid bone and depresses mandible, as in opening the mouth
2	Stylohyoid	Styloid process of temporal bone	Body of hyoid bone	Elevates hyoid bone and draws it posteriorly
3	Mylohyoid	Mylohyoid line of mandible	Body of hyoid bone	Elevates hyoid bone and floor of the mouth and depresses mandible
4	Geniohyoid	Mental spine of mandible	Body of hyoid bone	Elevates hyoid bone, draws hyoid bone and tongue anteriorly, depresses mandible
<b>Muscles Located Below Hyoid Bone (Infrahyoid Muscles)</b>				
1	Omohyoid	Superior border of scapula and superior transverse ligament	Body of hyoid bone	Depresses hyoid bone
2	Sternohyoid	Medial end of clavicle and manubrium of sternum	Body of hyoid bone	Depresses hyoid bone
3	Sternothyroid	Manubrium of sternum	Thyroid cartilage of larynx	Depresses thyroid cartilage of larynx
4	Thyrohyoid	Thyroid cartilage of larynx	Greater horn of hyoid bone	Elevates thyroid cartilage and depresses hyoid bone

No	Muscle	Origin	Insertion	Action
<b>DEEP MUSCLES OF THE NECK</b>				
<b>Deep Lateral Muscles of the Neck</b>				
1	Anterior scalene	Transverse processes of the third through sixth cervical vertebrae	First rib	Acting together, flex head and elevate the first or second ribs during deep inhalation; acting singly, laterally flex and rotate head to the side opposite contracting muscle
2	Middle scalene	Transverse processes of inferior six cervical vertebrae	First rib	
3	Posterior scalene	Transverse processes the of fourth through sixth cervical vertebrae	Second rib	
<b>Deep Prevertebral muscles of the neck</b>				
1	Longus colli	Anterior surface of bodies and transverse processes of C3– C7 and T1– T3 vertebrae	Bodies and transverse processes of C1– C5 and anterior tubercle of atlas	Acting together flex the cervical spine; acting singly, flex the cervical spine to the side same of contracting muscle
2	Longus capitis	Transverse processes of C3– C6	Basilar part of occipital bone	Bends the head forward
3	Rectus capitis anterior	Lateral mass of atlas	Basilar part of occipital bone	Bends the head forward
4	Rectus capitis lateralis	Transverse processes of atlas	Jugular process of occipital bone	Bends the head side to side
<b>Suboccipital Muscles</b>				
1	Obliquus capitis superior	Transverse processes of atlas	Occipital bone, above the inferior nuchal line	Draws the head backward and to its own side
2	Obliquus capitis inferior	Spinous process of axis	Transverse processes of atlas	Rotates atlas, turning the fare to the same sid
3	Rectus capitis posterior major	Spinous process of axis	Occipital bone, below the inferior nuchal line	Extension, lateral flexion and rotation
4	Rectus capitis posterior minor	Posterior tubercle of atlas	Occipital bone, below the inferior nuchal line	Extension and lateral flexion of the head

## MUSCLES OF THE HEAD

№	Muscle	Origin	Insertion	Action
<b>I. Epicranial muscles</b>				
1	Occipitofrontalis: • frontal belly; • occipital belly	Epicranial aponeurosis. Occipital bone and mastoid process of temporal bone	Skin superior to supraorbital margin. Epicranial aponeurosis	Draws scalp anteriorly, raises eyebrows, and wrinkles the skin of the forehead horizontally. Tenses and retracts scalp
2	Procerus	Nasal bones and lateral nasal cartilage	Aponeurosis at the bridge of the nose and skin of the forehead	Moves nose, forms transverse folds between eyebrows
<b>II. Auriculares muscles</b>				
1	Mm.auriculares: • anterior auricular; • posterior auricular; • superior auricular	Epicranial aponeurosis Epicranial aponeurosis Mastoid process	Skin of auricular concha	Pulls auricular concha: • forward; • upward; • backward
<b>III. Muscles of the Mouth</b>				
1	Orbicularis oris	Maxillary bone and mandible	Skin of superior and inferior lips	Closes and protrudes lips, compresses lips against teeth, and shapes lips during speech
2	Zygomaticus major	Zygomatic bone	Skin at angle of mouth	Draws angle of mouth superiorly and laterally as in smiling or laughing
3	Zygomaticus minor	Zygomatic bone	Upper lip	Raises (elevates) upper lip, exposing maxillary teeth
4	Levator labii superioris	Superior to infraorbital foramen of maxilla	Skin at angle of mouth and orbicularis oris	Raises upper lip
5	Depressor labii inferioris	Mandible	Skin of lower lip	Depresses (lowers) lower lip
6	Depressor anguli oris	Mandible	Skin at angle of mouth	Draws angle of mouth laterally and inferiorly as in opening mouth
7	Buccinator	Alveolar processes of maxilla and mandible	Orbicularis oris	Presses cheeks against teeth and lips as in whistling, blowing, and sucking; draws corner of mouth laterally; assists in mastication (chewing) by keeping food between the teeth (not between teeth and cheeks)

No	Muscle	Origin	Insertion	Action
8	Risorius	Fascia over parotid (salivary) gland	Skin at angle of mouth	Draws angle of mouth laterally, as in tenseness
9	Mentalis	Mandible	Skin of chin	Elevates and protrudes lower lip and pulls skin of chin up as in pouting
<b>VI. Orbit and Eyebrow Muscles</b>				
1	Orbicularis oculi • orbital part • palpebral part • lacrimal part	Medial margin of orbit	Skin around eyelids	<ul style="list-style-type: none"> <li>• closes eyelids</li> <li>• tight closure of the lids</li> <li>• dilates the lacrimal sac</li> </ul>
2	Corrugator supercilii	Medial end of superciliary arch of frontal bone	Skin of eyebrow	Draws eyebrow interiorly and wrinkles skin of forehead vertically as in frowning
<b>V. Nose muscle</b>				
1	Nasalis • the transverse part • the alar part	Maxilla	<ul style="list-style-type: none"> <li>• dorsum of the nose</li> <li>• ala nasi</li> </ul>	<ul style="list-style-type: none"> <li>• narrows nostrils</li> <li>• widens nostrils</li> </ul>
<b>VI. Masticatory muscles</b>				
1	Masseter	Maxilla and zygomatic arch	Masseteric tuberosity of mandible	Elevates mandible as in closing mouth and protracts (draws forward) mandible
2	Temporalis	Temporal fossa	Coronoid process and ramus of mandible	Elevates and retracts mandible
3	Medial pterygoid	Pterygoid fossa of pterygoid process	Pterygoid tuberosity of mandible	Elevates and protracts (protrudes) mandible
4	Lateral pterygoid	Greater wing and lateral surface of lateral plate of pterygoid process of sphenoid bone	Condyle of mandible; temporomandibular joint	Protracts mandible, depresses mandible as in opening mouth; unilateral contraction pulls mandible to opposite side

## MUSCLES OF THE UPPER LIMB

№	Muscle	Origin	Insertion	Action
<b>MUSCLES OF THE SHOULDER GIRDLE</b>				
1	Deltoid	Acromial extremity of clavicle, acromion of scapula, and spine of scapula	Deltoid tuberosity of humerus	Whole muscle: abducts arm at shoulder joint; anterior part: flexion and medial rotation; posterior part: extension and lateral rotation
2	Supraspinatus	Supraspinous fossa of scapula	Greater tubercle of humerus	Abduction at shoulder joint
3	Infraspinatus	Infraspinous fossa of scapula	Greater tubercle of humerus	Lateral rotation at shoulder joint
4	Teres major	Inferior angle and lateral border of scapula	Crest of the lesser tubercle of humerus	Extension, adduction and medial rotation at shoulder joint
5	Teres minor	Lateral border of scapula	Greater tubercle of humerus	Lateral rotation at shoulder joint
6	Subscapularis	Subscapular fossa	Lesser tubercle of humerus	Medial rotation and adduction of the arm
<b>MUSCLES OF THE UPPER ARM</b>				
<b>Anterior Muscles of the Upper Arm ( Flexors)</b>				
1	Biceps brachii	Long head from supraglenoid tubercle above glenoid cavity of scapula; short head from coracoid process of scapula	Tuberosity of radius	Flexes the arm and forearm, supinates forearm
2	Brachialis	Anterior surface of humerus below deltoid tuberosity	Tuberosity of ulna	Flexes at elbow
3	Coracobrachialis	Coracoid process of scapula	Medial margin of the shaft of humerus	Flexion and adduction at shoulder joint
<b>Posterior Muscle of the Upper Arm ( Extensors)</b>				
1	Triceps brachii	Long head: infraglenoid tubercle of scapula. Lateral head: posterior surface of humerus superior to radial groove. Medial head: posterior surface of humerus inferior to radial groove	Olecranon	Extension at elbow, extension and adduction at shoulder.
2	Anconeus	Lateral epicondyle of humerus	Olecranon	Extension at elbow



No	Muscle	Origin	Insertion	Action
<b>MUSCLES OF THE FOREARM</b>				
<b>ANTERIOR GROUP</b>				
<b>The First Layer</b>				
1	Pronator teres	Medial epicondyle of humerus and coronoid process of ulna	Middle part of the radius on the lateral side	Pronates forearm at radioulnar joints and flexes forearm at elbow joint
2	Flexor carpi radialis	Medial epicondyle of humerus	Second and third metacarpal bones	Flexion and abduction at wrist joint
3	Palmaris longus	Medial epicondyle of humerus	Flexor retinaculum and palmar aponeurosis	Stretches the palmar aponeurosis and flexes the hand at wrist joint
4	Flexor carpi ulnaris	Medial epicondyle of humerus	Pisiform bone, hamate bone, and base of fifth metacarpal bone	Flexion and adduction at wrist joint
<b>The Second Layer</b>				
1	Flexor digitorum superficialis	Medial epicondyle of humerus; adjacent anterior surface of ulna and radius	Middle phalanges of fingers 2 – 5	Flexion at proximal interphalangeal, metacarpophalangeal, and wrist joints
<b>The Third Layer</b>				
1	Flexor pollicis longus	Anterior surface of radius and interosseous membrane	Base of distal phalanx of thumb	Flexion of distal phalanx of thumb at interphalangeal joint
2	Flexor digitorum profundus	Anterior surface of ulna and of interosseous membrane	Base of distal phalanges of fingers 2 – 5	Flexion of distal interphalangeal joints; proximal interphalangeal joints, and wrist
<b>The Fourth Layer</b>				
1	Pronator quadratus	Anterior and medial surfaces of distal portion of ulna	Distal one-fourth of anterolateral surface of radius	Pronation of the forearm and hand
<b>POSTERIOR (EXTENSOR) COMPARTMENT OF THE FOREARM</b>				
<b>The first layer</b>				
1	Brachioradialis	Lateral border of distal end of humerus	Superior to styloid process of radius	Flexion of forearm and setting it in a middle position between supination and pronation
2	Extensor carpi radialis longus	Lateral epicondyle of humerus, posterior surface of ulna and radius	Base of second metacarpal bone	Extension and abduction at wrist

No	Muscle	Origin	Insertion	Action
3	Extensor carpi radialis brevis	Lateral epicondyle of humerus, posterior surface of ulna and radius	Base of third metacarpal bone	Extension and abduction at wrist
4	Extensor digitorum	Lateral epicondyle of humerus, posterior surface of ulna and radius	Distal and middle phalanges of fingers 2 – 5	Extension of phalanges and wrist
5	Extensor digiti minimi	Lateral epicondyle of humerus, posterior surface of ulna and radius	Proximal middle and distal phalanges of little finger	Flexion of the little finger
6	Extensor carpi ulnaris	Lateral epicondyle of humerus, posterior surface of ulna and radius	Base of the fifth metacarpal bone	Extension and adduction at wrist joint
<b>The second layer</b>				
1	Abductor pollicis longus	Proximal dorsal surface of radius and ulna	Fifth metacarpal bone	Abduction at joint of thumb and wrist
2	Extensor pollicis brevis	Posterior surface of radius and interosseous membrane	Base of proximal phalanx of thumb	Extension at joints of thumb; abduction at the wrist
3	Extensor pollicis longus	Posterior surface of the middle part of ulna and interosseous membrane	Base of distal phalanx of thumb	Extends distal phalanx of thumb at interphalangeal joint, first metacarpal of thumb at carpometacarpal joint, and abducts hand at wrist joint
4	Extensor indicis	Posterior surface of ulna	Tendon of extensor digitorum of index finger	Extends distal and middle phalanges of index finger at interphalangeal joints, proximal phalanx of index finger at metacarpophalangeal joint, and hand at wrist joint
<b>The third layer</b>				
1	Supinator	Lateral epicondyle of humerus and ridge near radial notch of ulna (supinator crest)	Lateral surface of proximal one-third of radius	Supinates forearm at radioulnar joints

No	Muscle	Origin	Insertion	Action
<b>MUSCLES OF THE HAND</b>				
<b>Thenar Muscles of the Hand</b>				
1	Abductor pollicis brevis	Flexor retinaculum, scaphoid, and trapezium	Lateral side of proximal phalanx of thumb	Abducts thumb at carpometacarpal joint
2	Opponens pollicis	Flexor retinaculum and trapezium	Lateral side of first metacarpal (thumb)	Moves thumb across palm to meet little finger (opposition) at the carpometacarpal joint
3	Flexor pollicis brevis	Flexor retinaculum, trapezium, capitate, and trapezoid	Lateral side of proximal phalanx of thumb	Flexes thumb at carpometacarpal and metacarpophalangeal joints
4	Adductor pollicis	Oblique head: capitate and second and third metacarpals; transverse head: third metacarpal	Medial side of proximal phalanx of thumb by a tendon containing a sesamoid bone	Adducts thumb at carpometacarpal and metacarpophalangeal joints
<b>Hypothenar Muscles of the Hand</b>				
1	Abductor digiti minimi	Pisiform and tendon of flexor carpi	Medial side of proximal phalanx of little finger	Abducts and flexes little finger at a metacarpophalangeal joint
2	Flexor digiti minimi	Flexor retinaculum and hook of hamate	Medial side of proximal phalanx of little finger	Flexes little finger at carpometacarpal and metacarpophalangeal joints
3	Opponens digiti minimi	Flexor retinaculum and hamate	Medial side of fifth metacarpal (little finger)	Moves little finger across palm to meet thumb (opposition) at carpometacarpal joint
4	Palmaris brevis	Transverse carpal ligament and palmar aponeurosis	Skin on the ulnar border of the palm of the hand	Tenses the skin of the palm on the near side during a grip action and deepens the hollow of the palm
<b>Intermediate (Midpalmar)</b>				
1	Lumbricals	Lateral sides of tendons and flexor digitorum profundus of each finger	Lateral sides of tendons of extensor digitorum on proximal phalanges of each finger	Flex each finger at metacarpophalangeal joints and extend each finger at interphalangeal joints
2	Palmar interossei	Sides of shafts of metacarpals of all digits (except the middle one)	Sides of bases of proximal phalanges of all digit (except the middle one)	Adduct fingers at metacarpophalangeal joints;
3	Dorsal interossei	Adjacent sides of metacarpals	Proximal phalanx of each finger	Abduct fingers

## MUSCLES OF THE LOWER LIMB

№	Muscle	Origin	Insertion	Action
<b>Muscles of the Pelvic Girdle. Anterior Group</b>				
1	Psoas major	Transverse processes and bodies of lumbar vertebrae	With iliacus into middle surface of lesser trochanter of femur	Psoas major and iliacus muscles acting together flex thigh at hip joint, rotate thigh laterally, and flex trunk on the hip as in sitting up from the supine position
2	Iliacus	Iliac fossa and sacrum	With psoas major into lesser trochanter of femur	Flex torso and thigh respect to each other
<b>Muscles of the Pelvic Girdle. Posterior Group</b>				
1	Gluteus maximus	Iliac crest, sacrum, coccyx, and aponeurosis of sacrospinalis	Iliotibial tract of fascia lata and lateral part of linea aspera under greater trochanter (gluteal tuberosity) of femur	Extends thigh at hip joint and laterally rotates thigh
2	Gluteus medius	Ilium	Greater trochanter of femur	Abducts thigh at hip joint and medially rotates thigh
3	Gluteus minimus	Ilium	Greater trochanter of femur	Abducts thigh at hip joint and medially rotates thigh
4	Tensor fasciae latae	Iliac crest	Iliotibial tract (anterior surface of lateral condyle of tibia)	Flexes and abducts thigh at hip joint
5	Piriformis	Anterior (pelvic) surface of the sacrum	Superior border of greater trochanter of femur	Laterally rotates and abducts thigh at hip joint
6	Obturator internus	Inner surface of obturator foramen, pubis, and ischium	Greater trochanter of femur	Laterally rotates and abducts thigh at hip joint
7	Obturator externus	Outer surface of obturator membrane	Trochanteric fossa of femur	Laterally rotates and abducts thigh at hip joint
8	Superior gemellus	Ischial spine	Greater trochanter of femur	Laterally rotates and abducts thigh at hip joint
9	Inferior gemellus	Ischial tuberosity	Greater trochanter of femur	Laterally rotates and abducts thigh at hip joint

No	Muscle	Origin	Insertion	Action
<b>MUSCLES OF THE THIGH</b>				
<b>Medial (Adductor) Compartment of the Thigh</b>				
1 2 3 4 5	Adductor magnus Adductor longus Adductor brevis Pectineus Gracilis	Body and inferior ramus of pubis	Medial surface of body of tibia	Adducts thigh at hip joint, medially rotates thigh, and flexes leg at knee joint
<b>Anterior (Extensor) Compartment of the Thigh</b>				
1	Quadriceps femoris: • rectus femoris; • vastus lateralis; • vastus medialis; • vastus intermedius	Anterior inferior iliac spine; greater trochanter and intertrochanteric line; linea aspera of femur; anterior and lateral surfaces of femur	Patella via quadriceps tendon and then tibial tuberosity via patellar ligament	All four heads extend the leg at knee joint; rectus femoris muscle also flexes the thigh at hip joint
2	Sartorius	Anterior superior iliac (Latin sartor = tailor; the longest muscle in the body)	Medial surface of the body of tibia	Flexes leg at knee joint; flexes, abducts, and laterally rotates at hip joint
<b>Posterior (flexor) compartment of the thigh</b>				
1	Biceps femoris	Long head arises from ischial tuberosity; short head arises from linea aspera of femur	Head of fibula and lateral condyle of tibia	Flexes leg at knee joint and extends thigh at hip joint
2	Semitendinosus	Ischial tuberosity	Proximal part of medial surface of shaft of tibia	Flexes leg at knee joint and extends thigh at hip joint
3	Semimembranosus	Ischial tuberosity	Medial condyle of tibia	Flexes leg at knee joint and extends thigh at hip joint
<b>MUSCLES OF THE LEG</b>				
<b>Anterior Compartment of the Leg</b>				
1	Tibialis anterior	Lateral condyle and body of tibia and interosseous membrane	The first metatarsal and the first (medial) cuneiform	Dorsiflexes foot at ankle joint and inverts foot at intertarsal joints
2	Extensor hallucis longus	Anterior surface of fibula and interosseous membrane	Distal phalanx of great toe	Dorsiflexes foot at ankle joint and extends proximal phalanx of great toe at metatarsophalangeal joint

No	Muscle	Origin	Insertion	Action
3	Extensor digitorum longus	Lateral condyle of tibia, anterior surface of fibula, and interosseous membrane	Middle and distal phalanges of toes 2 – 5	Dorsiflexes foot at ankle joint and extends distal and middle phalanges of each toe at interphalangeal joints and proximal phalanx of each toe at metatarsophalangeal joint
4	Fibularis (peroneus) tertius NB! This muscle is not constant	Distal third of fibula and interosseous membrane	Base of the fifth metatarsal bone	Dorsiflexes foot at ankle joint and everts foot at intertarsal joints
<b>Lateral (Fibular) Compartment of the Leg</b>				
1	Fibularis (Peroneus) longus	Head and body of fibula and lateral condyle of tibia	First metatarsal and first cuneiform	Plantar flexes foot at ankle joint and everts foot at intertarsal joints
2	Fibularis (Peroneus) brevis	Body of fibula	Base of fifth metatarsal	Plantar flexes foot at ankle joint and everts foot at intertarsal joints
<b>Superficial Posterior Compartment of the Leg</b>				
1	Triceps surae: • lateral and medial heads of gastrocnemius  • soleus	• Lateral and medial condyles of femur and capsule of knee  • Head of fibula and medial border of tibia	Calcaneal tuberosity by way of calcaneal (Achilles) tendon	• Plantar flexes foot at ankle joint and flexes leg at knee joint  • Plantar flexes foot at ankle joint
2	Plantaris	Femur superior to lateral condyle	Calcaneus by way of calcaneal (Achilles) tendon	Plantar flexes foot at ankle joint and flexes leg at knee joint
<b>Deep Posterior Compartment of the Leg</b>				
1	Popliteus	Lateral condyle of femur	Proximal part of tibia	Flexes leg at knee joint and medially rotates tibia to unlock the extended knee
2	Tibialis posterior	Tibia, fibula, and interosseous membrane	Second, third, and fourth metatarsals; navicular; all three cuneiforms; cuboid	Plantar flexes foot at ankle joint and inverts foot at intertarsal joints
3	Flexor digitorum longus	Posterior surface of tibia	Distal phalanges of toes 2 – 5	Plantar flexes foot at ankle joint; flexes distal and middle phalanges of each toe at interphalangeal joints and proximal phalanx of each toe at metatarsophalangeal joint

No	Muscle	Origin	Insertion	Action
4	Flexor hallucis longus	Inferior two-thirds of fibula	Distal phalanx of great toe	Plantar flexes foot at ankle joint; flexes distal phalanx of great toe at interphalangeal joint and proximal phalanx of great toe at metatarsophalangeal joint
<b>MUSCLE OF THE FOOT</b>				
<b>Dorsal Group</b>				
1	Extensor hallucis brevis	Calcaneus	Phalanges of the great toe	Extends the great toe
2	Extensor digitorum brevis	Calcaneus and inferior extensor retinaculum	Tendons of extensor digitorum longus on toes 2 – 4 and proximal phalanx of great toe	Extensor hallucis brevis extends great toe at metatarsophalangeal joint and extensor digitorum brevis extends toes 2 – 4 at interphalangeal joints
<b>Plantar Group. The First Layer (Most Superficial)</b>				
1	Abductor hallucis	Calcaneus, plantar aponeurosis and flexor retinaculum	Medial side of proximal phalanx of great toe with the tendon of the flexor hallucis brevis	Abducts and flexes great toe at metatarsophalangeal joint
2	Flexor digitorum brevis	Calcaneus and plantar aponeurosis	Sides of middle phalanx of toes 2 – 5	Flexes toes 2 – 5 at proximal interphalangeal and metatarsophalangeal joints
3	Abductor digiti minimi	Calcaneus and plantar aponeurosis	Lateral side of proximal phalanx of little toe with the tendon of the flexor digiti minimi brevis	Abducts and flexes little toe at metatarsophalangeal joint
<b>The Second Layer</b>				
1	Quadratus plantae	Calcaneus	Tendon of flexor digitorum longus	Assists flexor digitorum longus to flex toes 2 – 5 at interphalangeal and metatarsophalangeal joints
2	Lumbricals	Tendons of flexor digitorum longus	Tendons of extensor digitorum longus on proximal phalanges of toes 2 – 5	Extend toes 2 – 5 at interphalangeal joints and flex toes 2 – 5 at metatarsophalangeal joints

No	Muscle	Origin	Insertion	Action
<b>The Third Layer</b>				
1	Flexor hallucis brevis	Cuboid and the third (lateral) cuneiform	Medial and lateral sides of proximal phalanx of great toe via a tendon containing a sesamoid bone	Flexes great toe at metatarsophalangeal joint
2	Adductor hallucis	Metatarsals 2 – 4, ligaments of 3 – 5 metatarsophalangeal joints, and tendon of peroneus longus	Lateral side of proximal phalanx of great toe	Adducts and flexes great toe at metatarsophalangeal joint
3	Flexor digiti minimi brevis	Metatarsal 5 and tendon of peroneus longus	Lateral side of proximal phalanx of little toe	Flexes little toe at metatarsophalangeal joint
<b>The Fourth Layer (Deepest)</b>				
1	Dorsal interossei	Adjacent side of metatarsals	Proximal phalanges: both sides of toe 2 and lateral side of toes 3 and 4	Abduct and flex toes 2 – 4 at metatarsophalangeal joints and extend toes at interphalangeal joints
2	Plantar interossei	Metatarsals 3 – 5	Medial side of proximal phalanges of toes 3 – 5	Adduct and flex proximal metatarsophalangeal joints and extend toes at interphalangeal joints
3	Extensor digitorum brevis	Calcaneus and inferior extensor retinaculum	Tendons of extensor digitorum longus on toes 2 – 4 and proximal phalanx of great toe	Extensor hallucis brevis extends great toe at metatarsophalangeal joint and extensor digitorum brevis extends toes 2 – 4 at interphalangeal joints



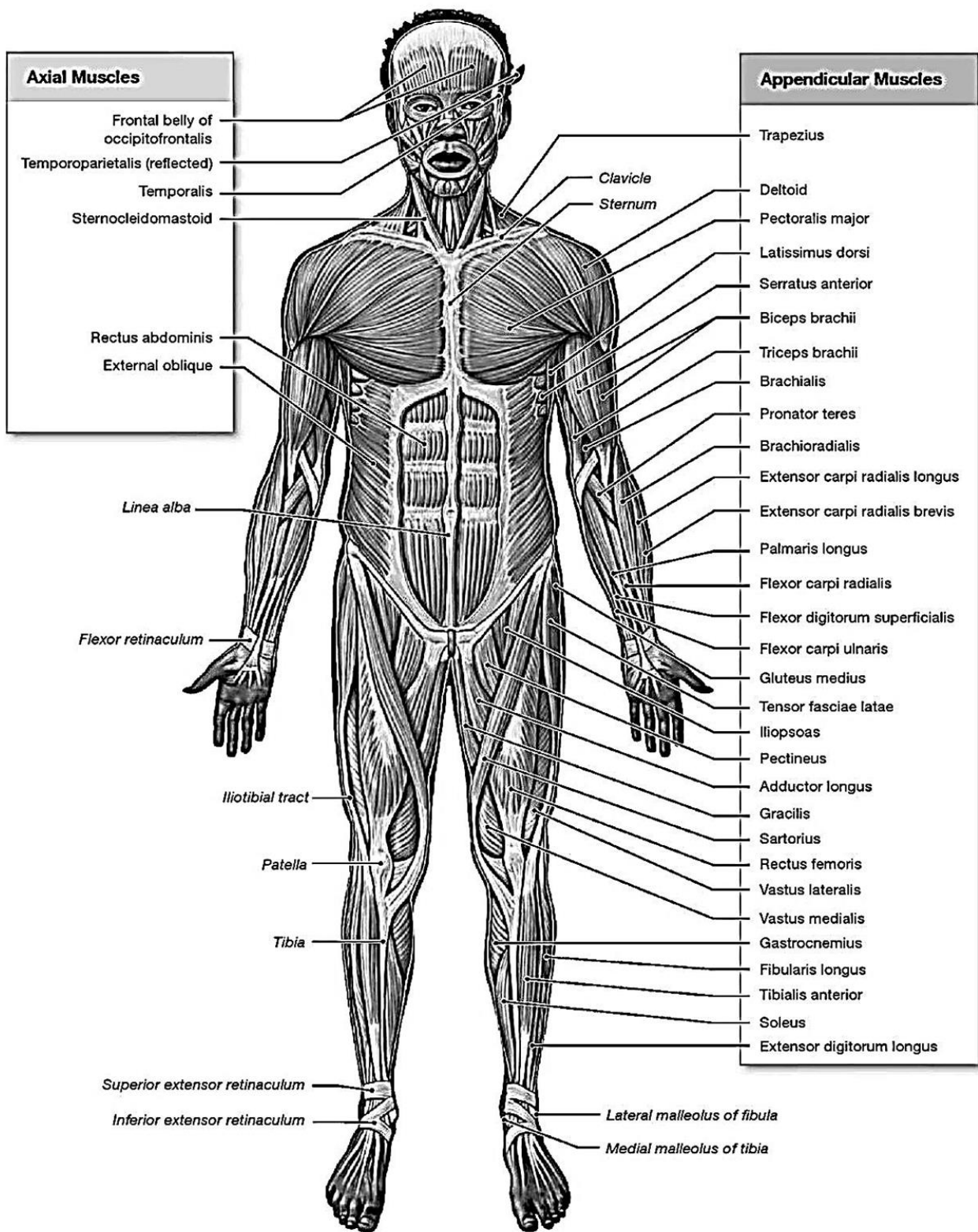


Figure 51 – An overview of the major skeletal muscles (anterior view)

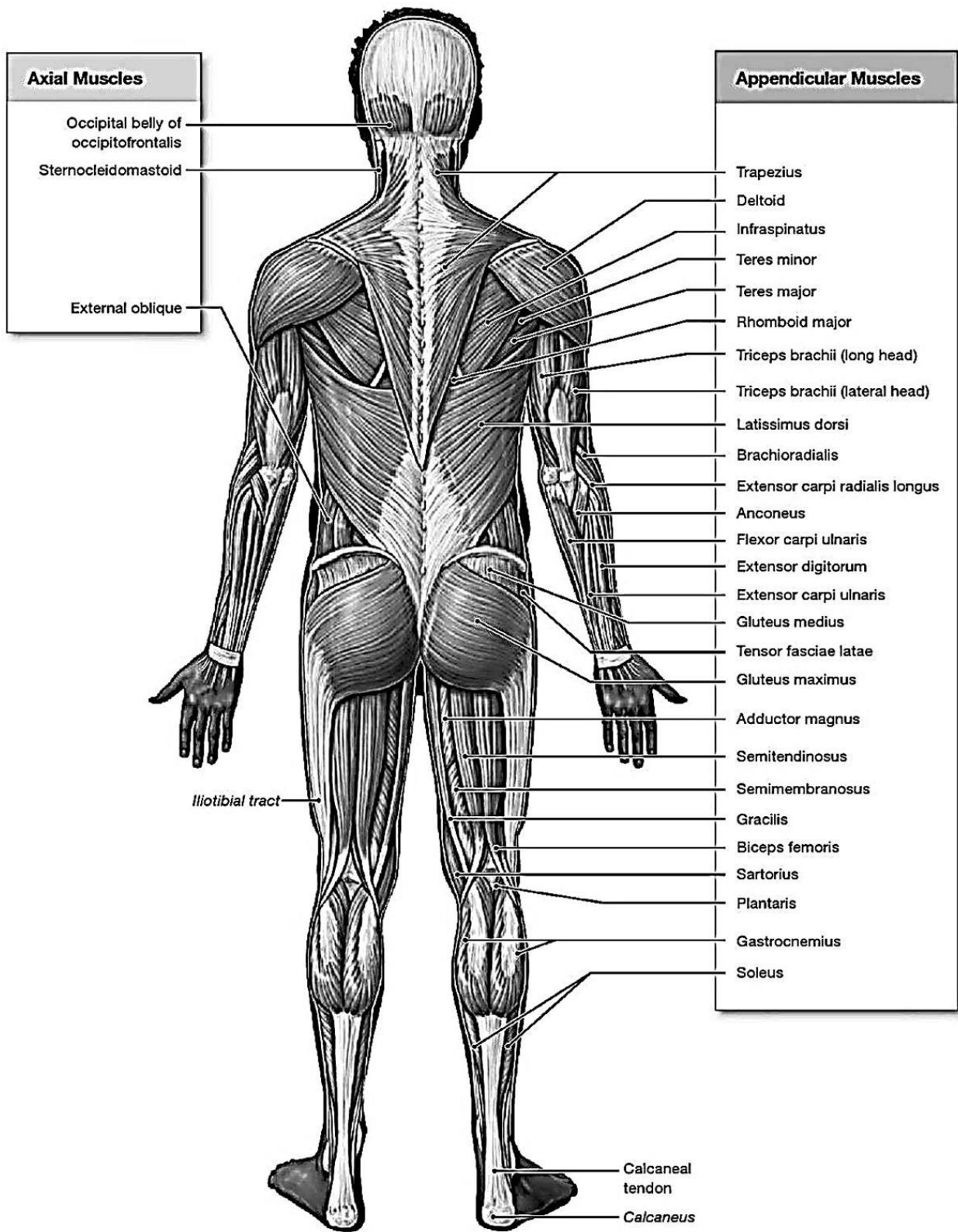


Figure 52 – An overview of the major skeletal muscles (posterior view)

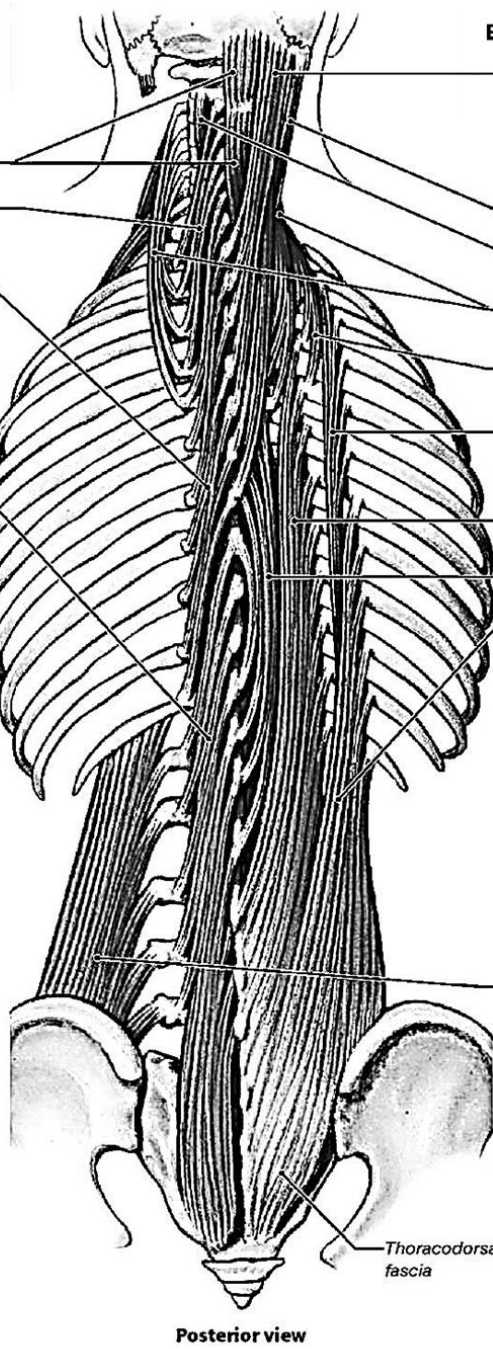
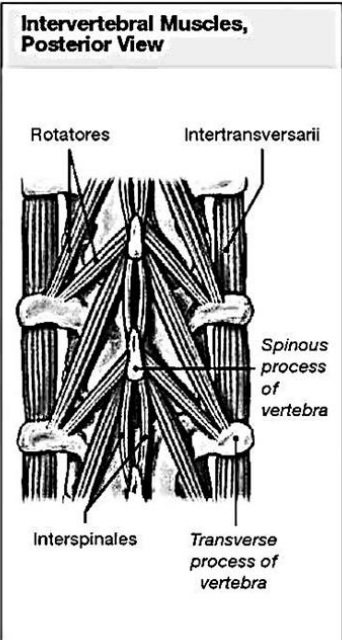
**Erector Spinae, Deep Layer**

- | Semispinalis Group    |  |
|-----------------------|--|
| Semispinalis capitis  |  |
| Semispinalis cervicis |  |
| Semispinalis thoracis |  |

Multifidus

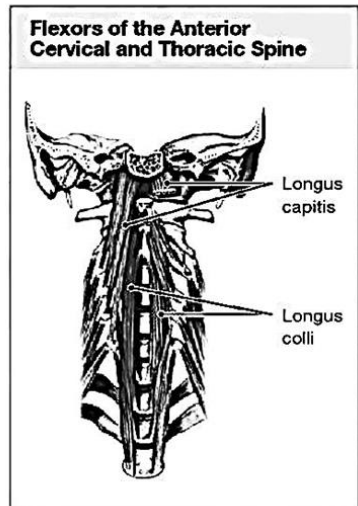
**Erector Spinae, Superficial Layer**

- | Spinalis, Longissimus, and Iliocostalis Group |  |
|---|--|
| Spinalis capitis                              |  |
| Longissimus capitis                           |  |
| Spinalis cervicis                             |  |
| Longissimus cervicis                          |  |
| Iliocostalis cervicis                         |  |
| Iliocostalis thoracis                         |  |
| Longissimus thoracis                          |  |
| Spinalis thoracis                             |  |
| Iliocostalis lumborum                         |  |



**Spinal Flexors**

Quadratus lumborum



**Figure 53 – Muscles of the vertebral column**

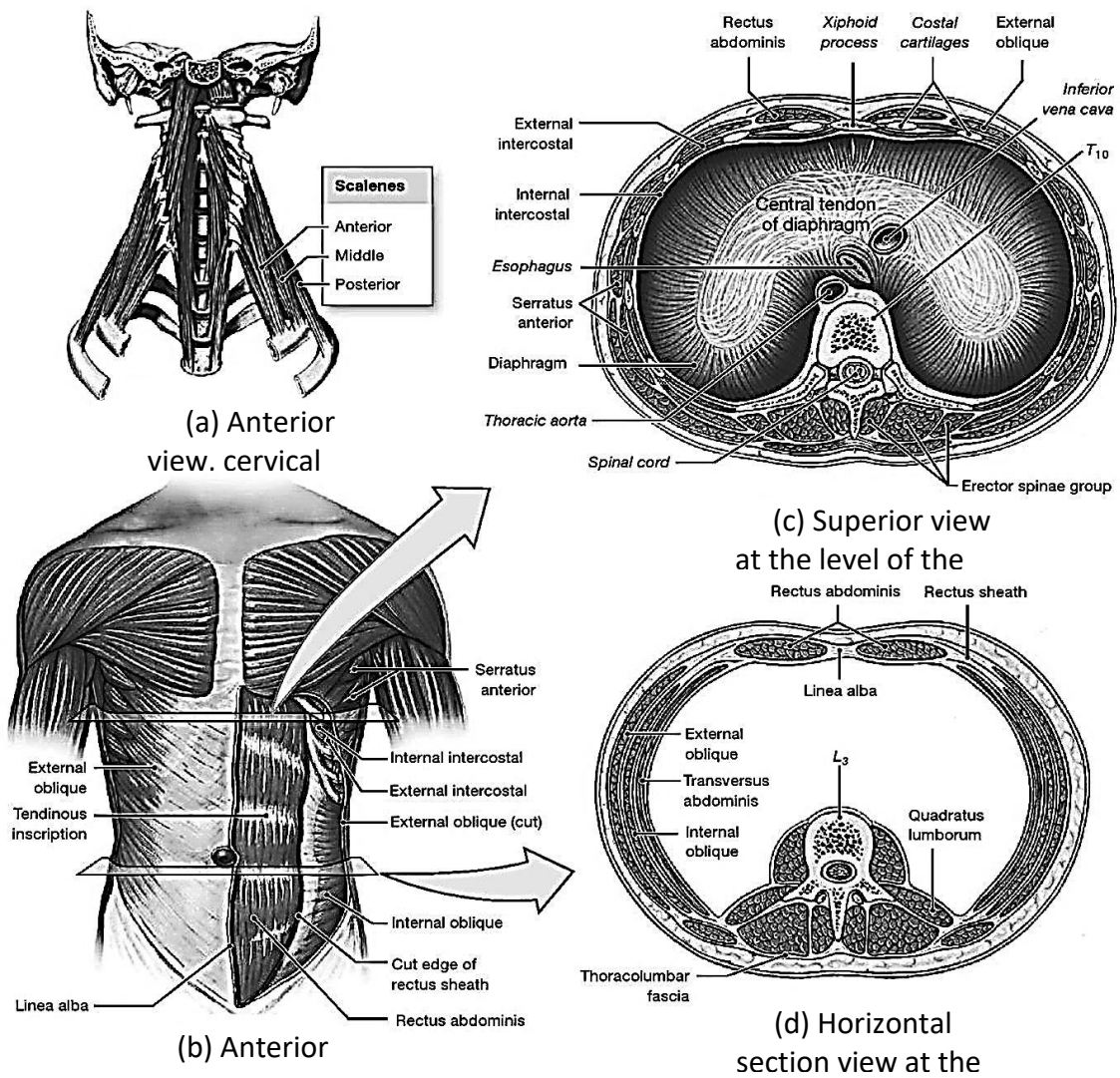


Figure 54 – Oblique and rectus muscles and the diaphragm

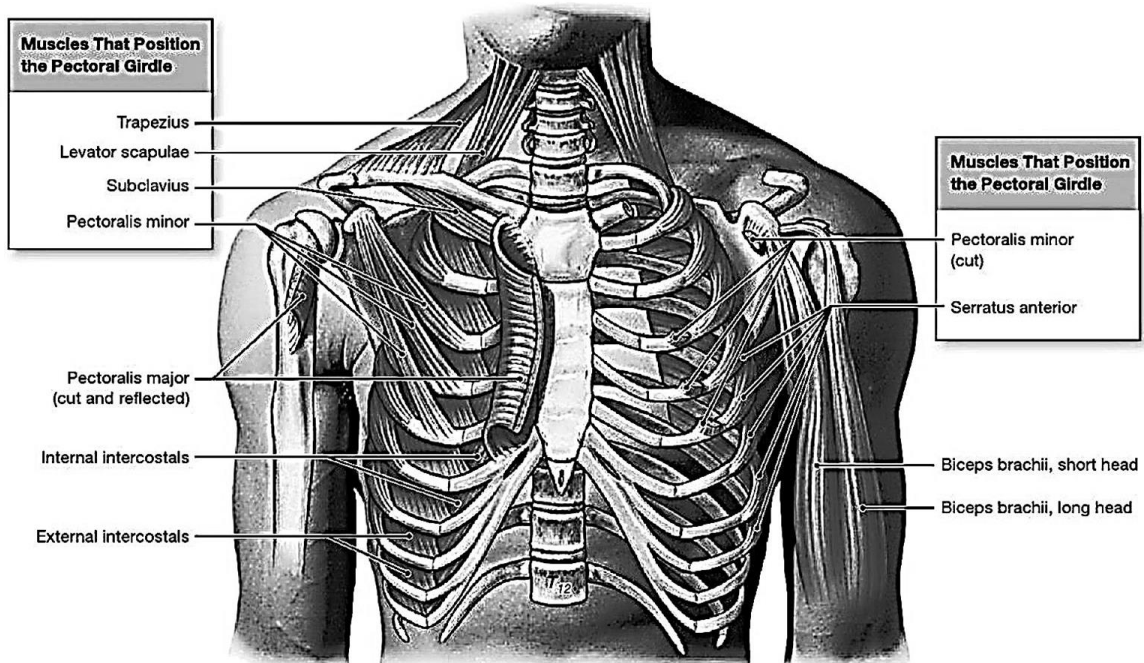


Figure 55 – Muscles of the pectoral girdle (anterior view)

**Superficial Dissection**

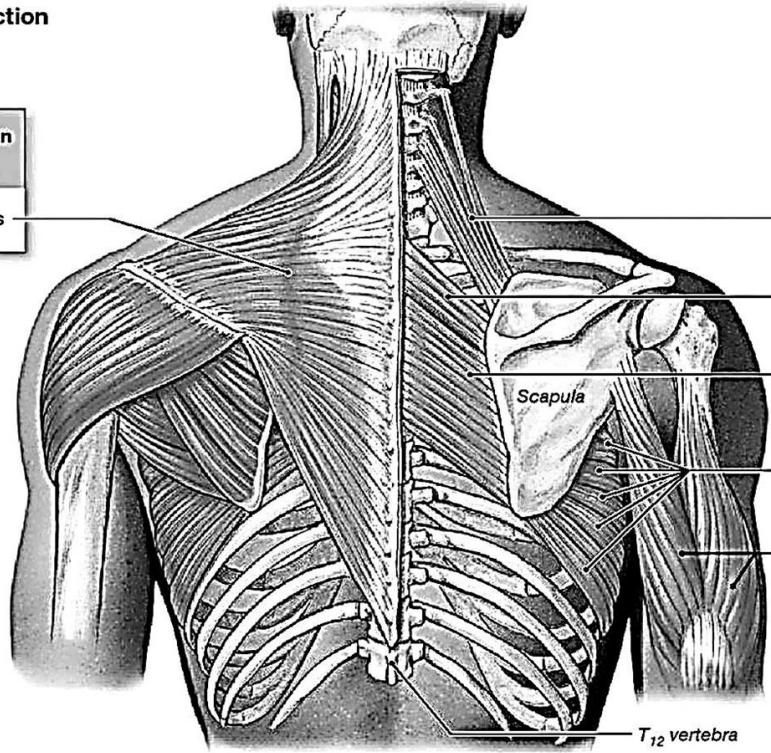
**Deep Dissection**

**Muscles That Position the Pectoral Girdle**

Trapezius

**Muscles That Position the Pectoral Girdle**

Levator scapulae  
 Rhomboid minor  
 Rhomboid major  
 Serratus anterior  
 Triceps brachii



**Figure 56 – Muscles of the pectoral girdle (posterior view)**

**Superficial Dissection**

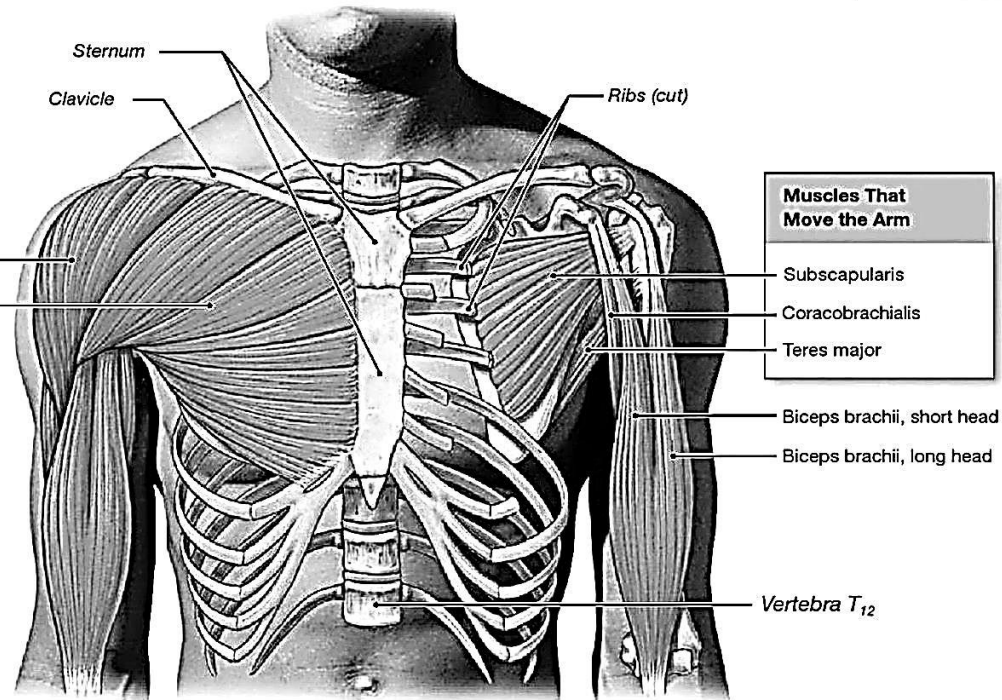
**Deep Dissection**

**Muscles That Move the Arm**

Deltoid  
 Pectoralis major

**Muscles That Move the Arm**

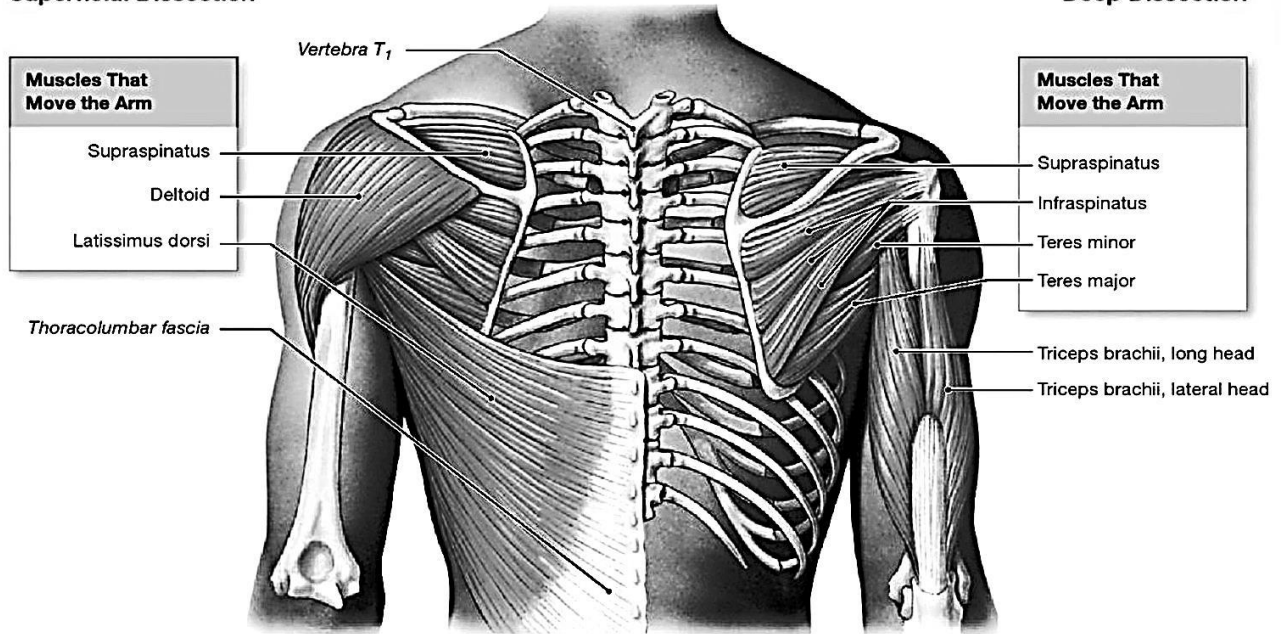
Subscapularis  
 Coracobrachialis  
 Teres major



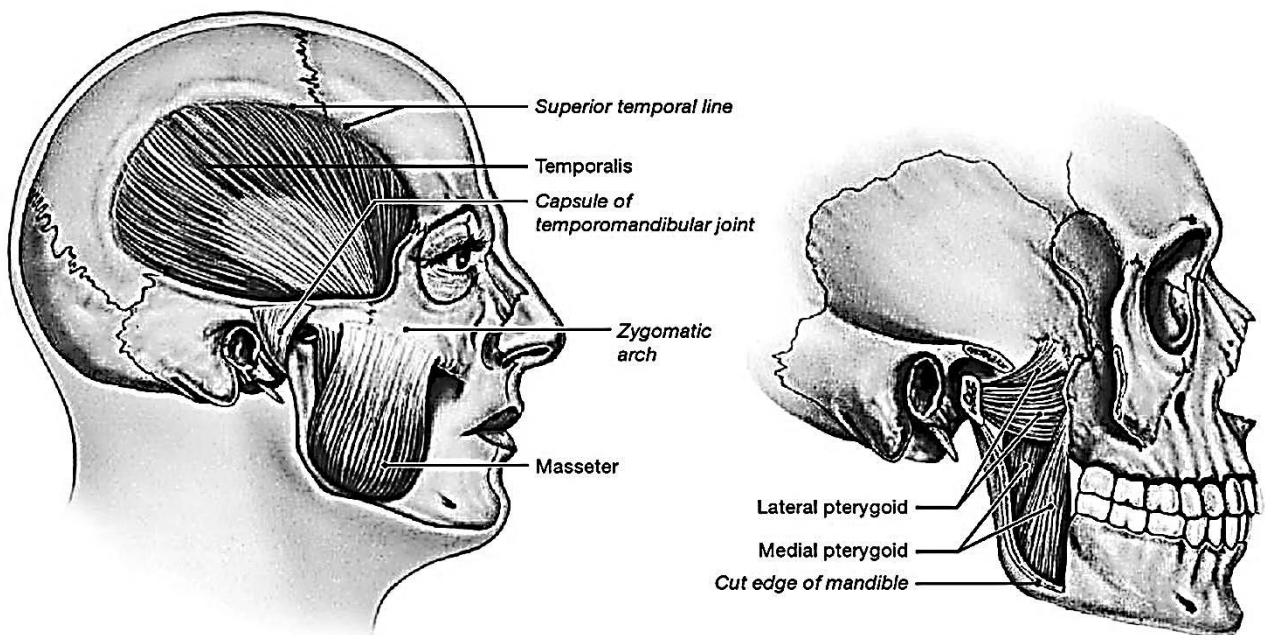
**Figure 57 – Muscles that move the arm (anterior view)**

**Superficial Dissection**

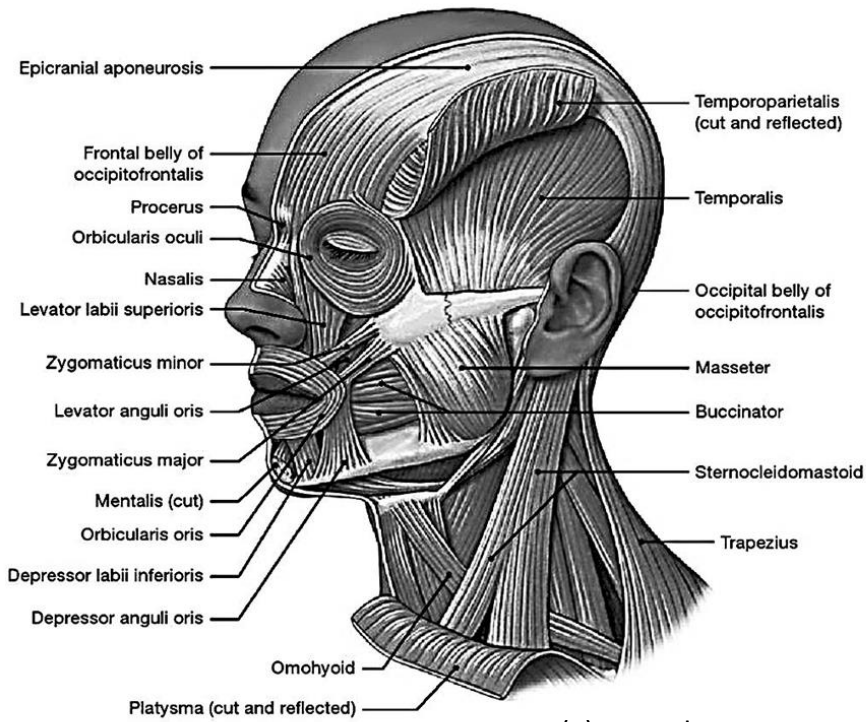
**Deep Dissection**



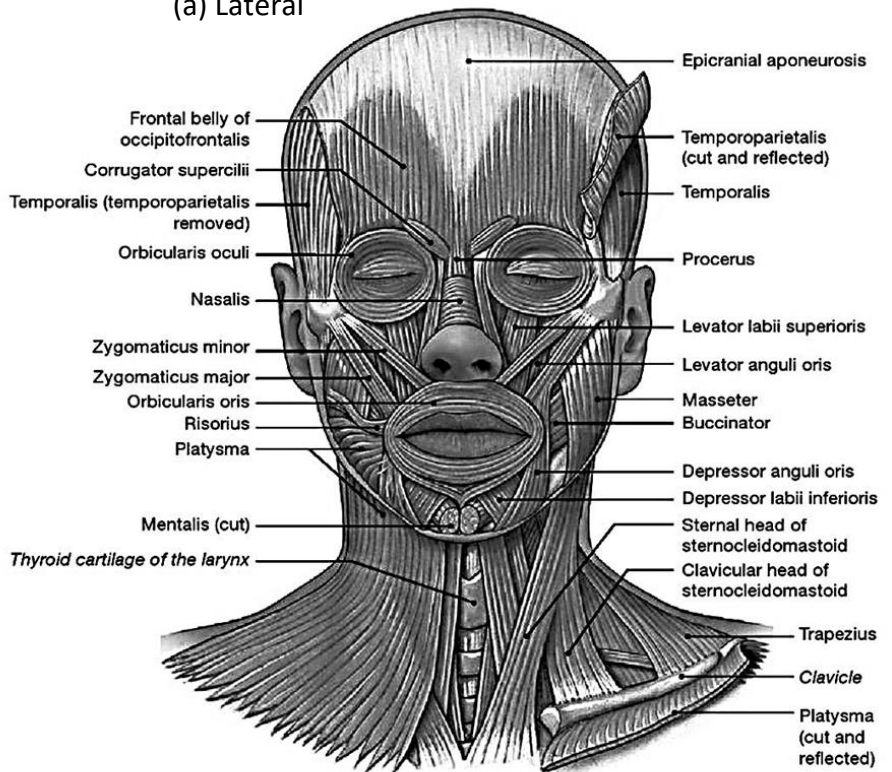
**Figure 58 – Muscles that move the arm (posterior view)**



**Figure 59 – Muscles of mastication**



(a) Lateral



(b) Anterior

Figure 60 – Muscles of facial expression

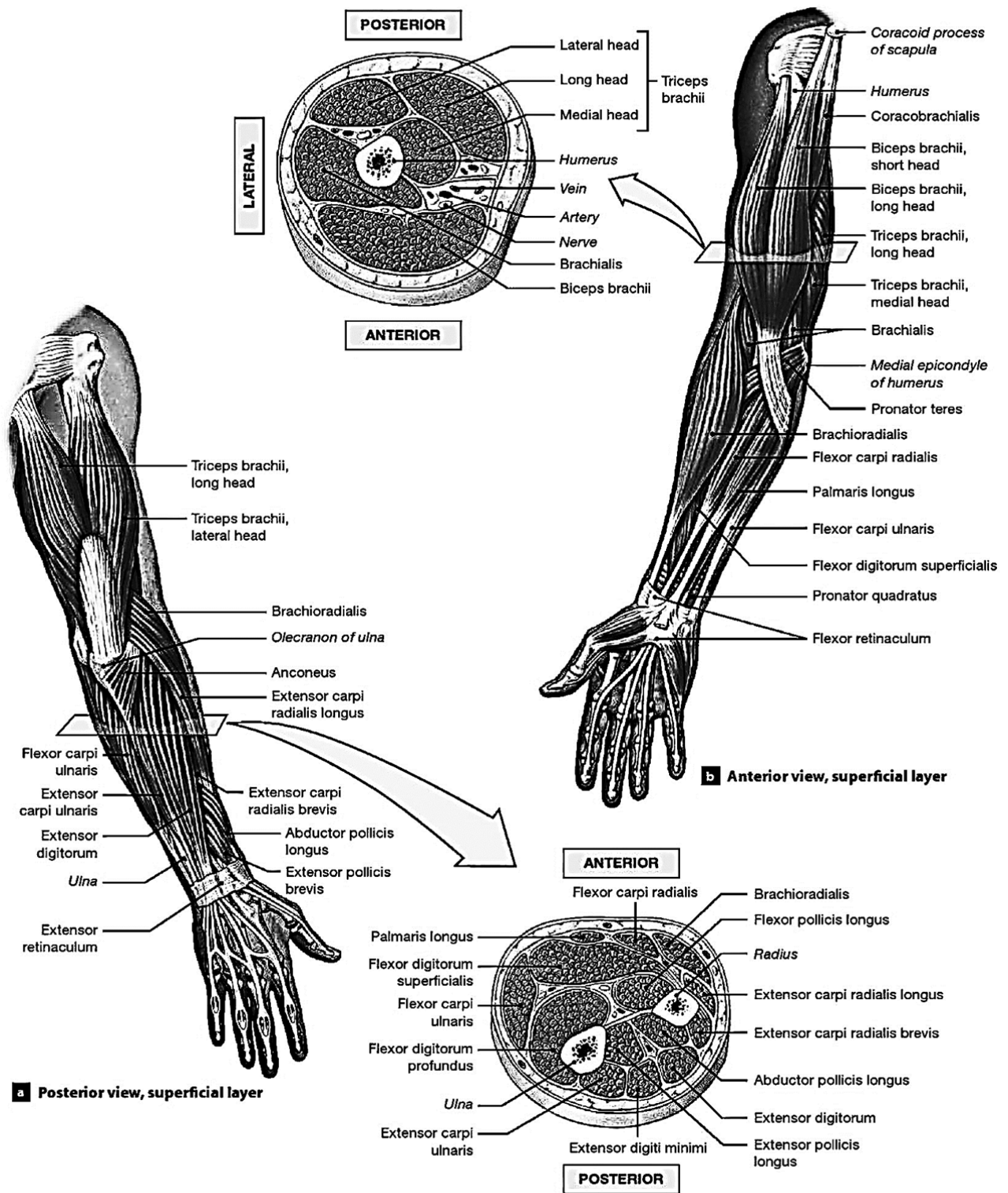
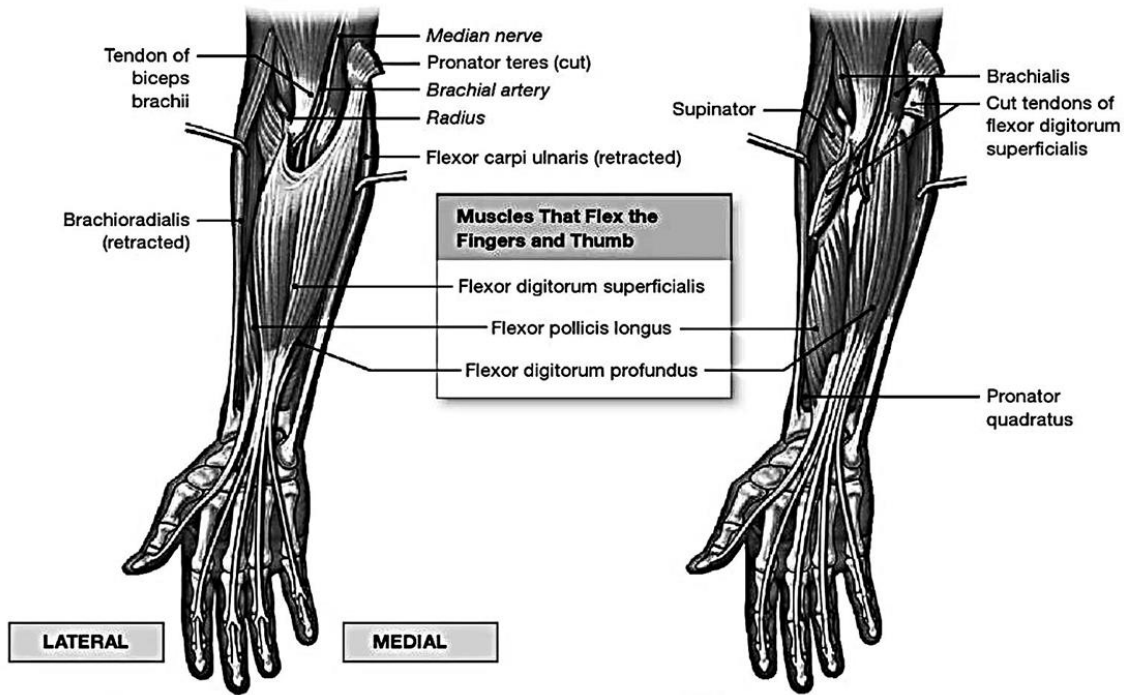


Figure 61 – Muscles of the forearm and hand

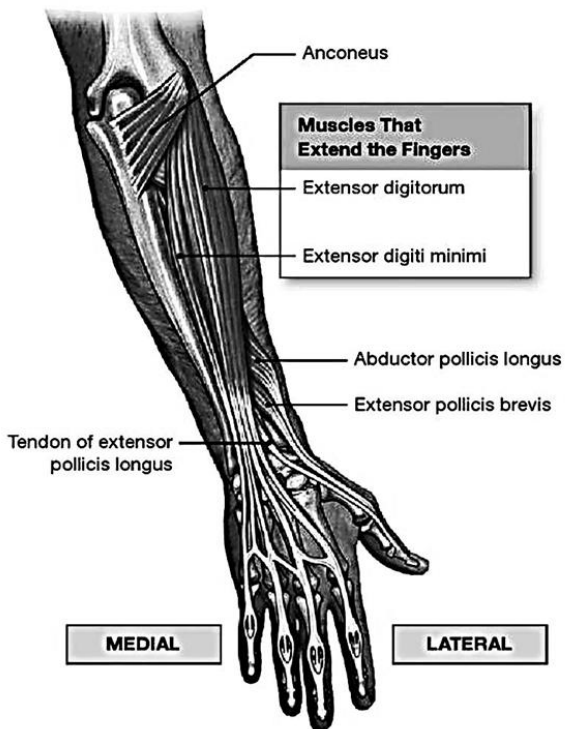


(b) Anterior view,

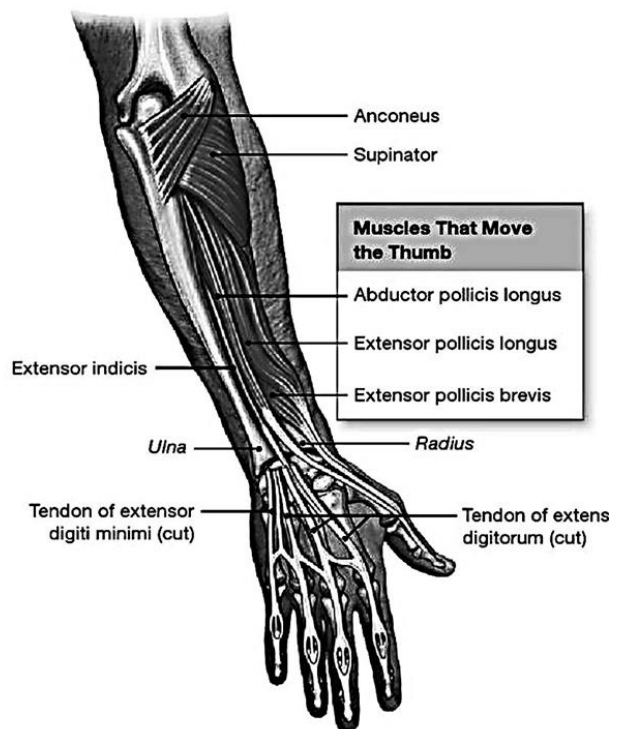


(a) Anterior view, middle

(b) Anterior view



(c) Posterior view, middle



(d) Posterior view

Figure 62 – Muscles of the hand and fingers

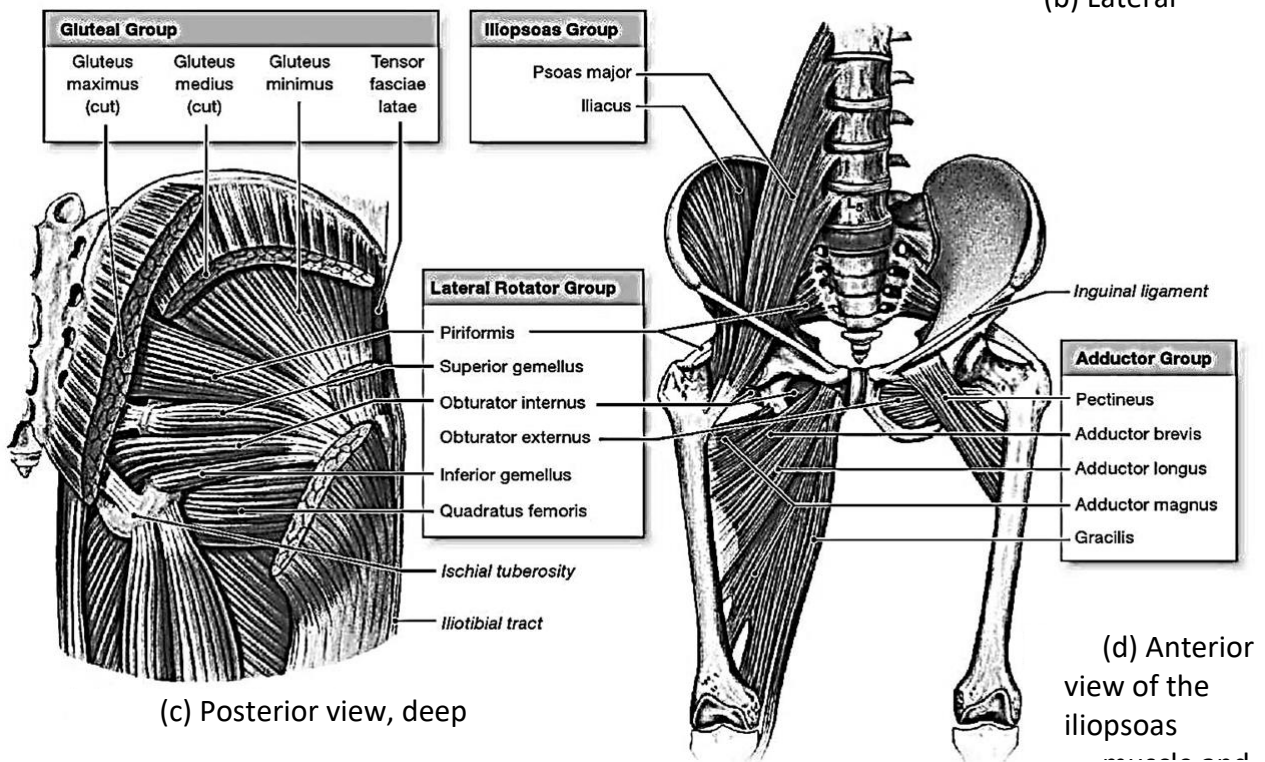
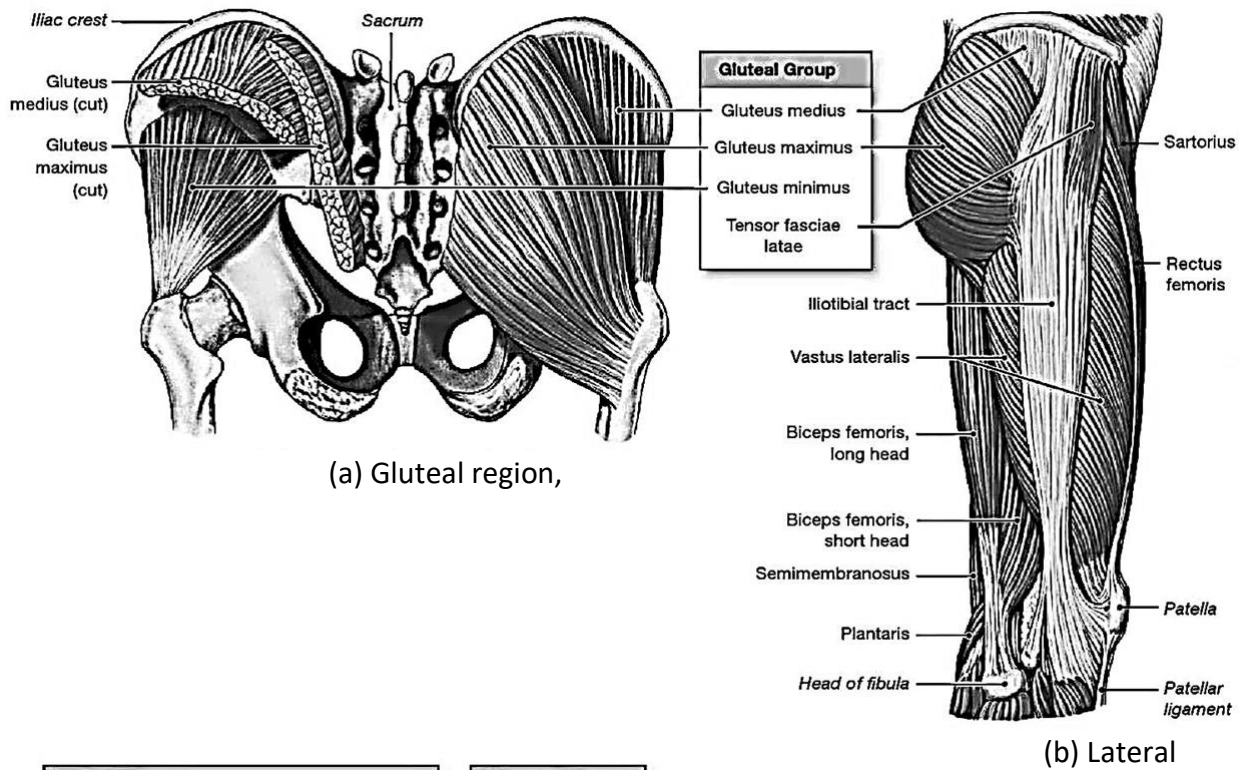


Figure 63 – Muscles of the thigh

## HUMAN BODY FASCIA

(see Figures 64 – 70)

### Fasciae of the back

**The superficial fascia of the back** covers the outer surface of superficial muscles (trapezius, latissimus dorsi) forming their sheath. It thickens in the upper portion and is called the nuchal fascia.

Another fascia of the back lies deeper and separates the deep (autochthonous) muscles of the back from the superficial muscles. It is called **the thoracolumbar fascia**, and two layers are distinguished in it:

- **the superficial (posterior) layer** which stretches from the pelvis to the head. Its upper part is thin, but its lower part is very strong where it is continuous with the aponeurosis of the latissimus dorsi muscle; medially, it is attached to the spinous processes, laterally, it is continuous with the ribs;

- **the deep (anterior) layer** which originates from the transverse processes of the lumbar vertebrae and stretches only between the twelfth rib and the iliac crest. Running laterally, the deep layer covers the anterior surface of the erector spinae and, on the lateral border of this muscle, merges with the superficial layer. Thus the deep (autochthonous) muscles are invested in a closed fibrous sheath.

### Fasciae of the chest

There is following chest fasciae classification:

**The superficial fascia** is thin.

**The pectoral fascia** covers the pectoralis major and the serratus anterior on the outside. The fascia attaches to the clavicle above, to the sternum medially, and laterally, it is continuous with the deltoid and axillary fascia. In females this fascial sheet separates the pectoral muscle from the mammary gland.

**The clavipectoral fascia** lies under the pectoralis major muscle; it is the thickest in the region of the clavipectoral triangle and extends from the clavicle and coracoid process of the scapula downward and encloses the pectoralis minor and subclavius muscles. The clavipectoral fascia merges with the pectoral fascia below.

**The thoracic fascia** covers the intercostal muscles and the ribs outside.

**The endothoracic fascia** lines the inner surface of the thoracic cage (intercostal muscles, ribs and diaphragm).

### Fasciae of the abdomen

The fasciae of the abdomen are as follows:

**The superficial fascia** is a direct continuation of the superficial fascia of the chest.

**The proper fascia** covers the abdominal muscles. It separates into three fascial sheets, which lie between the fleshy parts of the abdominal muscles.

**The endoabdominal fascia** lines the inner surface of the abdominal cavity. The portion of the fascia which covers the inner surface of the transversus abdominis is called the transverse fascia. It merges with the inguinal ligament and pubic symphysis below.

### Fasciae of the abdomen

**The superficial fascia** is a continuation of a superficial fascia of the chest. It splits into superficial and deep layers between which a superficial veins pass.

**The proper fascia** covers abdominal muscles separating into three fascial sheets.

**The endoabdominal fascia** covers the inner surface of the abdominal cavity. Its well developed part which covers transversus abdominis muscle is called **the transverse fascia (fascia transversalis)**.

### Fasciae of the neck

All fasciae of the neck are embraced under the term fascia cervicalis, which is divided into three layers as follows:

**The superficial layer** encloses the whole neck like a collar and forms the fascial sheaths for the sternocleidomastoid, trapezius and the submandibular salivary gland. It is attached above to the mandible and the mastoid process and is continuous with the parotid – masseteric fascia which cover the parotid gland and the masseter muscle. Below, the superficial layer is attached to the hyoid bone, whereas in the lower part of the neck – to the anterior border of the manubrium sterni and the clavicle. On each side of the neck, the superficial layer passes to the spinous processes of the cervical vertebrae. On reaching the sternocleidomastoid and the trapezius muscles, it separates into two lamellae, encloses

the muscles and fuses again, thus forming fascial sheets for each of these muscles separately. In the part where the superficial layer of the cervical fascia passes over the transverse processes, it attaches to them and gives off a fascial branch in the form of a frontally situated lamina, separating the entire fascial space of the neck into two parts, anterior and posterior.

**The pretracheal layer** (aponeurosis of Rishet) is present only in the middle part of the neck behind the sternocleidomastoid, where it is stretched like a trapezium over a triangular space bounded by the hyoid bone above, by the omohyoid muscles on both sides, and by the clavicles and the posterior border of the manubrium sterni below. This layer fuses with the deep veins of the neck.

**The prevertebral layer** covers anteriorly the prevertebral and scalene muscles stretching on the spine, and by fusing with the transverse processes of the vertebrae forms sheaths for these muscles. Above, the prevertebral fascia arises from the base of the skull behind the pharynx, descends through the entire length of the neck, and enters the posterior mediastinum where it merges with the endothoracic fascia.

The cervical fascia forms a fascial sheet for the major neurovascular bundle of the neck, which is called the carotid sheath. It encloses the common carotid artery, the internal jugular vein, and the vagus nerve.

#### **The interfascial spaces of the neck**

There are three interfascial spaces between the layers of the cervical fascia, which are filled with the loose fatty tissue.

**The suprasternal space** is situated between the superficial and pretracheal layers of the cervical fascia above the manubrium sterni and the clavicles. The space contains the adipose tissue and the superficial veins of the neck (the jugular venous arch). Laterally this space communicates with lateral recesses, a blind space behind the inferior ends of the sternocleidomastoid muscles.

**The previsceral space** resides between the pretracheal layer of the cervical fascia and the trachea. The latter contains the fatty tissue, the lymph nodes, the isthmus of the thyroid gland and blood vessels. The previsceral space extends into the thoracic cavity and superior and inferior mediastinum.

**The retrovisceral space** resides behind the pharynx and the oesophagus and in front of the prevertebral layer of the cervical fascia. It is filled with loose fatty tissue and is continuous downwards with the superior and inferior mediastinum.

#### **Fasciae of the head**

The muscles of the facial expression (except the buccinator) are not covered by fasciae. The fasciae of the head are located in the region of the masticatory muscles.

**The temporal fascia** is a strong fibrous lamina that covers the temporal muscle and arises above from the superior temporal line of the parietal bone. Below, it attaches to the zygomatic arch and separates into two layers:

- a superficial layer that fuses with the external surface of the zygomatic arch;
- a deep layer that fuses with the internal surface of the arch. The space between the two layers is filled with fatty tissue.

**The parotid fascia** forms a capsule around the parotid gland.

**The masseteric fascia** invests the muscle and attaches to the zygomatic arch above, to the mandibular border below, and to the mandibular ramus posteriorly and anteriorly. Posteriorly, this fascia is connected with the parotid fascia.

**The buccopharyngeal fascia** covers the posterior portion of the buccinator muscle extending into the pharynx posteriorly. There is a deep space between the buccinator and the masseter filled with the buccal fat pad.

#### **Fasciae of the upper limb**

**The superficial fascia** is a part of the common superficial fascia of the body.

**The proper fascia** has different names depending on its location.

#### **Fasciae of the shoulder girdle**

**The deltoid fascia** covers the deltoid muscle and gives off processes projecting between the muscular bundles. This fascia is continuous anteriorly with the pectoral fascia and posteriorly with the superficial fascia of the back.

**The supraspinous fascia** covers the corresponding muscle.

**The infraspinous fascia** is a dense connective tissue covering the infraspinatus muscle.

**The axillary fascia** is a thin plate forming the floor of the axillary cavity.

#### **Fasciae of the upper arm**

**The brachial fascia**, which forms a tubular investment for the muscles of the upper arm, is quite thin. On both sides the brachial fascia gives off two fibrous intermuscular septa, which project deeply and separate the anterior muscles of the arm from the posterior.

**The medial intermuscular septum** passes between the brachial and the triceps brachii muscles on the medial side.

**The lateral intermuscular septum** passes on the lateral border of the upper arm between the brachial, on one side, and the triceps and the brachioradialis muscles – on the other side.

#### **Fasciae of the forearm**

The fascia of the arm is continuous with the forearm fascia and has a thickened band there, which is part of the tendon of the biceps muscle, aponeurosis m. bicipitis brachii. In the upper part of the forearm, the antebrachial fascia tightly fuses with the muscles which take their origin from it. The antebrachial fascia invests the forearm muscles and produces fibrous septa, which project between them. The fascia fuses with the bones of the forearm and separates the flexors from the extensors. In the region of the wrist joint, the antebrachial fascia forms a transverse thickening in the form of ligaments, which are called the retinacula.

**The extensor retinaculum** extends from the radius toward the styloid process of the ulna on the dorsal surfaces. Processes from the retinaculum fuse with the dorsal surfaces of bones. Between these processes under the retinaculum, there are six canals which are osteofibrous. These canals transmit tendons surrounded by the synovial sheaths.

**The first canal** (beginning from the radial side) transmits the tendons of the abductor pollicis longus and the extensor pollicis brevis.

**The second** canal transmits the tendons of the extensor carpi radialis longus and brevis.

**The third** canal, crossing the preceding canal obliquely, transmits the tendon of the extensor pollicis longus.

**The fourth** canal transmits the tendons of the extensor digitorum and the extensor indicis.

**The fifth** canal, situated more superficially, transmits the tendon of the extensor digiti minimi.

**The sixth** canal transmits the tendon of the extensor carpi ulnaris.

The walls of the canals are lined with a synovial membrane, which, above and below the extensor retinaculum, folds over the tendons and covers them, forming the tendon sheath of the dorsal muscles.

The number of sheaths corresponds to the number of canals. The sheaths protrude on the dorsal surface of the hand from under the extensor retinaculum.

**The flexor retinaculum** resides on the palmar surface in the region of the wrist joint. It passes across the carpal groove turning it into the carpal canal. Two isolated synovial sheaths traverse the carpal canal, extending onto the first and fifth fingers. There are three isolated synovial sheaths on the second, third, and fourth fingers. Outside the carpal canal, the tendon of the flexor carpi radialis is covered by the synovial sheath, but it does not extend onto the hand.

**The common flexor sheath** is a large, medially located sac, enclosing eight tendons of the deep and superficial flexors of the fingers. Superiorly, it protrudes 1–2 cm proximally of the flexor retinaculum, while inferiorly, it reaches the middle of the palm. The sheath continues only on the tendons of the long flexors of the little finger, surrounds them and reaches, together with them, the base of the distal phalanx of the little finger.

**The tendinous sheath of the flexor pollicis longus muscle** is situated laterally in the carpal canal. It encloses the tendon of the corresponding muscle. Superiorly, this sheath also protrudes 1–2 cm proximally of the flexor retinaculum, while inferiorly, it extends on the tendon to the base of the distal phalanx of the thumb.

**The synovial sheaths of the digital tendons** enclose the tendons of the flexors of the index, middle, and ring fingers (there are three sheaths in all). These sheaths stretch from the metacarpophalangeal joints to the base of the distal phalanges. Three fingers have isolated sheaths for the tendons of their common flexors on the palmar surface, but are devoid of these sheaths in the segment corresponding to the distal halves of the metacarpal bones.

## Fasciae of the hand

**The palmar fascia** of the hand covers the muscles of the thenar and hypothenar eminences and encloses tendons of the flexor digitorum superficialis and lies deep as well as the lumbricals. The thickened fascia in the middle of the palm forms a strong **palmar aponeurosis**, which is an extension of the tendon of the long palmar muscle. It comprises both transverse and longitudinal fibers. The palmar aponeurosis is triangular, with the apex lying on the flexor retinaculum and the base directed to the fingers, where it separates into four flat slips.

**The dorsal fascia** of the hand contains superficial and deep layers. The thin **superficial layer** covers the tendons of the extensors, while the thicker **deep layer** covers dorsal interosseous muscles and fuses with the metacarpal bones.

## TOPOGRAPHY OF THE UPPER LIMB

(see Figures 71 – 76)

### Topography of the thoracic girdle

**The axillary cavity** is viewed after removing the skin, fasciae, vessels, nerves, and lymph nodes located in the axillary region. **The axillary fossa** is clearly visible on the skin. The axillary cavity has the shape of the quadrangular pyramid with its apex (the upper aperture) facing upward and medially to the region of the neck. Inferiorly, the axillary cavity ends in an opening (the lower aperture). The walls of the axillary cavity are formed by the following muscles:

- the anterior wall – the pectoralis major and minor;
- the posterior wall – the subscapularis, the teres major, and the latissimus dorsi;
- the medial wall – the serratus anterior;
- the lateral wall – the humerus and the short head of the biceps brachii and the coracobrachialis covering it.

On the posterior wall of the axillary cavity, there are two openings which transmit vessels and nerves:

**The quadrangular opening** (lateral) is formed by the teres major muscle (below), the subscapularis muscle (above), the long head of the triceps brachii (medially), and the humerus (laterally).

**The triangular opening** (medial) is bounded by the teres major muscle (below), the subscapularis muscle (above), and the long head of the triceps brachii (laterally).

Three triangles are distinguished on the anterior wall of the axillary cavity:

**The clavipectoral triangle** resides between the clavicle and the upper border of the projection of the pectoralis minor.

**The pectoral triangle** corresponds to the projection of the pectoralis minor.

**The subpectoral triangle** resides between the inferior borders of the pectoralis minor (above) and pectoralis major (below).

There is a deep deltoideo-pectoral groove between the pectoralis major and the deltoid muscles.

### Topography of the upper arm

**The radial canal** transmits the radial nerve and the attendant deep brachial artery and vein. The sulcus of the radial nerve of the humerus is covered by the triceps muscle, and thus converted in the radial canal. The canal has a spiral route. It begins on the medial surface of the arm between the medial and lateral heads of the triceps brachii and exits on the lateral surface of the arm between the brachialis and brachioradialis.

**The medial bicipital groove** is located medially between the biceps brachii and brachialis. It lodges the main neurovascular bundle of the upper arm.

**The lateral bicipital groove** lies between the lateral border of the biceps brachii and brachialis. It transmits the cephalic vein.

### Topography of the forearm

In front of the elbow joint, there is **the cubital fossa**, bounded by the brachioradialis muscle (laterally) and the pronator teres muscle (medially). The floor and the superior border of the fossa are formed by the brachialis muscle. Within the borders of the cubital fossa, there are two grooves located on each side from the brachialis muscle – **medial cubital groove and lateral cubital groove**.

There are three grooves between the anterior forearm muscles:

- the ulnar groove (medial) lies between the flexor carpi ulnaris and flexor digitorum superficialis. It transmits the ulnar nerve, artery, and vein.

- the median groove lies between the flexor carpi radialis (laterally) and the flexor digitorum superficialis (medially). It transmits the median nerve.

- the radial groove (lateral) runs between the brachioradialis (laterally) and flexor carpi radialis (medially). It contains the radial artery, vein, and nerve.

### Topography of the hand

**The carpal canal** is located in the region of the wrist joint under the flexor retinaculum. The tendons of the flexor digitorum superficialis, the flexor digitorum profundus, the flexor pollicis longus, and the median nerve pass via the canal. The flexor retinaculum splits on both sides of the canal and forms two other canals – the radial and the ulnar carpal canals.

The ulnar carpal canal transmits the ulnar artery, vein, and nerve. The radial carpal canal transmits the small synovial sheath of the tendon of the flexor carpi radialis muscle.

**The fibrous sheaths of the digits of the hand** are formed by the dense fibrous lamina of the fascia of the hand, which fuse with the phalanges. As a result, osteofibrous canals are formed, which contain tendons of the flexors covered by the synovial sheath. The fibrous sheath consists of the cruciform part (in the joint region) and the annular part (between them).

### Rectus sheath

(see Figure 77)

**The rectus sheath** is a long fibrous sheath that encloses the rectus abdominis muscle. It is formed mainly by aponeurosis of three lateral abdominal muscles:

- in the upper part above the navel, the sheath is formed in such a way that the aponeurosis of the external oblique muscle passes in front of the rectus muscle; the aponeurosis of the transversal muscle passes behind it; the aponeurosis of the internal oblique muscle splits into two laminae, which encompass the rectus muscle anteriorly and posteriorly. These aponeuroses form the anterior and posterior walls, of the sheath, which consist of 1,5 laminae of aponeuroses;

- in the lower part, 4 – 5 cm below the navel, the structure of the sheath is different: the

aponeuroses of the three abdominal muscles pass in front of the rectus abdominis muscle as anterior wall of its sheath, while the posterior wall is formed by transversal fascia.

It should be noted that the aponeuroses, forming the posterior wall, pass in front of the rectus abdominis muscle at the level of the anterior superior iliac spine; the posterior wall has a free, curved lower border, called the **arcuate line**.

When the rectus abdominis contracts, its lateral margin forms a curved ridge that can be palpated and often seen, and it is termed the **linea semilunaris**.

The rectus sheath is separated from its fellow on the opposite side by a fibrous band called **linea alba**.

It extends from the xiphoid process down to the symphysis pubis and is formed by the fusion of the aponeuroses of the lateral muscles of both sides. Wider above the umbilicus, it narrows down below the umbilicus to the attached to the symphysis pubis.

### Inguinal canal

(see Figure 78)

The inguinal canal is an oblique passage through the lower part of the anterior abdominal wall and is present in both-sexes. It conveys the spermatic cord in male. In females, the smaller canal conveys the round ligament of the uterus.

The canal is about 4 cm long in adult and extends from the deep inguinal ring downward and medially to the superficial inguinal ring. It lies immediately above and parallel to the inguinal ligament.

**The deep inguinal ring** is an oval opening in the fascia transversalis on the inner surface of the anterior abdominal wall. Medially, the ring is reinforced by the interfoveolar ligament. The deep inguinal ring projects into the lateral inguinal fossa.

**The superficial inguinal ring** is a triangular-shaped defect in the aponeurosis of the external oblique muscle and lies immediately above and medial to the pubic tubercle. The margins of the ring are called medial and lateral crura. Medially and posteriorly the superficial inguinal ring is reinforced by the **reflected ligament**. Superiorly

and laterally, it is strengthened by the **intercrural fibers**. The superficial inguinal ring projects onto the medial inguinal fossa on the inner surface of the anterior abdominal wall.

#### **Walls of the inguinal canal:**

- the anterior wall is formed by the aponeurosis of the external oblique muscle;
- the posterior wall is formed by the fascia transversalis;
- the inferior wall is formed by the rolled-under inferior edge of the aponeurosis of the external oblique muscle, namely, the inguinal ligament;
- the superior wall is formed by the arching lowest fibers of the internal oblique and transversus abdominis muscles.

#### **The folds and recesses on the internal surface of anterior abdominal wall**

(see Figure 87)

The umbilical folds are a series of 5 folds of parietal peritoneum on the deep surface of the anterior abdominal wall and consist of:

- a single midline median umbilical fold;
- bilateral medial umbilical folds;
- bilateral lateral umbilical folds.

The median umbilical fold is a raised ridge of parietal peritoneum in the deep aspect of the anterior abdominal wall overlying the median umbilical ligament (urachal remnant). It is seen to lie between the transversalis fascia and peritoneum. It is one of five umbilical folds and should not be confused with the bilateral medial umbilical folds (which is easy to do since the name differs by a single letter). It runs from the apex of the bladder to the umbilicus.

The medial umbilical folds are bilateral raised ridges of the parietal peritoneum in the deep aspect of the anterior abdominal wall formed by the underlying medial umbilical ligaments running from the pelvis to the umbilicus. The medial umbilical ligaments are anatomical remnants of the obliterated foetal umbilical arteries. The folds are 2 of the 5 umbilical folds and should not be confused with the single midline median umbilical fold.

The bilateral suprapubic fossa lies between the median and bilateral medial umbilical folds. The medial inguinal fossae lie between the medial and lateral umbilical folds.

The lateral umbilical folds are bilateral raised ridges of parietal peritoneum in the deep aspect of the anterior abdominal wall overlying the inferior epigastric vessels. The paired folds originate medially to the deep inguinal ring and end at the arcuate line on the posterior aspect of the anterior abdominal wall. The lateral inguinal fossae lie laterally to the lateral umbilical folds.

### **FASCIAE OF THE LOWER LIMB**

(see Figure 80, 85-86)

**The superficial fascia** is thin and resides under the skin enveloping the entire lower limb. It is a direct continuation of the superficial fascia of the abdomen.

**The proper fascia** is well developed and has different names depending on its location.

#### **Fasciae of the pelvic girdle**

In the region of the abdomen the iliopsoas muscle is covered by **the psoas fascia** and **the iliac fascia**, which are parts of the **endoabdominal fascia**. Both fasciae attach to the skeleton along the edges of the entire region, occupied by the iliopsoas muscle, and thus form a closed sheath for it. The iliac fascia along the iliac and passes under the inguinal ligament continuing into the deep layer of the fascia lata of the thigh. Under the inguinal ligament the iliac fascia thickens and forms the **iliopectineal arch**, which tightly fuses with the inguinal ligament laterally. Further, the arch extends medially, separates from the inguinal ligament, bridges over the iliopsoas muscle, and attaches to the iliopubic eminence. The iliopectineal arch divides the space under the inguinal ligament into **the vascular** (medially) and **muscular** (laterally) spaces.

**The gluteal fascia** is thin; it separates into several layers enclosing the gluteus maximus and deeper muscles of the gluteal region.

#### **The fascia of the thigh**

**The fascia lata** is the most well-developed fascia in the body. It invests the muscles of the thigh. Directly below the inguinal ligament, within the boundaries of the femoral triangle, the fascia divides into two layers: **deep** and **superficial**. The



former passes behind the vessels of the thigh. **The superficial layer** extends in front of the thigh vessels and lateral to the femoral vein and terminates as a free falciform margin. This margin bounds a depression called **the saphenous opening** (hiatus saphenus), which has an oval shape. Two "horns" are distinguished in the falciform margin. The great saphenous vein, draining into the femoral vein, overlaps the inferior horn (inferior cornu), which blends with the deep layer of fascia lata. The superior horn (superior cornu) attaches to the inguinal ligament and, curving under it, fuses with the lacunar ligament. The saphenous opening is covered by the **cribriform fascia**, which is a portion of the superficial layer of the fascia lata and bears openings for nerves and vessels.

The fascia lata, investing the muscles of the thigh, gives off processes which pass deeply between the muscles and are attached to the bone:

**The lateral femoral intermuscular septum** is attached to the lateral lip of the linea aspera of the femur and separates the vastus lateralis muscle from the biceps femoris muscle.

**The medial femoral intermuscular septum** is on the medial aspect of the thigh and attaches to the medial lip of the linea aspera. It passes between the vastus medialis muscle and adductors.

Less noticeable **posterior intermuscular septum** separates the adductors from the muscles of the posterior group.

As a result, three osteofibrous sheaths are formed on the thigh. The anterior sheath contains the quadriceps femoris, the medial sheath encloses the adductors, and the posterior sheath contains the flexors of the thigh.

The fascia lata is very thick, particularly on the lateral surface of the thigh, where tendinous fibres of the tensor fasciae latae and gluteus maximus muscles blend into it. Here it forms a wide thickened band, **the iliotibial tract**, extending for the entire length of the thigh from the ilium towards the lateral condyle of the tibia.

Distally, fascia lata extends to the anterior surface of the knee and is continuous with the fascia of the leg; posteriorly, it is continuous with fascia poplitea, covering the popliteal fossa and

representing an intermediate area between the fascia of the thigh and that of the leg.

### **Fasciae of the leg**

**The fascia of the leg** surrounds the leg and fuses with bones. On the posterior aspect of the leg, it consists of superficial and deep layers.

**The superficial layer** covers the triceps surae muscle, while the **deep layer** lies between this muscle and the deep posterior muscles and is attached to the tibia and fibula on the sides.

On the lateral side, fascia cruris gives off two intermuscular septa, which penetrate deeply and attach to the fibula.

**The anterior intermuscular septum** passes in front of the peroneal muscles separating them from the anterior muscle group.

**The posterior intermuscular septum** stretches behind the peroneal muscles and separates them from the posterior muscle group.

The intermuscular septa and fascial layers form three osteofibrous sheaths for three groups of muscles of the leg – anterior, posterior, and lateral.

In the region of the talocrural joint, the fascia of the leg forms the retinacula, located in the front, medially and laterally. The retinacula press the tendons of the muscles of the leg to the bones.

There are two retinacula in front:

**The superior extensor retinaculum** is a transverse band between the leg bones above their malleoli.

**The inferior extensor retinaculum** is located distally in front of the ankle joint. It originates from the lateral surface of the calcaneus and separates into two bands; the superior band passes to the medial malleolus, while the inferior attaches to the navicular and the medial cuneiform bones. Under each retinaculum, as a result of the formation of septa, three osteofibrous canals are formed. They contain the tendons of the muscles of the anterior group covered by the synovial sheath.

**The medial canal** transmits the tendon of the anterior tibial muscle. **The canal, next to it**, transmits the tendon of the extensor hallucis longus muscle, while the extreme **lateral canal** transmits the tendon of the extensor digitorum longus (and sometimes, the peroneus tertius)

muscle. The tendons, passing through the canals, are invested in synovial sheaths. The fourth canal, located behind the middle one, contains vessels. The synovial sheaths invest tendons where they pass deep to retinacula, extend onto the dorsal surface of the foot and reach the bases of the metatarsal bones. The sheath of the extensor hallucis longus is the longest one.

On the medial side, the thickening of the fascia of the leg forms **the flexor retinaculum**, which passes from the calcaneus to the medial malleolus over the tendons of deep muscles of the leg. The retinaculum gives rise to the septa that penetrate deeper and form three osteofibrous canals to transmit the muscular tendons, surrounded by the synovial sheaths. The canals are arranged in the following order (front to back): **the first** one transmits the tendon of the tibialis posterior; **the second** one contains the tendons of the flexor digitorum longus; **the third** one transmits the tendon of the flexor hallucis longus; and one fibrous canal that lies closer to the surface to transmit vessels. After passing the flexor retinaculum, the synovial sheaths extend onto the plantar surface of the foot and reach the bases of the metatarsal bones.

On the lateral side behind the lateral malleolus, there is a fascial thickening, **the superior fibular (peroneal) retinaculum**, stretching from the malleolus to the calcaneus over the tendons of the peroneus longus and brevis muscles, which lie under it in a common osteofibrous canal invested in a common synovial sheath. Both tendons pass under another retinaculum (distally and downward); **the inferior fibular (peroneal) retinaculum** is attached to the lateral surface of the calcaneus. The space under the inferior fibular retinaculum is divided by a septum into two canals, transmitting each tendon separately invested in the separate synovial sheath.

### Fasciae of the foot

**The dorsal fascia of the foot** consists of two layers – superficial and deep. **The superficial layer** is thin; it covers the tendons of the extensor digitorum longus and extensor hallucis longus muscles. **The deep layer** covers the dorsal interossei muscles and attaches to the metatarsal bones.

**The fascia of the sole of the foot** divides into two layers – superficial, or plantar aponeurosis, and deep. **The plantar aponeurosis** is a strong tendinous shining sheet, which covers the muscles of the sole and fuses with the flexor digitorum brevis. It stretches from the calcaneal tuberosity to the base of the toes. Toward the toes, the aponeurosis expands and separates into five slips between which the transverse fibres pass. These slips terminate on the fibrous sheaths of the tendons on the toes. Two vertical septa arise from the edges of the plantar aponeurosis, pass upward between the muscles, and are attached to the deep layer of the fascia of the sole covering the plantar interossei muscles. These septa divide the sole into three compartments which correspond, on the whole, to three groups of muscles of the sole (medial, middle, and lateral).

Several sheaths investing the tendons are found on the sole of the foot. **The synovial sheath of the peroneus longus muscle** is lodged deep in the sole around the tendon of this muscle, where the latter passes in the groove of the cuboid bone under the long plantar ligament. The other **five isolated fibrous sheaths** of the toes invest the flexor tendons in the plantar aspect of the toes and stretch from the region of the metatarsal heads to the distal phalanges forming the osteofibrous canals. The tendinous fibers of these sheaths consist of the annular and cruciate parts.

## TOPOGRAPHY OF THE LOWER LIMB

(see Figure 79, 81 – 84)

### The region of the pelvic girdle

The piriform muscle passes through the greater sciatic foramen, above and below which narrow openings (**the suprapiriform foramen and the infrapiriform foramen**) remain and transmit the gluteal vessels and nerves.

The obturator groove of the pubic bone is supplemented below by the obturator membrane and is thus converted to **the obturator canal**, providing a passage for the obturator vessels and nerves.

### The region of the thigh

**The inguinal ligament** runs over the hip bone from the superior anterior iliac spine to the pubic tubercle of the pubic bone and, in that way, bounds the space between the above named

bone and the ligament. Fascia iliaca, passing in this space, fuses in its lateral part with the inguinal ligament, while its medial portion diverges from the ligament, thickens and attaches to the iliopubic eminence. The part of this thickened band of fascia iliaca between the inguinal ligament and the iliopubic eminence is distinguished under the name of **the iliopectineal arch**. It divides the entire space below the inguinal ligament into two parts: a lateral, **muscular space**, lodging the iliopsoas muscle and the femoral nerve, and a medial, **vascular space**, for passage of the femoral artery and vein (the latter passes medially).

**The muscular space** is bounded: medially – by the iliopectineal arch; in front and above – by the inguinal ligament; laterally and in the back – by the ilium.

**The vascular space** is bounded: in front and above – by the inguinal ligament; posteriorly – by the pectineal ligament; laterally – by the iliopectineal arch; medially – by the lacunar ligament (the lacunar ligament and the pectineal ligament are the derivatives of the inguinal ligament).

**The femoral ring** is the narrow opening in the medial corner of the vascular space. The ring is bounded: laterally – by the femoral vein; anteriorly and superiorly – by the inguinal ligament; medially – by the lacunar ligament; and posteriorly – by the pectineal ligament.

The femoral ring is covered by a thin layer of fascia, the femoral septum, and by the peritoneum inside. Outside, it is covered by a small lymph node.

### **The femoral canal**

Under normal conditions the femoral canal is absent, but the femoral ring is a weak spot, which can serve as an exit for the femoral hernia. When the hernia passes through, the femoral canal is formed. The internal aperture of the femoral canal is the femoral ring. The outlet, or external opening, is the saphenous hiatus, bounded by the falciform margin and its superior and inferior horns. The space between the openings is **the femoral canal**, which has three walls: **lateral**, formed by the femoral vein; **posterior**, formed by the deep layer of fascia lata; and the **anterior** wall, formed by the inguinal ligament and the superior horn of the falciform margin of the fascia lata. The

latter is loosened in the saphenous hiatus and perforated by lymph vessels and great saphenous vein, and is called cribriform fascia. Loosening of fascia lata in the saphenous hiatus is responsible for the protrusion of a femoral hernia just in this place. The femoral hernias occur more frequently in women due to greater width of the pelvis.

According to the passage of the vessels and nerves, the following grooves and canals are distinguished on the thigh:

**The femoral triangle (Scarpa's triangle)** resides on the anterior surface of the thigh containing the main neurovascular bundle and lymph nodes. It is bounded by the inguinal ligament superiorly (the base of the triangle), the sartorius muscle laterally, and the adductor longus muscle medially. The floor of the triangle, called iliopectineal fossa, is formed by the iliopsoas and pectineus muscles.

**The iliopectineal groove**, with which the vascular space is continuous, lies between the iliopsoas (laterally) and the pectineus muscles (medially) and is then, in turn, continuous with anterior femoral groove.

**The anterior femoral groove** is formed by the vastus medialis (laterally) and the adductor longus and magnus muscles (medially).

Downward, facing the apex of the triangle, the anterior femoral groove leaves it between the muscles and transforms into a canal, **the adductor canal (Hunter's canal)**, passing on the lower third of the thigh into the popliteal fossa. The canal is formed by the vastus medialis (laterally), the adductor magnus muscle (medially), and the tendinous plate, lamina vastoadductoria, running over them (anteriorly). The distal foramen of the adductor canal, called **adductor hiatus**, is formed by the diverging bundles of the adductor magnus muscle; it opens into the popliteal fossa. The canal transmits the femoral vessels and saphenous nerve. The nerve leaves the canal via **the anterior opening**, which resides in the lower part of the lamina vastoadductoria.

### **The region of the leg**

**The popliteal fossa** resides in the back on the border between the thigh and the leg. It is shaped like a rhomb. **The superior angle** of the rhomb is formed by the biceps femoris muscle laterally and

by the semimembranosus and semitendinosus muscles medially. **The inferior angle** is bounded by the heads of the gastrocnemius muscle. The floor of the fossa (anterior wall) is formed by the popliteal surface of the femur and the capsule of the knee joint. The popliteal fossa contains fatty tissue with lymph nodes. From the superior to the inferior angle the terminal branches of the sciatic nerve, the popliteal artery and the vein pass in the following order (from the surface and deeper): nerve, vein, artery.

**The cruropopliteal canal (Gruber's canal)** extends between the superficial and the deep layers of the posterior leg muscles and is mainly formed by the tibialis posterior (anteriorly) and the soleus (posteriorly). It provides a passage for the tibial nerve, the posterior tibial artery and vein. The canal has three openings – superior, inferior, and anterior. **The superior opening** of the canal is bounded by the popliteus muscle in front and by the tendinous arch of the soleus in the back.

**The inferior opening** resides between the tibialis posterior and soleus muscles on the medial margin of the Achilles tendon. **The anterior**

**opening** is located in the upper part of the interosseous membrane of the leg.

**The inferior musculo-peroneal canal** is a branch of the cruropopliteal canal in the lateral direction. Its walls are formed by the posterior surface of the fibula (anteriorly) and the flexor hallucis longus muscle (posteriorly). The canal transmits the peroneal (fibular) vessels.

**The superior musculo-peroneal canal** is an independent canal in the upper third of the leg between the lateral surface of the fibula and the peroneus (fibular) longus muscle. The superficial peroneal nerve passes in it.

### **The region of the foot**

In line with the course of the plantar vessels and nerves, two grooves are found on the sole along the edges of the flexor digitorum brevis muscle:

- a **medial plantar groove** is between the above-indicated muscle and the abductor hallucis muscle;
- a **lateral plantar groove** is between the same flexor and the abductor digiti minimi muscle.

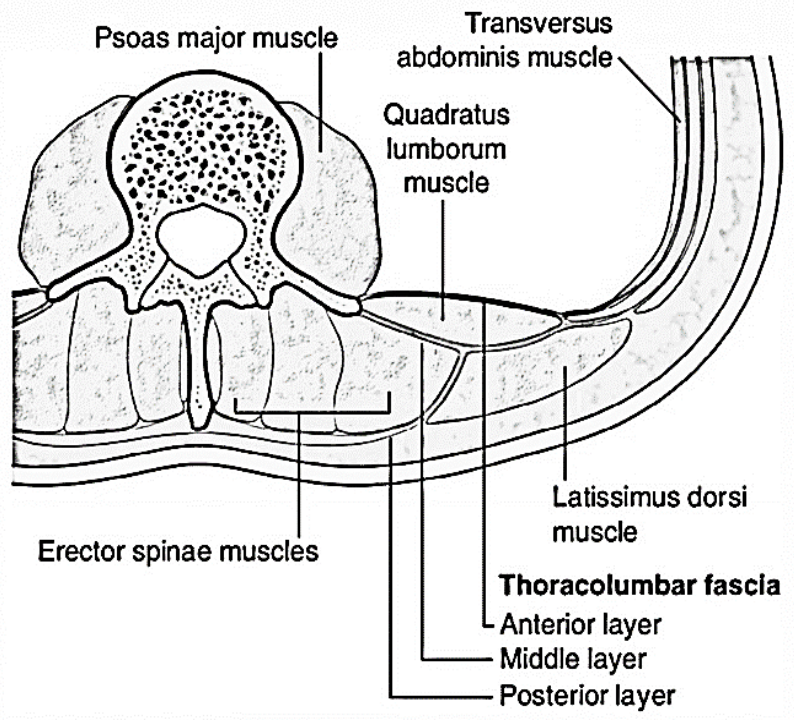
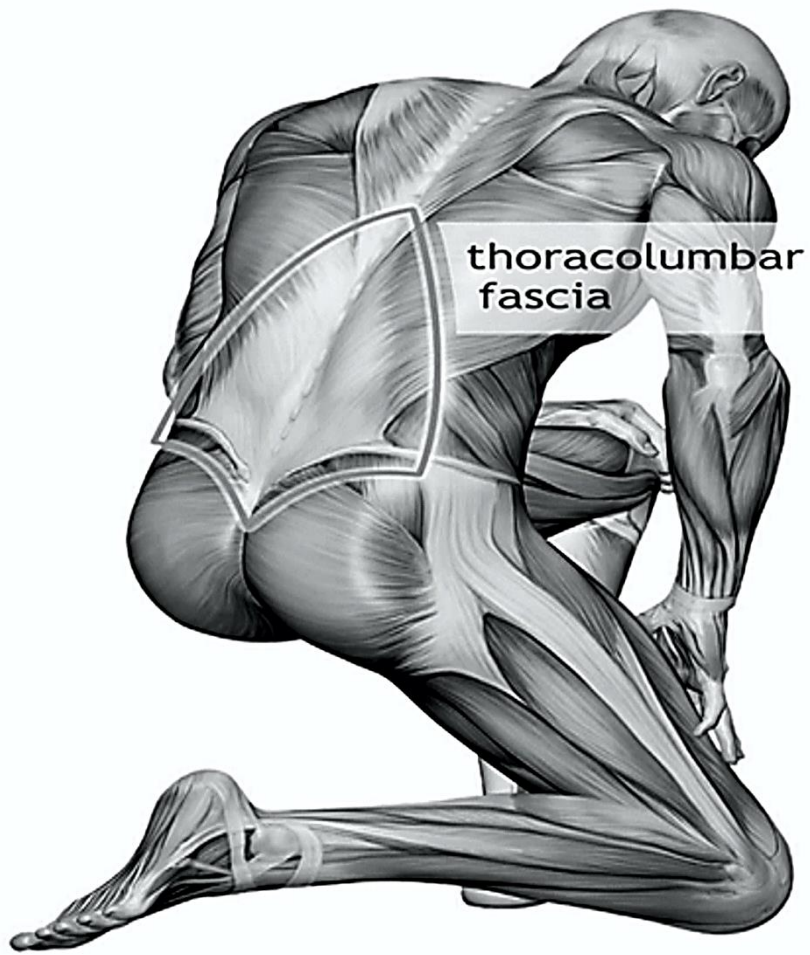


Figure 64 – Layers of thoracolumbar fascia

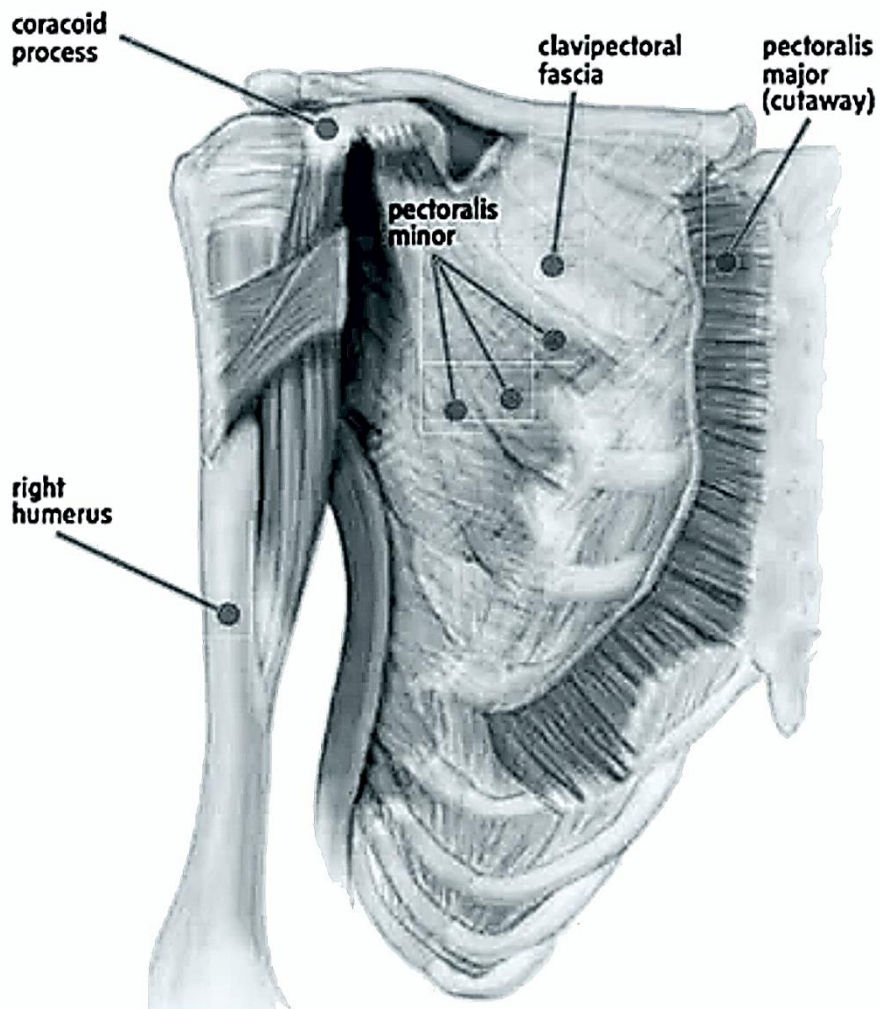
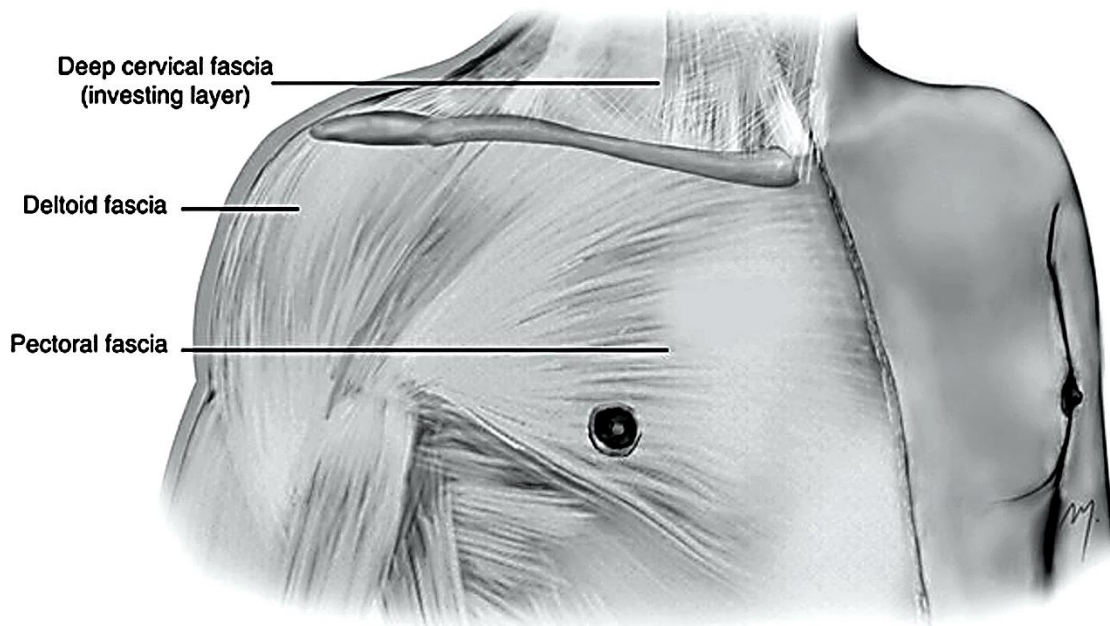
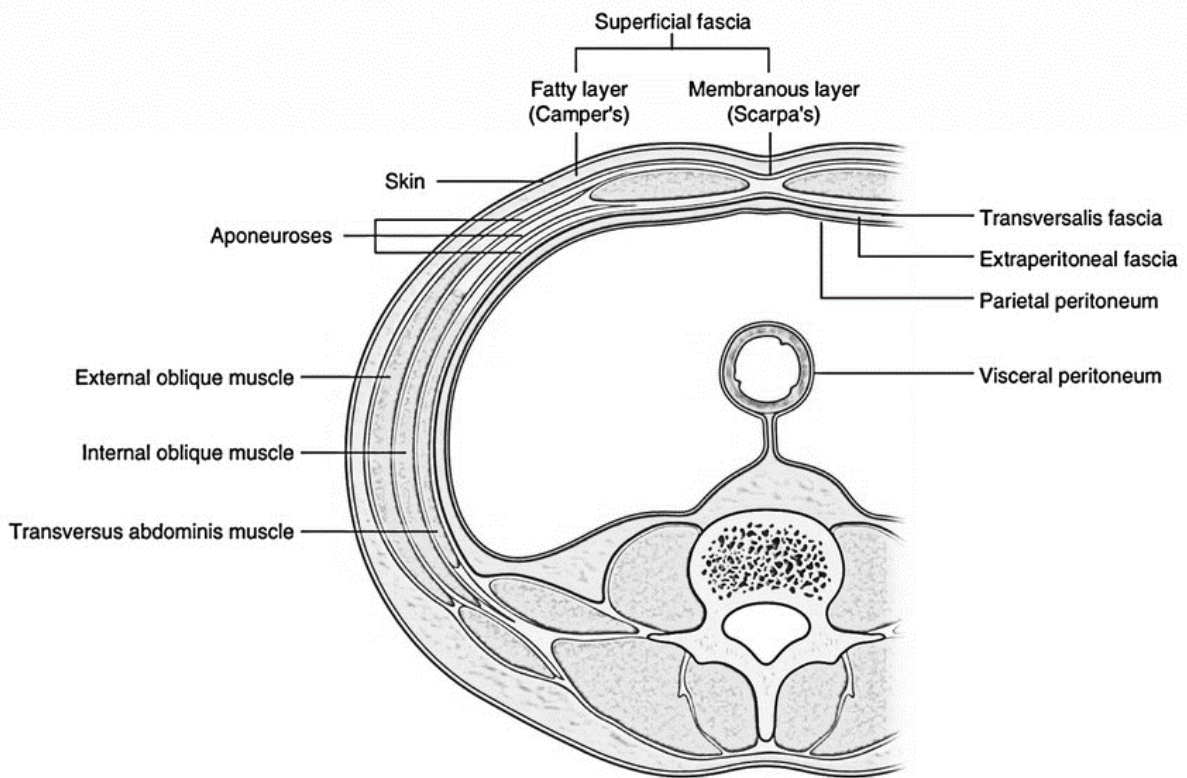
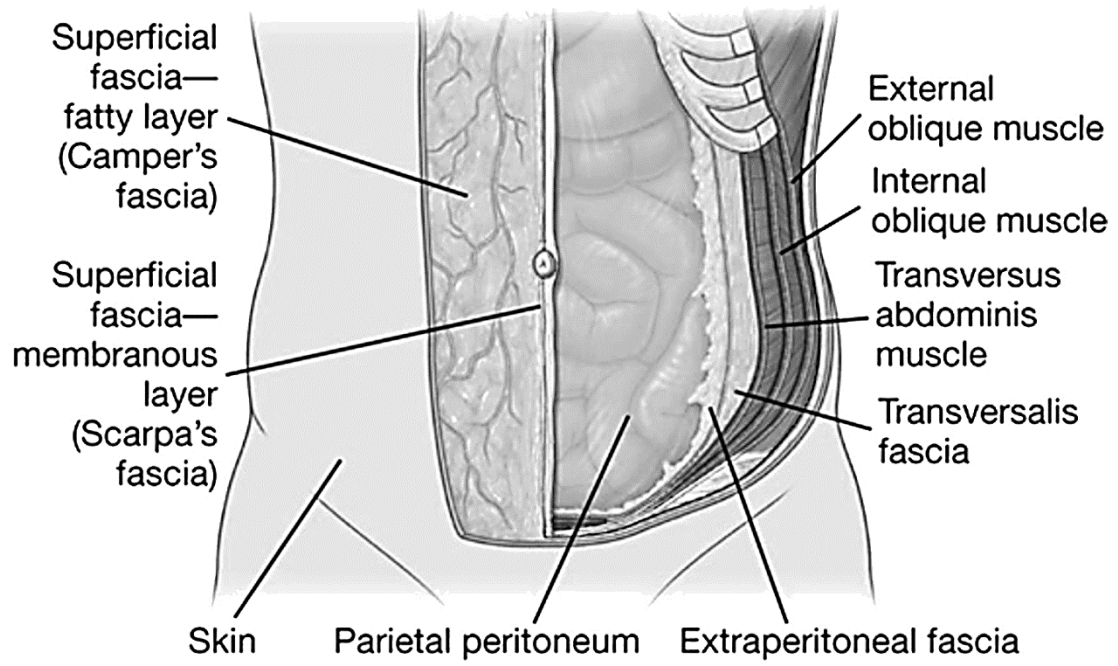


Figure 65 – The pectoral and clavipectoral fascia of the chest



**Figure 66 – The fasciae of the abdomen**

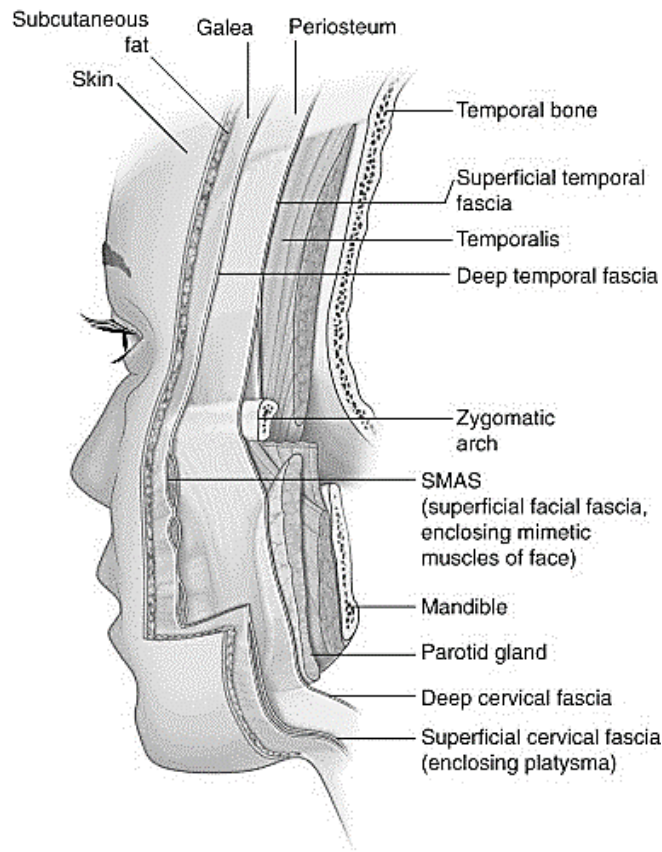


Figure 67 – The fasciae of the head

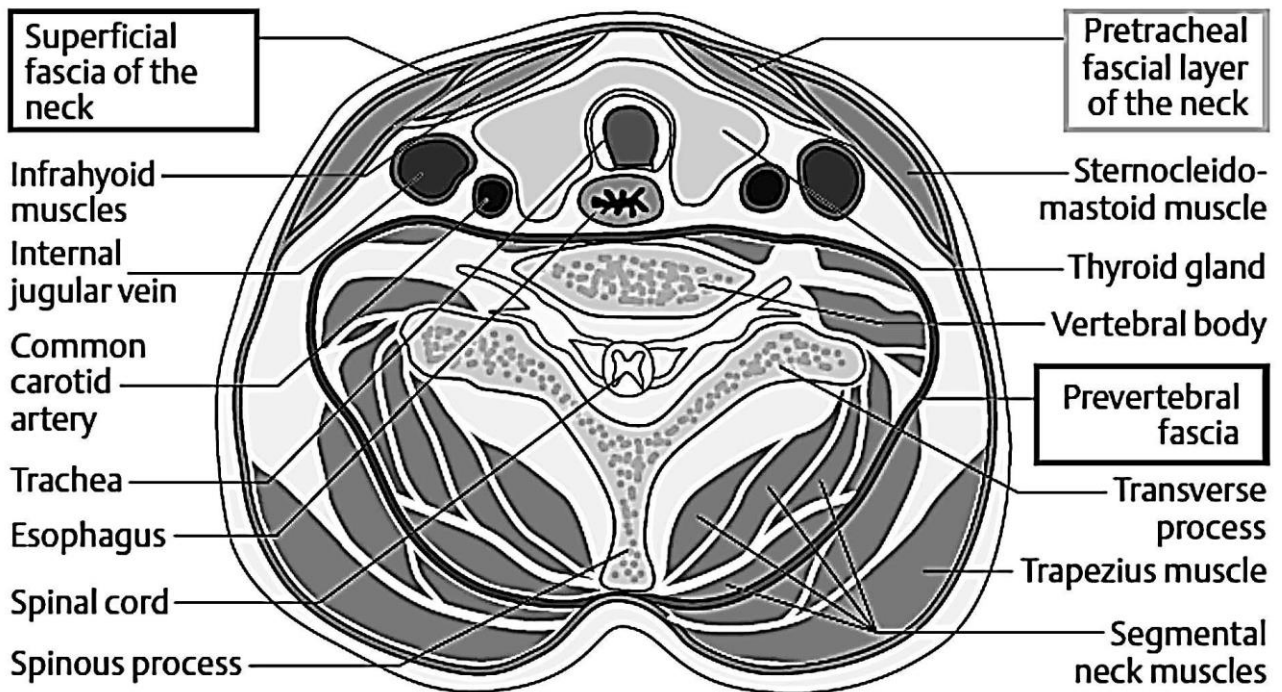
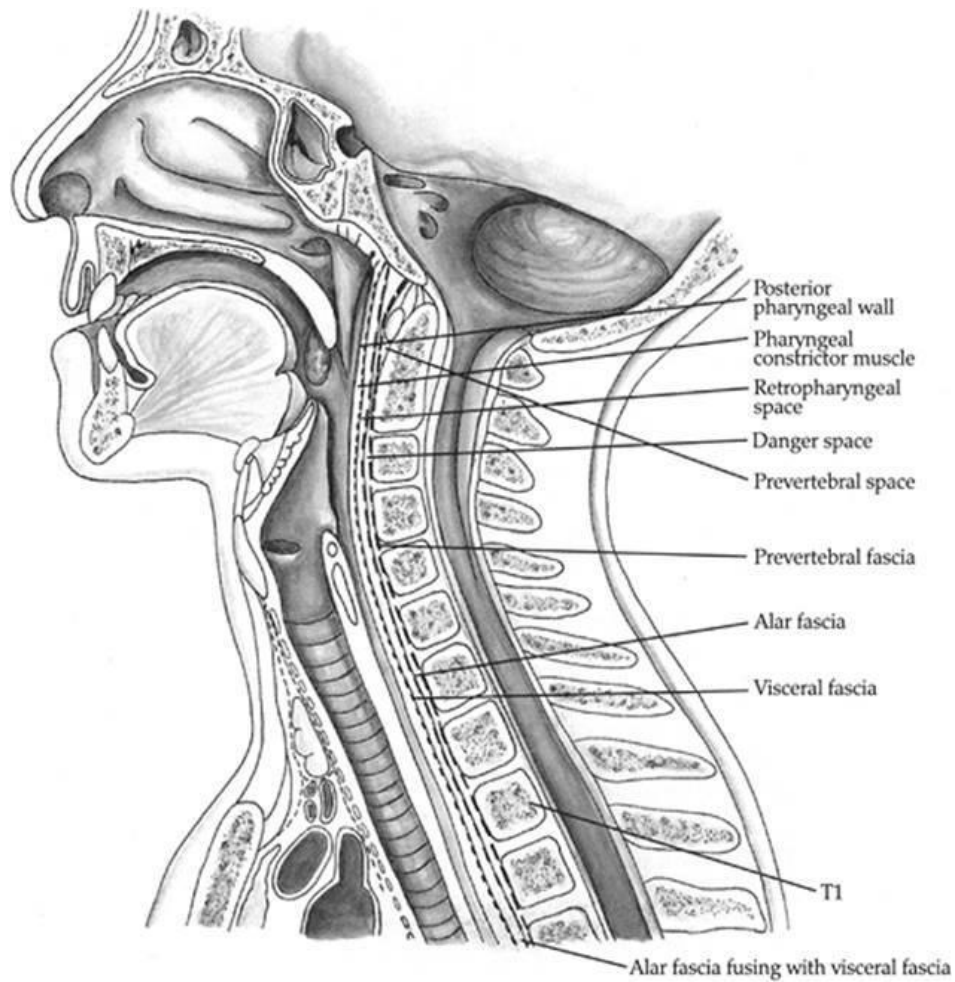
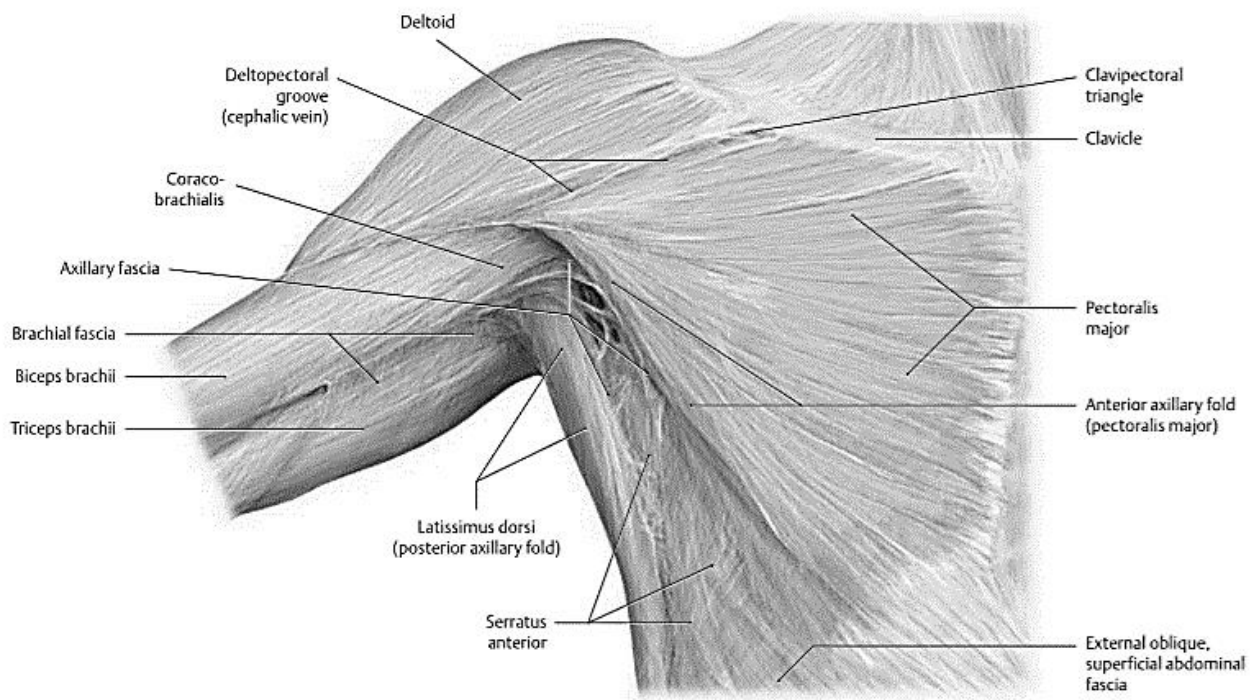


Figure 68 – Horizontal section of the neck at the level of thyroid gland





**Figure 69 – Sagittal section of the head and neck**



**Figure 70 – The axillary fascia**

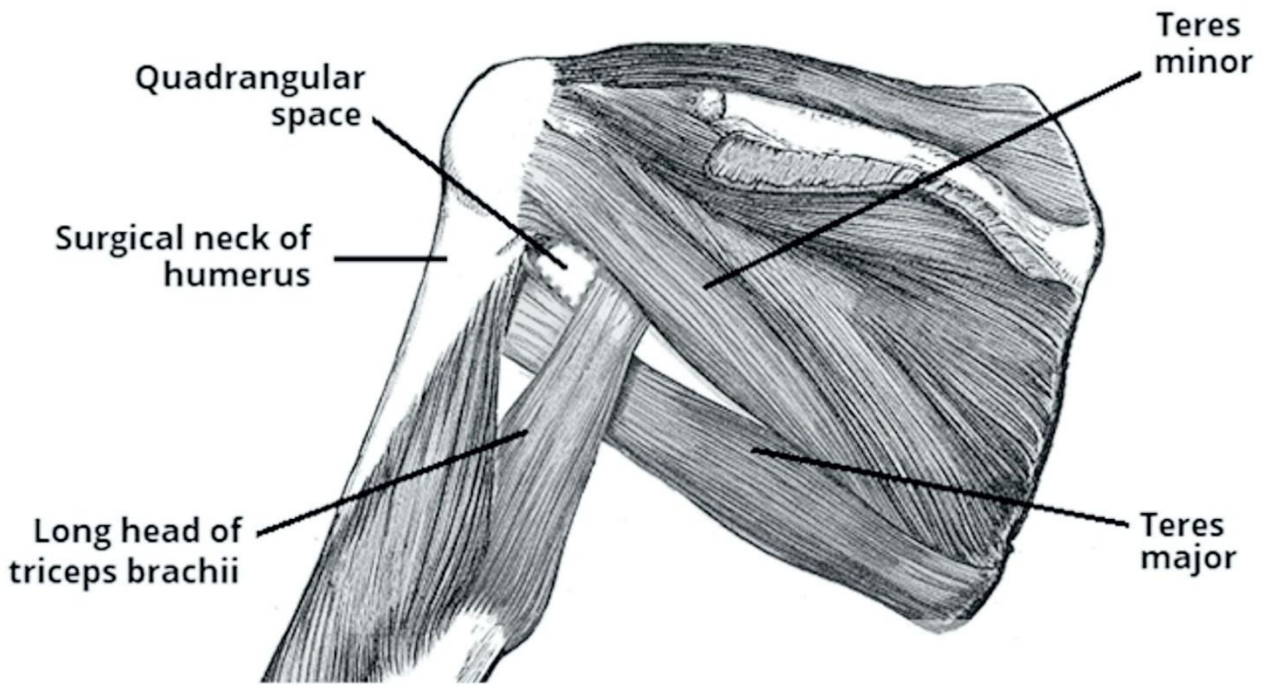


Figure 71 – Openings of the axillary cavity

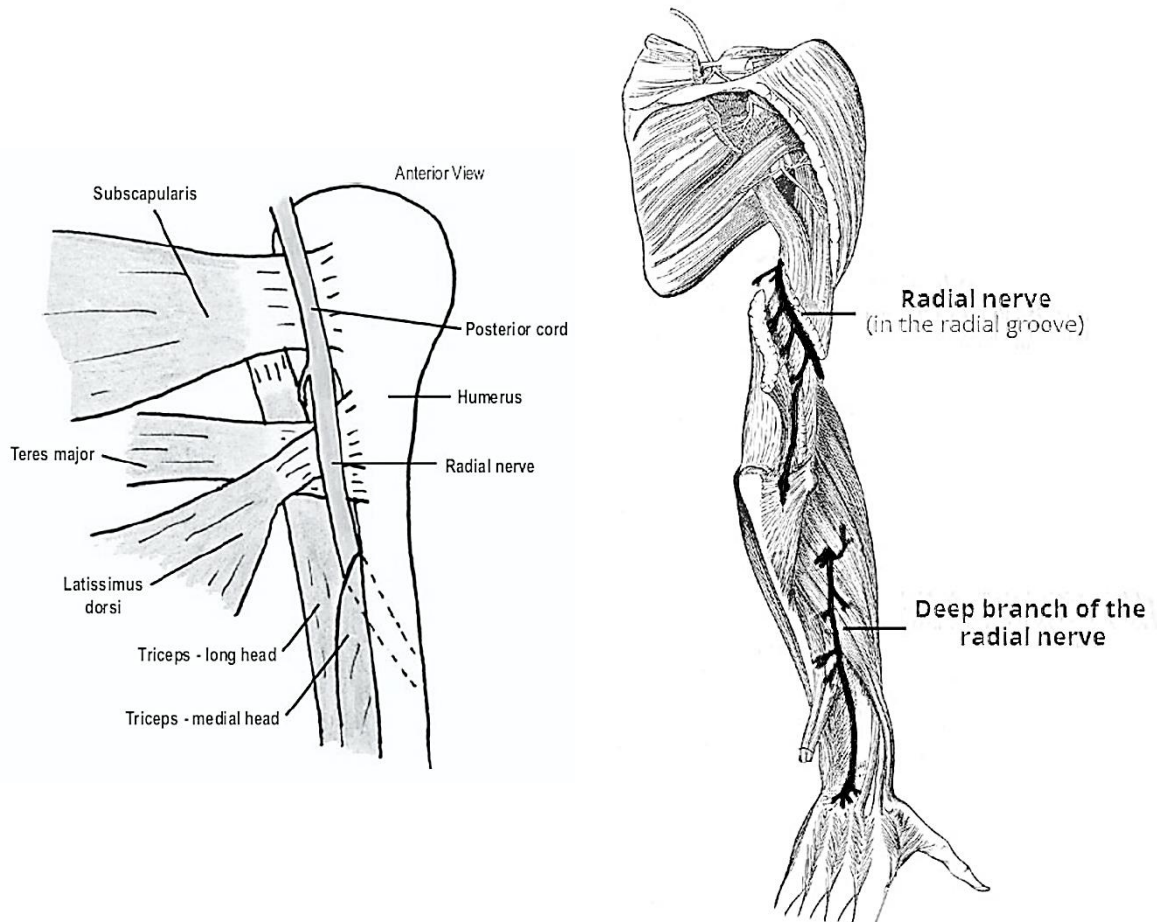
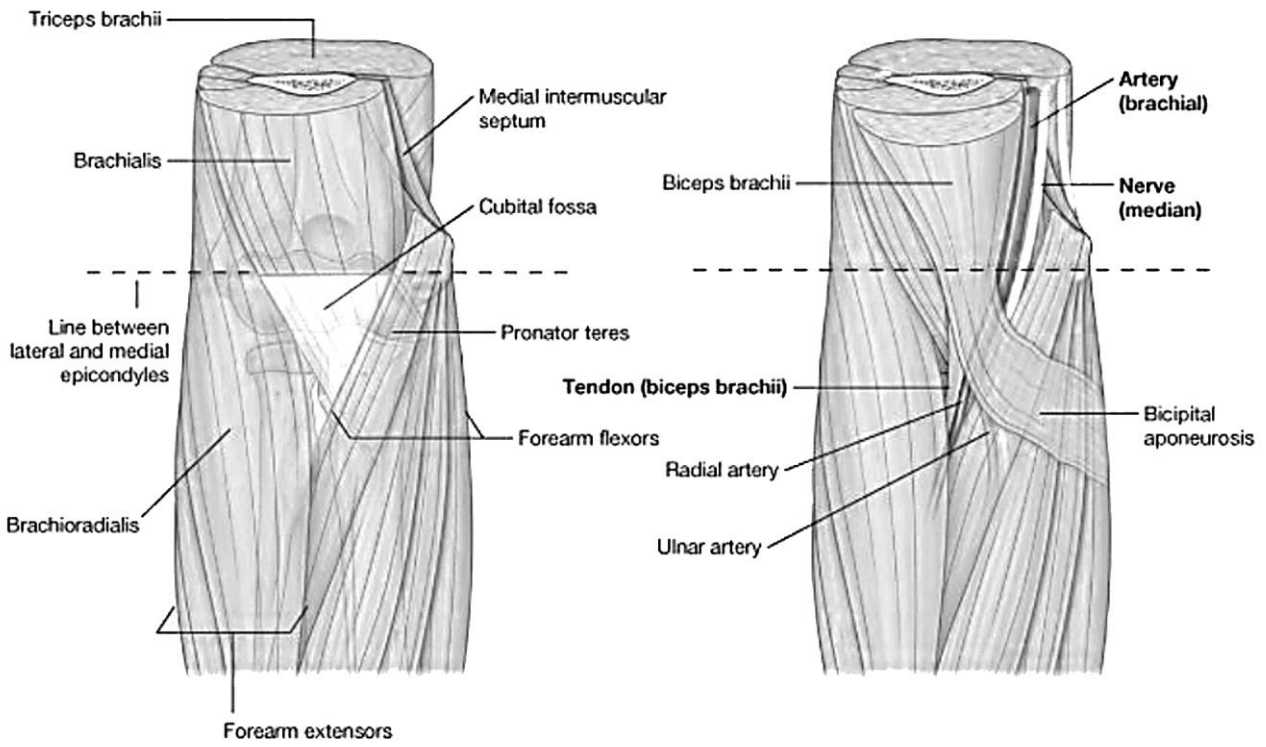
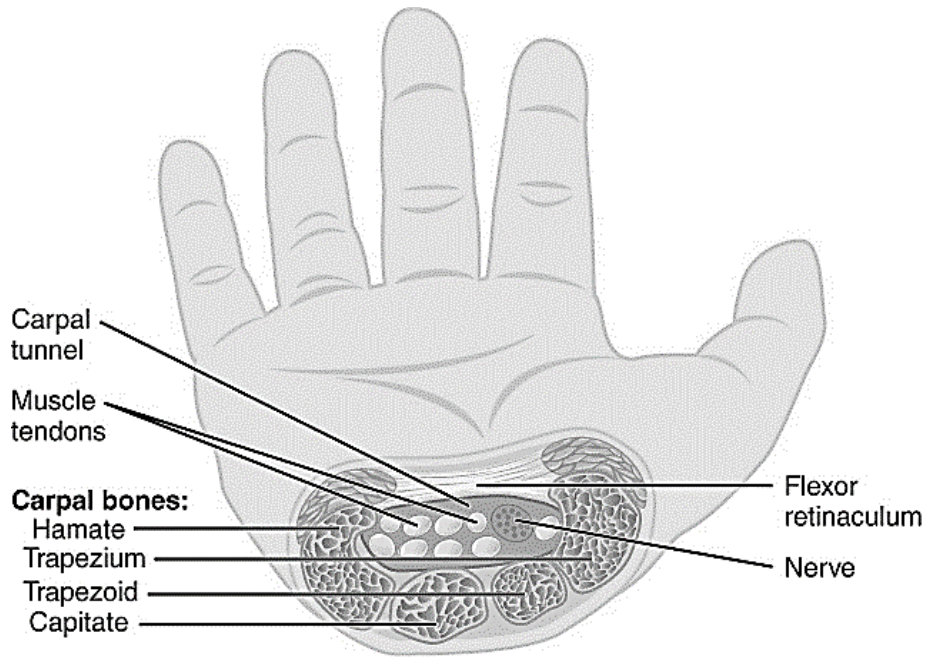


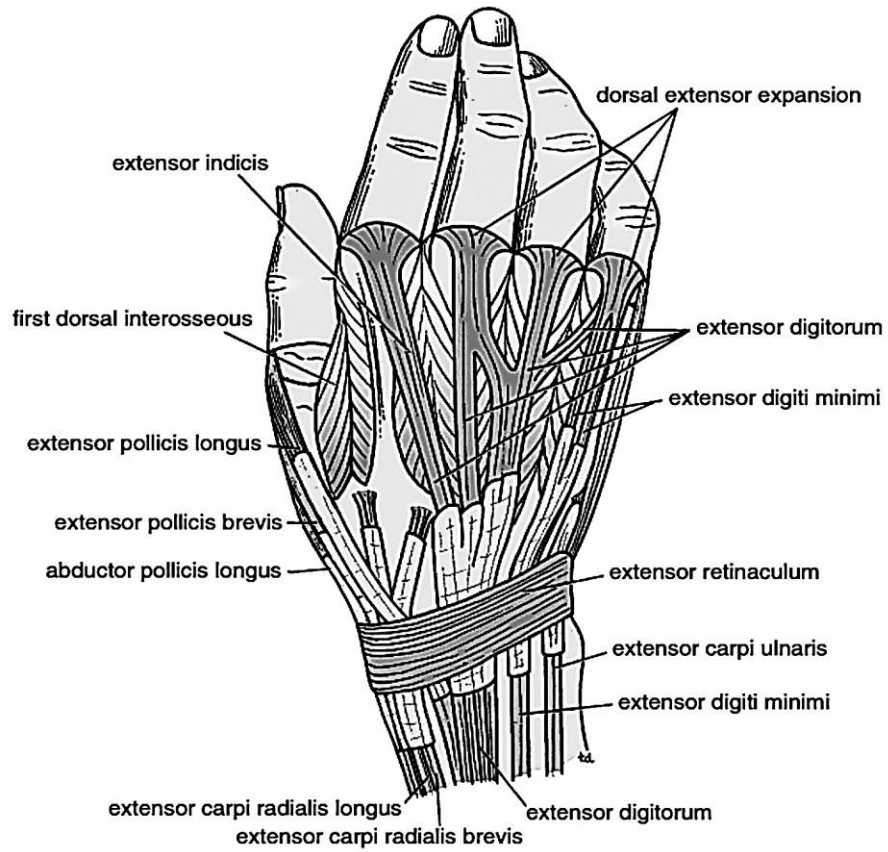
Figure 72 – Radial canal



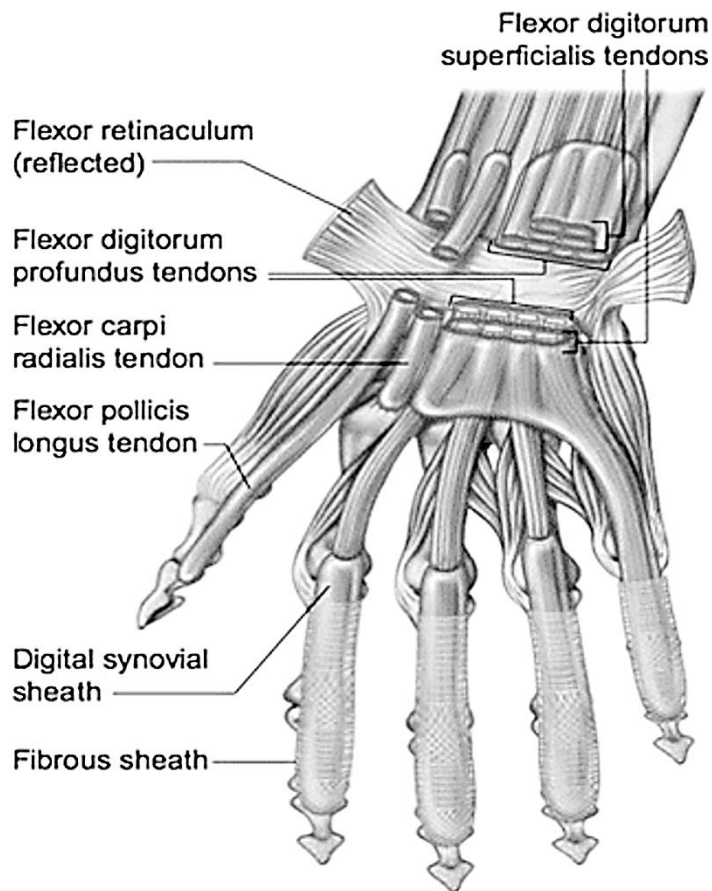
**Figure 73 – The cubital fossa**



**Figure 74 – The carpal canal**



**Figure 75 – Dorsal surface of the hand showing the long extensor tendons and their synovial sheaths**



**Figure 76 – The tendineous sheaths of the flexors**

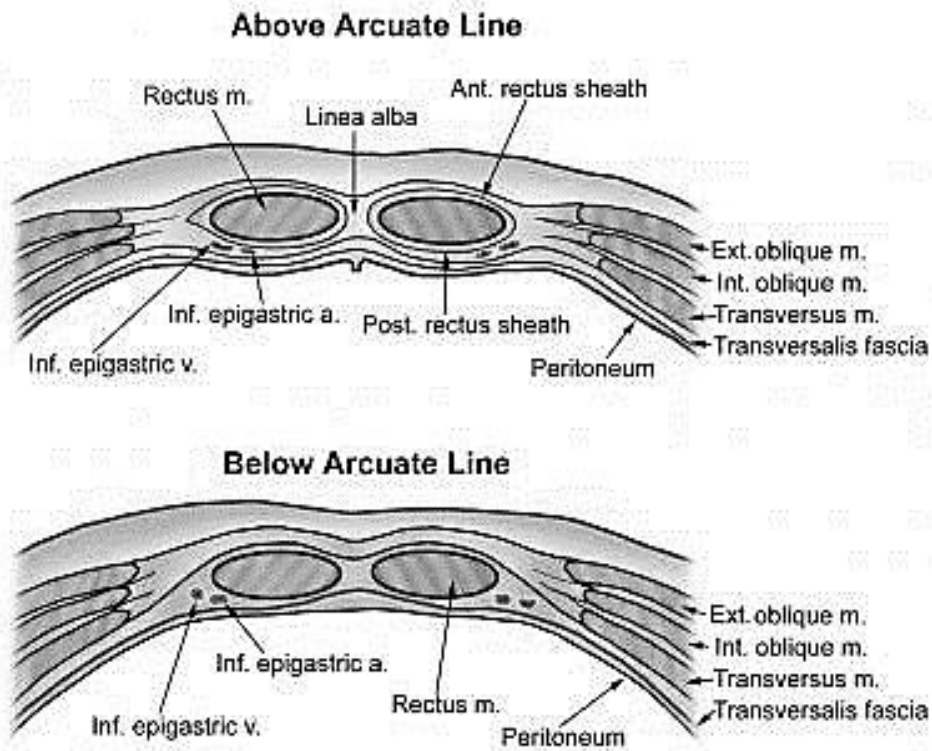


Figure 77 – The rectus sheath

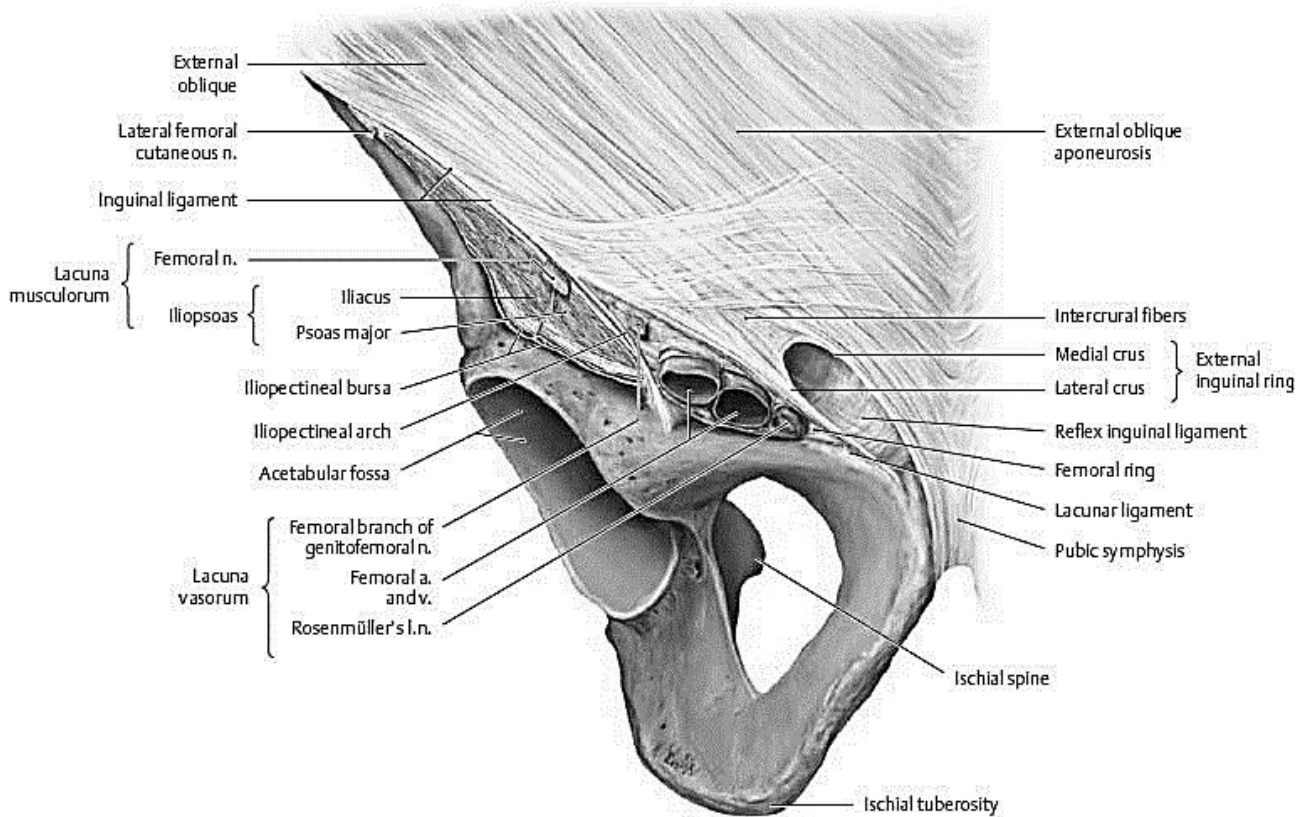
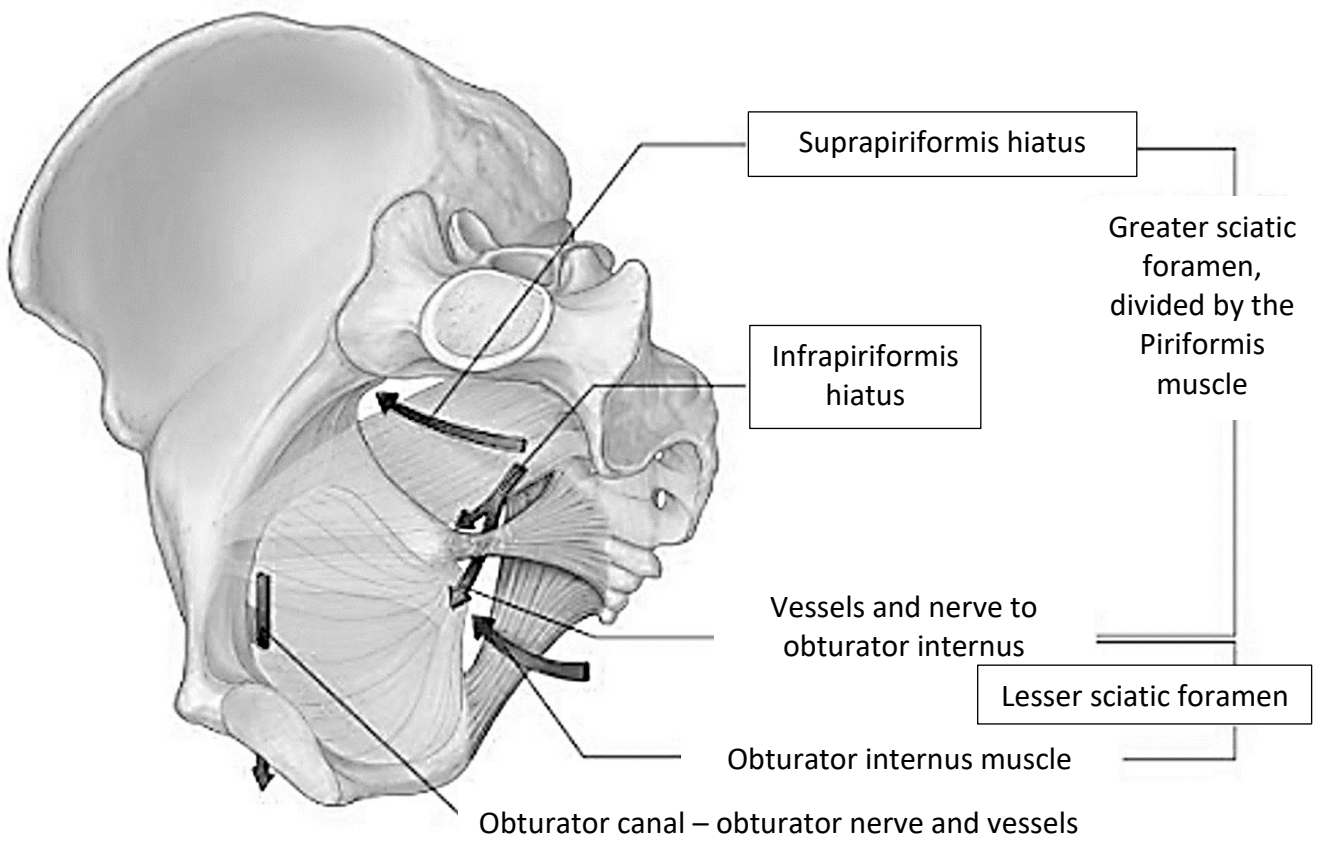
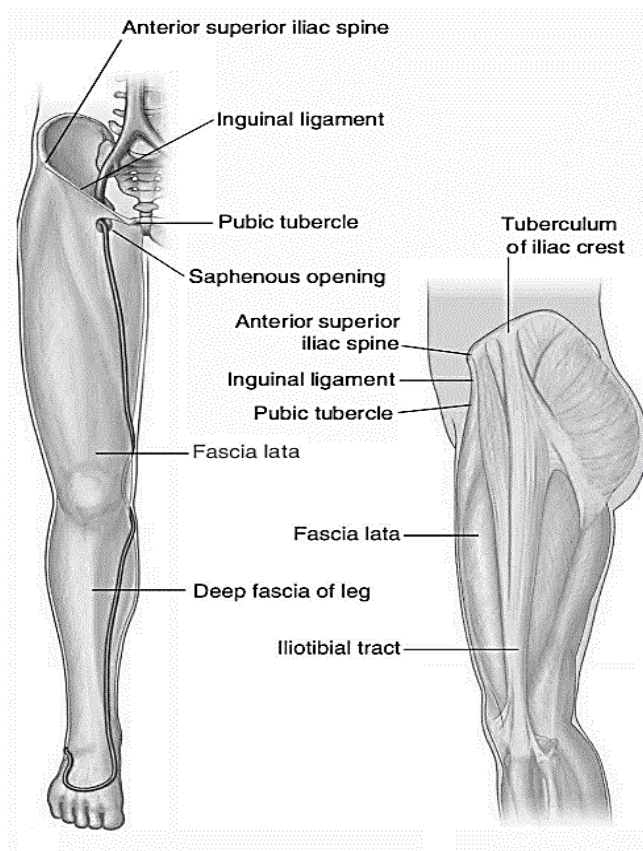


Figure 78 – The right inguinal region, anterior aspect



**Figure 79 – The topography of the region of the pelvic girdle**



**Figure 80 – The fascia lata**

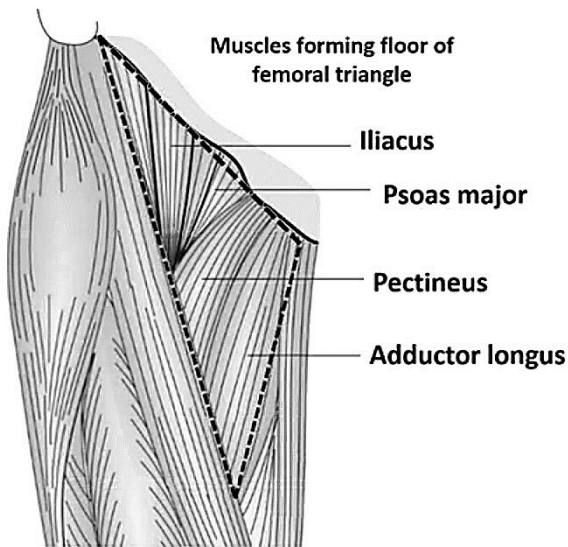


Figure 81 – The femoral triangle

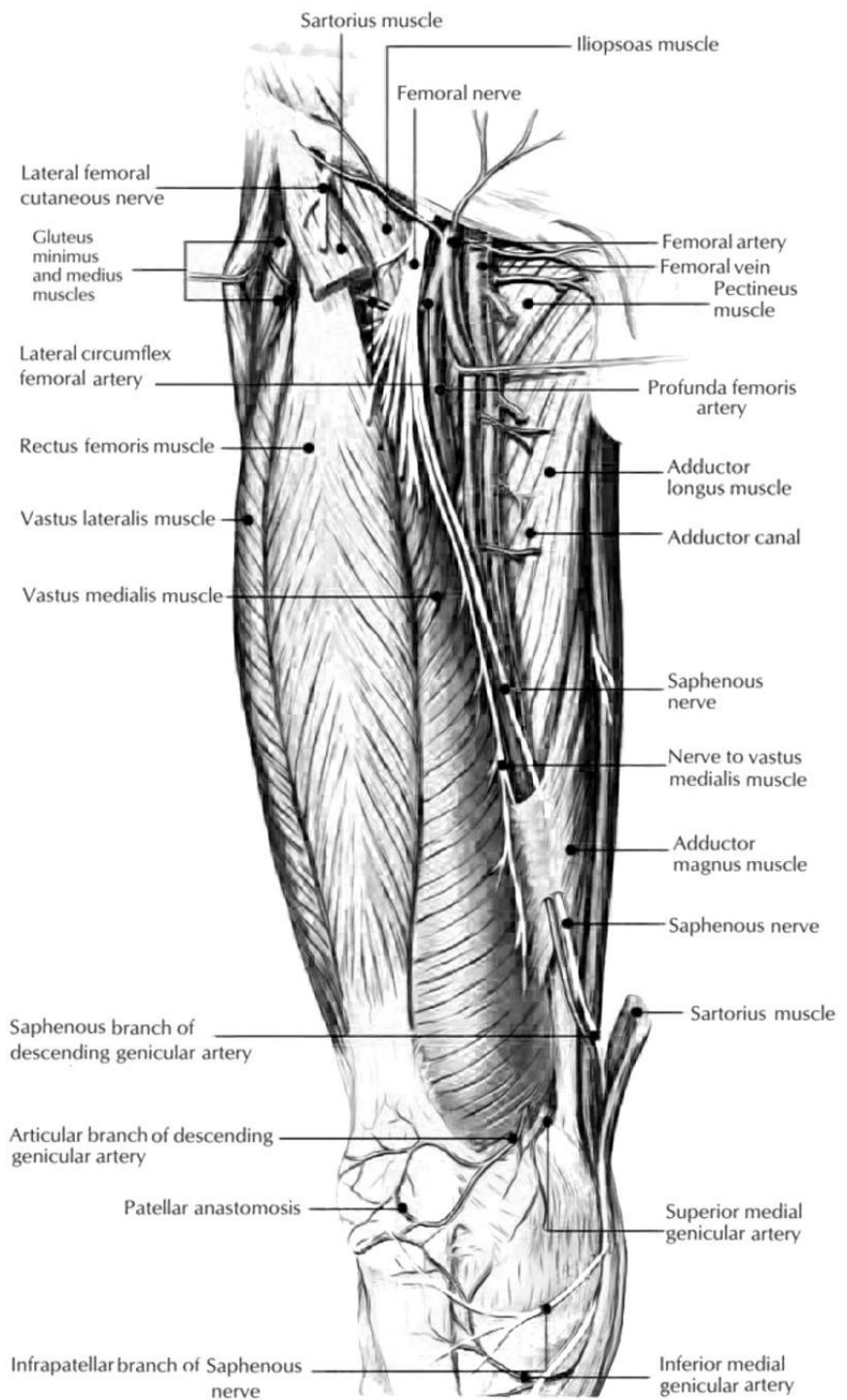


Figure 82 – The adductor canal

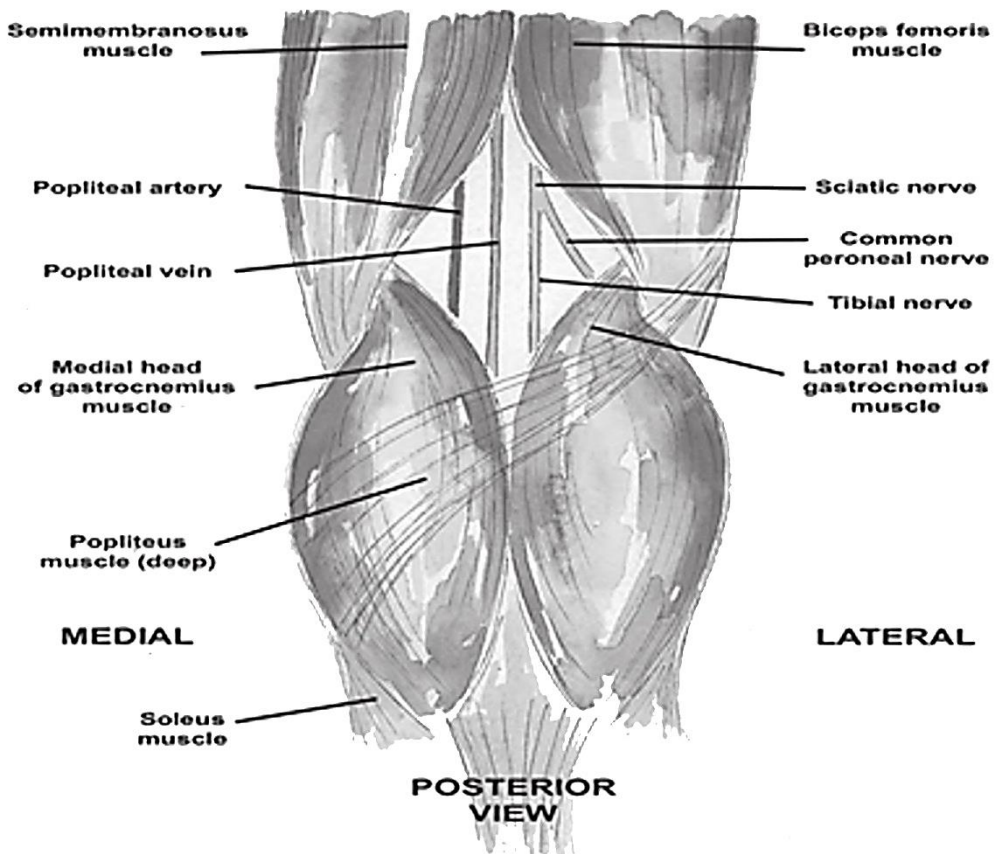


Figure 83 – The popliteal fossa

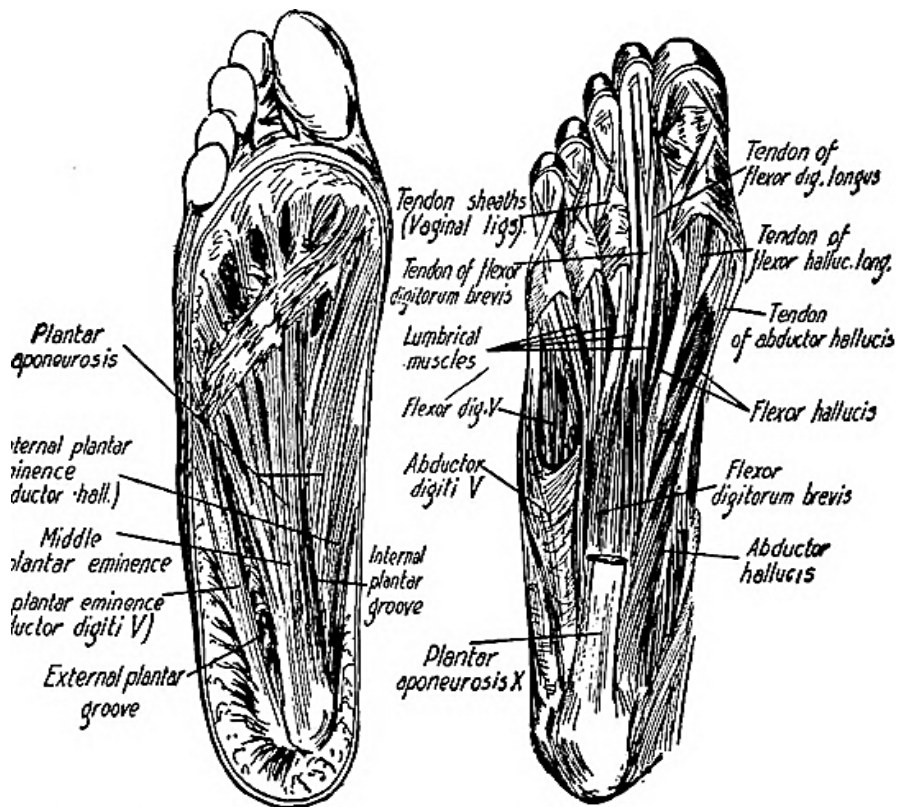
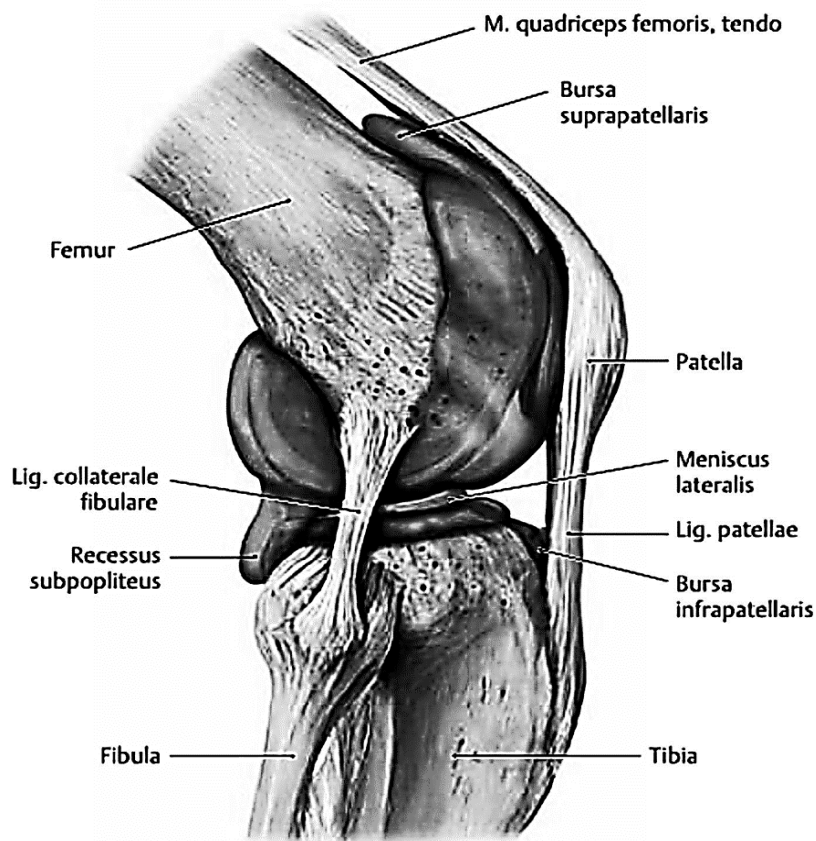
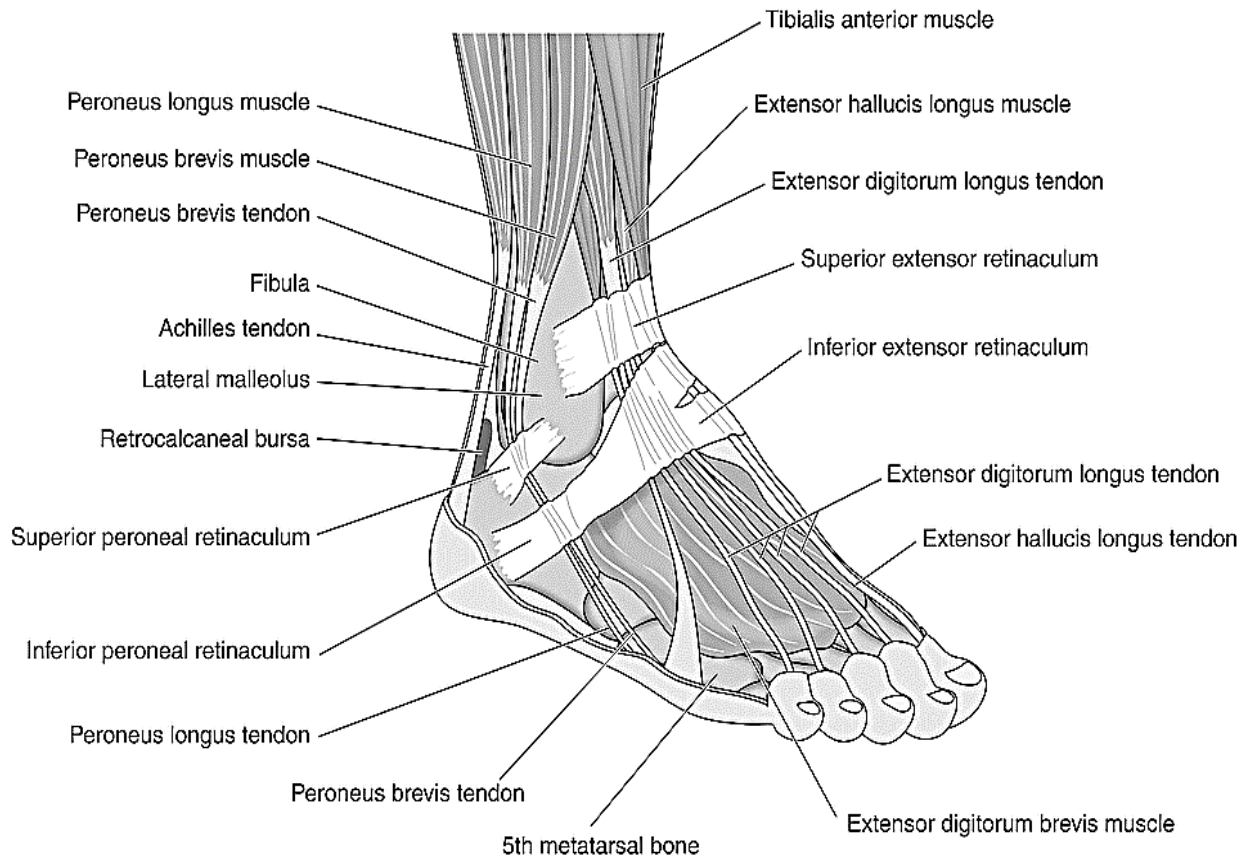


Figure 84 – The lateral and medial plantar grooves





**Figure 85 – Cavitas articularis, right knee, lateral view**



**Figure 86 – The retinacula of the leg**

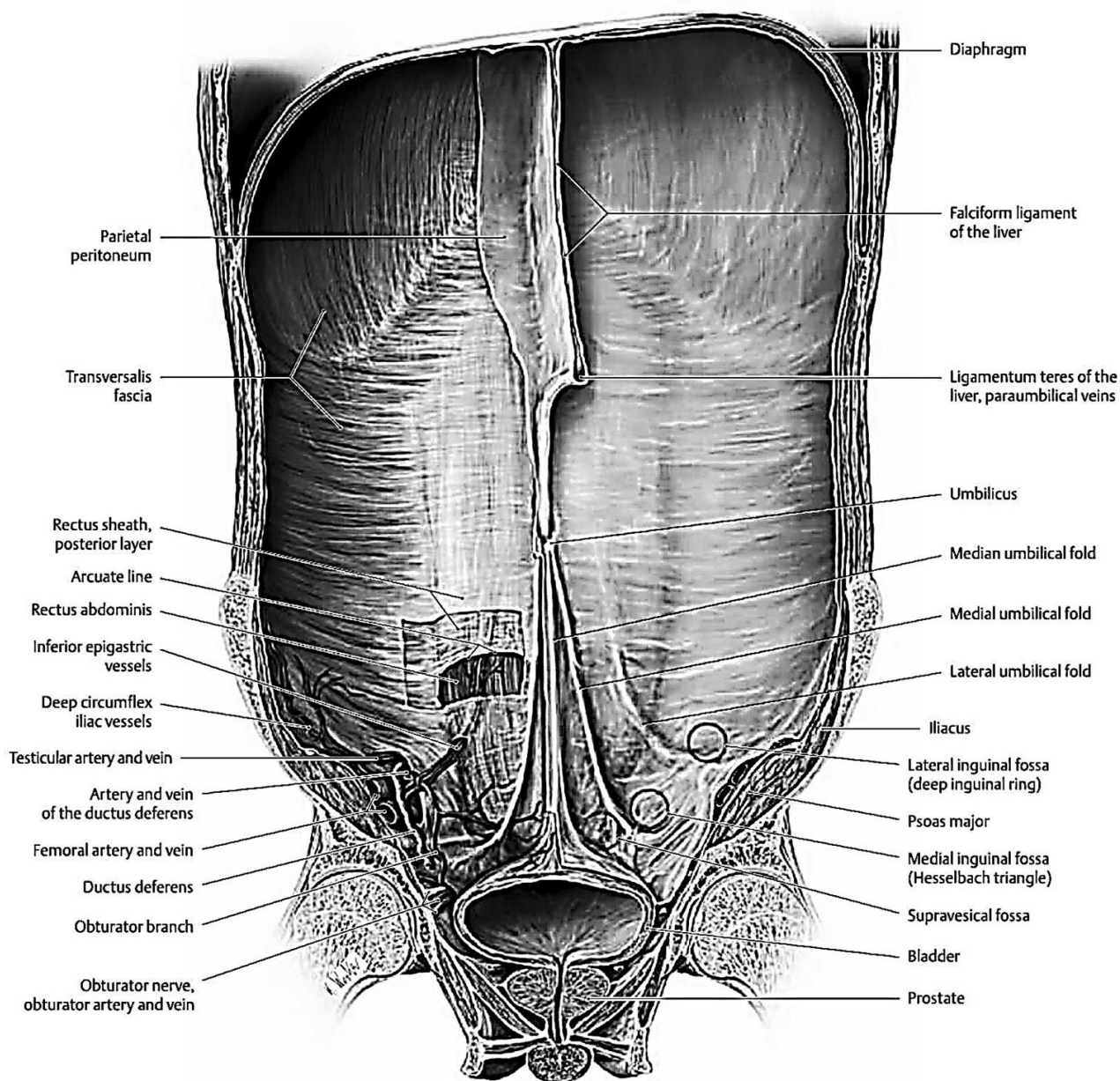


Figure 87 – Anterior abdominal wall, internal view

## TEST QUESTIONS (COMPUTER)

### **What parts are distinguished in a typical vertebra:**

- + the body and the arch with processes;
- only the body;
- the arch without processes;
- the body and processes?

### **What limits the vertebral foramen:**

- + a vertebral arch and posterior surface of the vertebral body;
- a vertebral arch and anterior surface of the vertebral body;
- vertebral processes;
- a vertebral arch and processes?

### **What do all vertebral foramina form:**

- + the vertebral canal;
- the spinal canal;
- an intervertebral foramina;
- a nutrition foramina?

### **What limits the intervertebral foramen:**

- + superior and inferior incisures of the adjacent vertebrae;
- vertebral foramina of all vertebrae;
- medial and lateral incisures of the adjacent vertebrae;
- the body and the arch of one vertebra?

### **What unpaired vertebral processes do you know:**

- + a spinous process;
- a transverse process;
- an articular process;
- a medial process?

### **What paired vertebral processes do you know:**

- + transverse and articular;
- transverse and spinous;
- medial and lateral;
- medial and transverse?

### **What are basic features of the cervical vertebrae:**

- + a foramen in transverse process;
- a foramen in articular process;
- absence of processes;
- absence of the body?

### **What typical structure is absent in the atlas:**

- + the body, articular and spinous processes;
- a vertebral foramen;
- transverse processes;
- the body and transverse processes.

### **How is the first vertebra called:**

- + atlas;
- axis;
- prominence;
- transverse.

### **What arches are distinguished in the atlas:**

- + anterior and posterior;
- inferior and superior;
- medial and lateral;
- only posterior?

### **How is the second vertebra called:**

- + axis;
- atlas;
- prominence;
- transverse?

### **What are basic features of the thoracic vertebrae:**

- + the costal facets of the body and of the transverse processes;
- foramina of the transverse processes;
- the costal facets of the body and foramina of the transverse processes;
- the costal facets and foramen of the transverse processes?

### **What is characteristic of the transverse processes of the thoracic vertebrae:**

- + they are well-developed, turned backwards and have costal facets;
- they are well-developed and have a foramen;
- they are well-developed, turned backwards and have a foramen;
- they are well-developed, have costal facets and a foramen?

### **What thoracic vertebrae do not have costal facets of transverse process:**

- + the 11th and the 12th;
- the 1st and the 12th;

- the 1st and 11th;
- the 10th, the 11th and the 12th?

**What parts has the vertebral column:**

- + cervical, thoracic, lumbal, sacral and coccygeal;
- cervical, costal and coccygeal;
- cervical, thoracic, pelvic and coccygeal;
- cervical, scapular, sacral and coccygeal?

**How many vertebrae has the cervical part of the vertebral column:**

- + 7;
- 12;
- 5;
- 8?

**How many vertebrae has the thoracic part of the vertebral column:**

- + 2;
- 7;
- 5;
- 8?

**Theme 3. The lumbar vertebrae and their features. Sacrum. Coccyx. Bones of the thorax**

**What are basic features of the lumbar vertebrae:**

- + a large body, the accessory and mammillary processes;
- a large body and foramen in transverse processes;
- a large body and costal processes;
- a large body and absence of transverse processes?

**Where is the mammillary process located:**

- + on the superior articular process;
- on the spinous process;
- on the inferior articular process;
- on the transverse process?

**Where is the accessory process located:**

- + on the transverse process;
- on the anterior portion of the base of transverse process;
- on the spinous process;
- on the inferior process?

**How many vertebrae has the sacral part of the vertebral column:**

- + 5;
- 7;
- 12;
- 3 – 4?

**How many vertebrae has the lumbar region of the vertebral column:**

- + 5;
- 7;
- 12;
- 3–4?

**How many vertebrae has the coccygeal part of the vertebral column:**

- + 3–5;
- 7;
- 12;
- 1?

**What shape has the sacrum:**

- + triangular;
- cube;
- oval;
- circle?

**What surfaces has the sacrum:**

- + anterior (ventral) and posterior (dorsal);
- medial and lateral;
- superior and inferior;
- Superior, inferior, posterior and inferior?

**What parts has the sacrum:**

- + the base, the apex and lateral parts;
- the body and processes;
- the base, the body and processes;
- the base, the apex and the arch with processes?

**How is the anterior surface of the sacrum called:**

- + pelvic;
- dorsal;
- medial;
- superior?

**What anatomical structures are located on the pelvic surface of the sacrum:**

- + the transverse line and anterior sacral foramina;

- the vertical line and anterior sacral foramina;
- the transverse line, superior and inferior sacral foramina;
- the transverse line and posterior sacral foramina?

***How is a posterior surface of the sacrum called:***

- + dorsal;
- pelvic;
- medial;
- superior?

***What anatomical structures are located on the dorsal surface of the sacrum:***

- + posterior sacral foramina and 5 crests;
- posterior sacral foramina and 2 crests;
- anterior sacral foramina and 5 crests;
- posterior sacral foramina and 7 crests?

***What crests are located on the dorsal surface of the sacrum:***

- + median, two intermediate and two lateral;
- median, two superior and two inferior;
- median, two medial and two lateral;
- median and two lateral?

***What paired sacral crests do you know:***

- + intermediate and lateral;
- superior and inferior;
- median and lateral;
- right and left?

***What unpaired sacral crests do you know:***

- + median;
- intermediate;
- lateral;
- superior and inferior?

***What anatomical structures are located on the lateral parts of the sacrum:***

- + auricular surfaces and sacral tuberosities;
- auricular surfaces and the apex;
- sacral tuberosities and articular processes;
- sacral tuberosities and the base of the sacrum?

***What is located inside the sacrum:***

- + a sacral canal;

- anterior sacral foramina;
- posterior sacral foramina;
- intervertebral foramina?

***The vertebral foramen of the sacral vertebrae transforms into:***

- + sacral canal;
- pelvic foramina;
- posterior sacral foramina;
- intervertebral foramina.

***The sacral canal terminates as:***

- + sacral hiatus;
- terminates blindly;
- pelvic foramen;
- dorsal foramen.

***How is an inferior part of the sacrum called:***

- + the apex;
- the base;
- lateral masses;
- auricular surface?

***What structures limit the sacral hiatus:***

- + sacral horns (cornua);
- inferior articular surface;
- superior articular surface;
- auricular surface?

***The apex of the sacrum join with:***

- + the coccyx;
- the 5th lumbar vertebra;
- an iliac bone;
- an ischial bone?

***What parts has the coccyx:***

- + the base which is turned upwards and the apex which is turned downwards;
- the apex which is turned upwards and the base which is turned downwards;
- superior and inferior parts, the apex;
- anterior and posterior parts, the base?

***How many ribs do you have:***

- + 12 pairs;
- 7 pairs;
- 10 pairs;
- 8 pairs?

**What parts has a rib:**

- + a bony part (posterior) and cartilaginous part (anterior);
- a bony part (anterior) and cartilaginous part (posterior);
- medial and lateral;
- the body, superior and inferior parts?

**How are the upper 7 ribs called:**

- + true ribs;
- false ribs;
- floating ribs;
- unnamed?

**What ribs are "true":**

- + upper 7 ribs;
- lower 7 ribs;
- all ribs;
- from the 8th to 10th?

**What ribs are called "false ribs":**

- + the ribs which don't connect with the sternum, but connect with the upper ribs;
- the ribs with short cartilaginous parts which terminate in muscles of anterior abdominal wall;
- the ribs which connect with the thoracic vertebrae;
- the ribs which connect with the sternum but don't connect with thoracic vertebrae?

**What ribs are called "floating ribs":**

- + the ribs with short cartilaginous parts which terminate in muscles of anterior abdominal wall;
- the ribs which don't connect with the sternum, but connect with the upper ribs;
- the ribs which connect with the thoracic vertebrae;
- the ribs which connect with the sternum but don't connect with thoracic vertebrae?

**What ribs are "false":**

- + from the 8th to the 10th;
- upper 7;
- the 11th and 12th;
- from 5th to 8th?

**What ribs are "floating":**

- + 11th and 12th;
- from 8 to 10;
- upper 7;
- from 5 to 8?

**What ends have the ribs:**

- + anterior – sternal and posterior – vertebral;
- superior and inferior;
- medial and lateral;
- medial and sternal?

**The posterior end of the rib connects with...**

- + the body of the thoracic vertebrae;
- transverse processes of the vertebrae;
- articular processes of the vertebrae;
- the sternum?

**What anatomical structure is located on the head of the rib:**

- + the crest of the head of the rib;
- the fossa of the head of the rib;
- the tubercle of the rib;
- the sulcus of the head of the rib?

**What anatomical structure is located just after the head of the rib:**

- + the neck of the rib;
- the tubercle of the rib;
- the angle of the rib;
- the costal groove?

**Where is the tubercle of the rib located:**

- + between the neck and the body of the rib;
- between the neck and the head of the rib;
- Between costal and vertebral ends of the rib;
- Between costal and vertebral parts of the rib?

**What ribs don't have costal tubercle:**

- + the 11th and 12th;
- from the 1st to the 10th;
- the 1st and 2nd;
- From the 2nd to the 7th?

**Where is the angle of the rib located:**

- + just after the costal tubercle;
- just after the head of the rib;
- between costal and vertebral ends of the rib;
- between costal and vertebral parts of the rib?

***In what ribs does costal tubercle correspond to the angle of the rib:***

- + the 1st;
- from the 1st to the 10th;
- the 1st and the 2nd;
- From the 2nd to the 7th?

***What surfaces have the bodies of the 2nd to the 12th ribs:***

- + external and internal;
- superior and inferior;
- superficial and deep;
- lateral and inferior?

***What edges have the bodies of the 2nd to the 12th ribs:***

- + superior and inferior;
- external and internal;
- medial and lateral;
- lateral and inferior?

***What anatomical structure is located on the inferior edge of the rib:***

- + costal groove;
- the angle of the rib;
- the column of the rib;
- the cartilage of the rib?

***What surfaces has the body of the 1st rib:***

- + superior and inferior;
- external and internal;
- medial and lateral;
- lateral and inferior?

***What edges has the body of the 1st rib:***

- + external and internal;
- superior and inferior;
- anterior and superior;
- lateral and inferior?

***What anatomical structures are located on the superior surface of the 1st rib:***

- + the tubercle of anterior scalene muscle and grooves for the subclavian vein and artery;
- the tubercle of anterior scalene muscle and costal groove;
- the tubercle of anterior scalene muscle and groove for the jugular vein;
- the tubercle of posterior scalene muscle and grooves for the subclavian vein and artery?

***How is the tubercle on the superior surface of the 1st rib called:***

- + the tubercle of anterior scalene muscle;
- the tubercle of posterior scalene muscle;
- the costal tubercle;
- the tubercle of serratus anterior muscle?

***What is located in front of the tubercle of anterior scalene muscle:***

- + the groove for the subclavian vein;
- the groove for the subclavian artery;
- the groove for the jugular vein;
- the costal groove?

***What is located behind the tubercle of anterior scalene muscle:***

- + the groove for the subclavian artery;
- the groove for the subclavian vein;
- the groove for the jugular vein;
- the costal groove?

***What parts has the sternum:***

- + the manubrium, the body and the xiphoid process;
- the leg, the body and the xiphoid process;
- the manubrium, the body and the articular process;
- the manubrium, the body and the transverse process?

***What anatomical structure is located on the superior edge of the manubrium:***

- + the jugular and clavicular notches;
- the costal notches;
- the jugular and costal notches;
- the jugular and xiphoid notches?

***Where is the jugular notch of the sternum located:***

- + on the superior edge of the manubrium;
- on the inferior edge of the manubrium;
- on the xiphoid process;
- on the lateral edge of the sternum?

***Where is the clavicular notch of the sternum located:***

- + on the lateral edge of the manubrium;
- on the superior edge of the manubrium;
- on the inferior edge of the manubrium;
- on the xiphoid process?

**What is located on the lateral edge of the body of the sternum:**

- + the costal notches;
- the jugular notch;
- the clavicular notches;
- the articular processes?

**The 2nd – 7th ribs connect with:**

- + costal notches of the body of the sternum;
- costal notches of the manubrium of the sternum;
- costal notches of the xiphoid process;
- costal notches of the manubrium and the body of the sternum.

**Where are the costal notches for the 7th ribs located:**

- + between the body and xiphoid process;
- between the manubrium and the body;
- on the lateral edge of the body;
- on the lateral edge of the manubrium?

**The process of the sternum is called:**

- + xiphoid;
- inferior articular;
- superior articular;
- transverse.

**Theme 4. Bones of the shoulder girdle.  
Bones of the free upper limb.**

**What parts are distinguished in the upper limb:**

- + pectoral (shoulder) girdle and the free upper extremities (handing part);
- a pectoral (shoulder) girdle and the arm;
- a pectoral (shoulder) girdle and the forearm;
- the arm, the forearm and the hand?

**What bones constitute the shoulder girdle:**

- + scapula and clavicle;
- clavicle and the sternum;
- scapula and the humerus;
- scapulae, ribs and the sternum?

**What borders has the scapula:**

- + medial, lateral and superior;
- medial, lateral and inferior;
- superior and inferior;
- superior, inferior and medial?

**What angles has the scapula:**

- + inferior, superior and lateral;
- inferior, superior and medial;
- medial, lateral and inferior;
- anterior, posterior and lateral?

**What surfaces has the scapula:**

- + costal and dorsal;
- medial and lateral;
- superior and inferior;
- costal and superior?

**What anatomical structure is located on a costal surface of the scapula:**

- + the subscapular fossa;
- the spine of scapula;
- the supraspinous fossa;
- the infraspinous fossa?

**What processes of the scapula do you know:**

- + acromion and the coracoid;
- articular and coracoid;
- acromion and medial;
- supraspinous and infraspinous?

**What anatomical structure is located on the lateral angle of the scapula:**

- + the glenoid cavity;
- the head of the scapula;
- a clavicular articular surface;
- a clavicular notch?

**What is located above the glenoid cavity:**

- + the supraglenoid tubercle;
- the infraglenoid tubercle;
- the coracoid process;
- the spine of the scapula?

**The clavicle is located between the:**

- + the scapula and the sternum;
- the scapula and the 1st rib;
- the sternum and the humerus;
- the sternum and ribs.

**What parts has the clavicle:**

- + the body, sternal and acromial ends;
- the base, medial and lateral ends;
- the body and two processes;
- the body, costal and humeral ends?



***The sternal end of clavicle connects with:***

- + a clavicular notch of the sternum;
- a xiphoid process of the sternum;
- an acromion;
- a coracoid process of the scapula.

***The acromial end of the clavicle connects with:***

- + an acromion;
- a clavicular notch of the sternum;
- a xiphoid process of the sternum;
- a coracoid process of the scapula.

***What surfaces has the clavicle:***

- + superior and inferior;
- anterior and posterior;
- medial and lateral;
- scapular and costal?

***What parts has the humerus:***

- + the diaphysis and two epiphyses;
- the diaphysis and processes;
- the base and epiphysis;
- the body and apophysis?

***What anatomical structures are located on the proximal end of the humerus:***

- + the head, the anatomical neck, greater and lesser tubercles, the crest of the lesser and greater tubercle and the intertubercular groove;
- the head, the surgical neck, the lateral and medial tubercles;
- the head, the anatomical neck, the superior and inferior tubercles, the radial groove;
- the head, the anatomical neck, the medial and lateral epicondyles?

***What is located just below the head of the humerus:***

- + the anatomical neck;
- the surgical neck;
- the crest of the greater tubercle;
- the crest of the lesser tubercle?

***What is the name of the narrowest place between the head and the body of the humerus:***

- + a surgical neck;
- an anatomical neck;
- an intertubercular groove;
- the crest of the lesser tubercle?

***Where is a radial groove located:***

- + on the posterior surface of the humerus;
- on the anterolateral surface of the humerus;
- on the anteromedial surface of the humerus;
- on the posterior surface of the medial epicondyle?

***What groove is located on the body of the humerus:***

- + radial;
- ulnar nerve;
- Intertubercular;
- median nerve?

***What anatomical structure is located above the trochlea anteriorly:***

- + the coronoid fossa;
- the radial fossa;
- the olecranon fossa;
- the groove for ulnar nerve?

***Where is the olecranon fossa located:***

- + above and behind the trochlea;
- in front and above the trochlea;
- above the capitulum humeri;
- on the proximal end of humerus, below its head?

***Where is the capitulum of humerus located:***

- + at the distal end, laterally from the trochlea;
- at the proximal end, below the head;
- at the distal end, above the medial epicondyle;
- at the distal end, above the lateral epicondyle?

***What anatomical structure is located above the trochlea posteriorly:***

- + the olecranon fossa;
- the coronoid fossa;
- the radial fossa;
- the groove for ulnar nerve?

***What parts has the ulna:***

- + the diaphysis and two epiphyses;
- the diaphysis and processes;
- the base and epiphysis;
- the body and apophysis?

***What anatomical structure is located at the proximal end of the ulna:***

- + a trochlear notch, an olecranon, a coronoid process, a radial notch and an ulnar tuberosity;
- the head, an articular fossa, an ulnar tuberosity;
- a trochlear notch, an olecranon, an ulnar notch, an ulnar tuberosity;
- an olecranon, an ulnar notch, an ulnar tuberosity?

***What is located between the olecranon and the coronoid process of the ulna:***

- + the trochlear notch;
- the radial notch;
- the ulnar notch;
- the articular circumference?

***Where is the ulnar tuberosity located:***

- + just below the coronoid process;
- behind the olecranon;
- on the top of the olecranon;
- on posterior surface of the ulna?

***What anatomical structure terminates the distal end of the ulna:***

- + the head of the ulna;
- the olecranon;
- the coronoid process;
- the trochlear notch?

***What anatomical structures are located at the distal end of the ulna:***

- + the head of the ulna and the styloid process;
- the olecranon and the coronoid process;
- the head and the neck of the ulna, a radial notch of the ulna;
- the olecranon and the styloid process?

***What parts has the radius:***

- + the diaphysis and two epiphyses;
- the diaphysis and processes;
- the base and the epiphysis;
- the body and the apophysis?

***What anatomical structures are located at the proximal end of the radius:***

- + the head, the articular process and the articular circumference;

- the trochlear notch, the olecranon, the coronoid process;
- the head and the styloid process;
- the head, the radial tuberosity?

***Where is the radial tuberosity located:***

- + on the anterior surface of the radius, below its neck;
- on the head of the radius;
- on the posterior surface of the radius, below its neck;
- on the inferior end of the radius?

***What parts has the skeleton of the hand:***

- + carpus (wrist), metacarpus and phalanges;
- metacarpus and phalanges;
- proximal and distal parts;
- proximal part and phalanges?

***How are the carpal bones arranged:***

- + in two rows – proximal and distal;
- in two rows – medial and lateral;
- in two rows – anterior and posterior;
- are not arranged?

***How many metacarpal bones are there:***

- + five metacarpal bones;
- two metacarpal bones;
- eight metacarpal bones;
- four metacarpal bones?

***What parts has the metacarpal bone:***

- + the base, the body and the head;
- the diaphysis and two epiphyses;
- the base and the epiphysis;
- the body and the apophysis?

***How is the proximal end of the metacarpal bone called:***

- + the base;
- the head;
- the proximal process;
- the articular process?

***How is the distal end of the metacarpal bone called:***

- + the head;
- the base;
- the distal process;
- the articular process?

**What metacarpal bone is the longest:**

- + the 2nd;
- the 1st;
- the 3rd;
- the 4th?

**How is the 1st finger called:**

- + the pollex;
- the hallux;
- the middle finger;
- the ring finger?

**How is the 2nd finger called:**

- + the index;
- the pollex;
- the middle finger;
- the ring finger?

**What finger is the longest:**

- + the 3rd;
- the 2nd;
- the 1st;
- the 4th?

**What phalanges of the fingers do you know:**

- + proximal, middle and distal;
- medial, middle and lateral;
- lateral, proximal and middle;
- lateral, distal and middle?

**What phalanges has the 1st finger:**

- + proximal and distal;
- proximal and middle;
- distal and middle;
- proximal, middle and distal?

**What parts have the phalanges:**

- + the base, the body and the head;
- the diaphysis and two epiphysis;
- the base and the epiphysis;
- the body and the apophysis?

## **Theme 5. Bones of the pelvic girdle and free lower limb**

**The hip bone is formed by...**

- + the ilium, the pubis and the ischium;
- the ilium and the sacrum;
- the pubis, the ischium and the coccyx;
- the ilium, the ischium and the sacrum.

**What anatomical structure is formed when bodies of the ilium, the pubis and the ischium join:**

- + the acetabulum;
- the articular fossa;
- the femoral fossa;
- the femoral cavity?

**How is articular surface of the acetabulum called:**

- + a lunate surface;
- an acetabular notch;
- an acetabular fossa;
- a femoral surface?

**How is the central part of the acetabulum called:**

- + an acetabular fossa;
- an acetabular notch;
- a lunate surface;
- the head of the acetabulum?

**What anatomical structure makes the acetabulum:**

- + an acetabular notch, a lunate surface and an acetabular fossa;
- an acetabular notch and a process;
- an acetabular fossa and two processes;
- a lunate surface, external and internal lips?

**What parts has the ilium:**

- + a body and an ala of the ilium;
- a body and a base;
- a base and a wing;
- a body and processes?

**The inferior thick part of the ilium is called:**

- + a body;
- a base;
- a wing;
- a lateral process.

**The superior wide part of the ilium is called:**

- + a wing;
- a body;
- a base;
- a lateral process.

***The superior free part of the iliac wing ends as:***

- + an iliac crest;
- an iliac process;
- an iliac fossa;
- an iliac tuberosity.

***The auricular surface of the ilium joins with:***

- + the auricular surface of the sacrum;
- the head of the femur;
- the body of the pubis;
- the ischial ramus.

***What parts has the pubis:***

- + a body and two rami;
- a body and two processes;
- a body and a base;
- a base and two rami?

***The symphyseal surface of the pubis joins with:***

- + the symphyseal surface of the opposite side;
- the ischial bone;
- the iliac bone;
- the sacrum.

***What part of the ischium forms the acetabulum:***

- + the body;
- the superior ramus;
- the interior ramus;
- neither part of the ischium forms the acetabulum?

***The body of the ischium continuous to:***

- + the ischial ramus;
- the base of the ischium;
- the body of the pubis;
- the inferior pubic ramus.

***The ischial ramus joins with:***

- + the inferior pubic ramus;
- the superior pubic ramus;
- the body of the pubis;
- the body of the ilium.

***The obturator foramen is bordered by:***

- + the pubic and ischial rami;
- the bodies of the ilium, the pubic and the ischium:

- the greater and lesser sciatic notches;
- the greater sciatic notch and the body of the pubis.

***What part has the femur:***

- + a diaphysis and two epiphyses;
- a diaphysis and processes;
- a base and an epiphysis;
- a body and an apophysis?

***What anatomical structure ends the proximal end of the femur:***

- + the head of the femur;
- the greater trochanter;
- the lesser trochanter;
- the neck of the femur?

***The head of the femur is placed:***

- + medially and upwards;
- laterally and upwards;
- in front and upwards;
- behind and upwards.

***The head of the femur join with:***

- + the hip bone;
- the tibia;
- the pubis;
- the ilium?

***What structure connects the head of the femur with its body:***

- + a neck;
- a greater trochanter;
- a lesser trochanter;
- an intertrochanteric line?

***What is located on posterior surfaces of the femur:***

- + an aspera line;
- an intertrochanteric line;
- an intertrochanteric tuberosity;
- a soleal line?

***What parts has the aspera line:***

- + lateral and medial lips;
- a pectineal line and a lateral lip;
- a lateral lip and a gluteal tuberosity;
- a medial lip and an intertrochanteric line?

**What makes the distal part of the femur:**

- + lateral and medial condyles;
- the head and the neck of the femur;
- the greater and lesser trochanters;
- a patellar surface, the greater and lesser tubercles?

**What separates the lateral and medial condyles of the femur posteriorly:**

- + an intercondylar fossa;
- the fovea of the head of the femur;
- a trochanteric fossa;
- a patellar surface?

**What shape has the patella:**

- + sesamoid;
- flat;
- long;
- irregular?

**What parts has the patella:**

- + a base and an apex;
- a body and an apex;
- a base and a body;
- a body and a process?

**What part has the tibia:**

- + a diaphysis and two epiphyses;
- a diaphysis and processes;
- a base and an epiphysis;
- a body and an apophysis?

**What anatomical structure ends the proximal end of the tibia:**

- + medial and lateral condyles;
- a head;
- an articular surface and medial malleolus;
- an articular process?

**What separates the superior articular surface of the tibia:**

- + an intercondylar eminence;
- an intercondylar fossa;
- a tibial fossa;
- a tibial eminence?

**What borders has the tibia:**

- + anterior, interosseous and medial;
- posterior and anterior;

- anterior, posterior and medial;
- posterior and medial?

**What anatomical structure is located on the anterior border of the tibia in its superior section:**

- + a tibial tuberosity;
- a soleal line;
- an anterior intercondylar area;
- a fibular notch?

**What surfaces has the tibia:**

- + medial, lateral and posterior;
- anterior and posterior;
- lateral and medial;
- interior, posterior and lateral?

**What anatomical structure is located on the distal end of the tibia medially:**

- + a medial malleolus;
- a lateral malleolus;
- an inferior malleolus;
- the head of the tibia?

**What parts has the fibula:**

- + a diaphysis and two epiphyses;
- a diaphysis and processes;
- a base and an epiphysis;
- a body and an apophysis?

**What anatomical structure marks the proximal end of the fibula:**

- + the head of the fibula;
- a lateral malleolus;
- the condyle;
- a medial malleolus?

**What anatomical structure marks the distal end of the fibula:**

- + a lateral malleolus;
- the head of the fibula;
- the apex of the fibula;
- a medial malleolus?

**The articular surface of the head of the fibula joins with:**

- + the tibia;
- the femur;
- the patella;
- the talus?

**How many tarsal bones has the foot:**

- + 7;
- 8;
- 4;
- 5?

**How are the tarsal bones arranged:**

- + in two rows – proximal and distal;
- in two rows – medial and lateral;
- in two rows – anterior and posterior;
- they are not arranged?

**What tarsal bones form the proximal row:**

- + the talus and the calcaneus;
- the navicular, the cuboid and the cuneiform;
- the talus, the cuboid and the cuneiform;
- the navicular and the calcaneus?

**What tarsal bones form the proximal row:**

- + the navicular, the cuboid and the cuneiform;
- the talus and the calcaneus;
- the talus, the cuboid and the cuneiform;
- the navicular and the calcaneus?

**What parts has the talus:**

- + a body, a head and a neck;
- a base and a head;
- a body and a base;
- a base and two articular surfaces?

**What anatomical structure is located on the top of the body of the talus:**

- + the trochlea of the talus;
- the head of the talus with articular surface;
- the trochlea and the head;
- the base with three articular surfaces?

**What anatomical structures are located on the inferior surface of the talus:**

- + anterior, posterior and middle calcaneal articular surfaces, sulcus tali;
- sulcus tali and the groove for the tendon of the flexor hallucis longus muscle;
- anterior and lateral calcaneal articular surfaces;
- posterior and lateral calcaneal articular surfaces?

**The anterior, posterior and middle calcaneal articular surfaces join:**

- + the calcaneus;
- the tibia and the fibula;
- the navicular and cuboid bones;
- the calcaneus and cuboid bones.

**What anatomical structures are located between the posterior and middle calcaneal articular surfaces of the talus:**

- + sulcus tali;
- the groove for the tendon of the flexor hallucis longus muscle;
- a posterior process of the talus;
- the neck of the talus?

**What anatomical structure ends the calcaneus posteriorly and downwards:**

- + a calcaneal tuberosity;
- sustentaculum tali;
- posterior articular processes;
- the head of the calcaneus?

**What anatomical structures are located on the superior surface of the calcaneus:**

- + the anterior, posterior and middle talar articular surfaces;
- the anterior, posterior and lateral talar articular surfaces;
- the lateral and medial talar articular surfaces;
- the superior and inferior talar articular surfaces?

**The anterior, posterior and middle talar articular surfaces join:**

- + the talus;
- the tibia and the fibula;
- the navicular and cuboid bones;
- the calcaneus and cuboid bones?

**What anatomical structure is located on the anterior end of the calcaneus:**

- + the cuboid articular surface;
- the navicular articular surface;
- the cuneiform articular surface;
- the talar articular surface?

**What cuneiform bones do you know:**

- + medial, intermediate and lateral;
- lateral and medial;

- posterior, anterior and lateral;
- posterior, anterior and intermediate?

**The distal surface of the navicular bone joins with:**

- + the cuneiform bones;
- the head of the talus;
- the distal part of the calcaneus;
- the cuboid bone?

**How many metatarsal bones has the foot:**

- + 5;
- 4;
- 6;
- 3?

**What parts has each metatarsal bone:**

- + a base, a body and a head;
- a body and two heads;
- a base and two heads;
- a body, superior and inferior processes?

**How is the proximal end of the metatarsal bone called:**

- + a base;
- a head;
- a superior (proximal) process;
- an articular process?

**How is the distal end of the metatarsal bone called:**

- + a head;
- a base;
- an inferior (distal) process;
- an articular process?

**The heads of the metatarsal bones join with:**

- + the base of the proximal phalanges;
- the base of the distal phalanx;
- cuneiform bones;
- a cuboid bone ?

**What phalanges have the toes:**

- + proximal, middle and distal;
- proximal and distal;
- proximal, middle and inferior;
- proximal and lateral?

**What phalanges has the big toe:**

- + proximal and distal;
- proximal, middle and distal;
- proximal, middle and inferior;
- proximal and lateral?

**What parts has each phalanx:**

- + a base, a body and a head;
- a body and two heads;
- a base and two heads;
- a body, superior and inferior processes?

**Theme 6. Introduction in craniology. The frontal, parietal, occipital, sphenoid and ethmoid bones**

**The frontal bone is:**

- + an unpaired pneumatic bone of the neurocranium;
- a paired bone of the neurocranium;
- an unpaired pneumatic bone of the visceral skull;
- a paired bone of the visceral skull.

**What parts has the frontal bone:**

- + orbital, nasal and squamous parts;
- orbital and nasal parts;
- lateral and squamous parts;
- nasal and lateral parts?

**Name the surface of the squamous part which has contact with the brain:**

- + internal;
- external;
- medial;
- lateral.

**Where is a supra-orbital notch (a supra-orbital foramen) located:**

- on the supra-orbital margin;
- on the infra-orbital margin;
- on the temporal line of the frontal bone;
- on the frontal crest?

**What name has the most prominent elevation of the squamous part of the frontal bone:**

- + a frontal tuber;
- a glabella;
- a supra-orbital margin;
- a zygomatic process?

***What anatomical structure separates orbital parts of the frontal bone:***

- + the ethmoidal notch;
- the foramen caecum;
- the frontal crest;
- the temporal line?

***What surfaces has the orbital part of the frontal bone:***

- + superior (cerebral) and inferior (orbital);
- lateral and medial;
- medial and inferior (orbital);
- lateral and superior (cerebral)?

***Where is nasal part of the frontal bone situated:***

- + between the orbital parts;
- between the superciliary arches;
- between the frontal tubers;
- between the squamous part and the frontal sinus?

***What name has a cavity of the frontal bone:***

- + the frontal sinus;
- the ethmoidal sinus;
- the sagittal sinus;
- the alveolar sinus?

***What part of the calvaria (skull cap) forms the paired parietal bones:***

- + superolateral;
- anterior;
- posterior;
- inferior?

***The parietal bone according to classification is:***

- + flat;
- spongy;
- pneumatic;
- sesamoid.

***What surfaces has the parietal bone:***

- + external and internal;
- medial and lateral;
- superior and inferior;
- inferior and lateral?

***What borders has the parietal bone:***

- + sagittal, frontal, occipital, squamosal;
- anterior and posterior;
- squamosal, medial and lateral;
- inferior, superior and lateral?

***What border of the parietal bone articulates with the occipital bone:***

- + occipital;
- sagittal;
- frontal;
- squamosal?

***The sagittal border of the parietal bone articulates with:***

- + the opposite parietal bone;
- the occipital bone;
- the temporal bone;
- the frontal bone.

***The squamosal border of the parietal bone articulates with:***

- + the temporal bone;
- the parietal bone;
- the occipital bone;
- the frontal bone.

***What border of the parietal bone articulates with the temporal bone:***

- + squamosal;
- occipital;
- sagittal;
- frontal?

***Where is the parietal tuber situated:***

- + in the centre of the external surface of the parietal bone;
- near the occipital angle;
- in the center of the internal surface of the parietal bone;
- near the frontal angle;

***What parts has the occipital bone:***

- + basilar, lateral and squamous;
- squamous, superior and inferior;
- basilar and two medial;
- basilar, medial and lateral?

***Four parts of the occipital bone enclose:***

- + the foramen magnum;
- the foramen minor;
- the clivus;
- the condylar canal.



**What part of the occipital bone is located in front of the foramen magnum:**

- + basilar;
- squamous;
- lateral;
- medial?

**The sphenoid bone consists of the following parts:**

- + the body, the greater and lesser wings, a pterygoid process;
- the body and a squamous part;
- the body, a squamous part and a lesser wing;
- the body, the greater and lesser wings, an articular process?

**What anatomical structure is inside the body of the sphenoid bone:**

- + a sphenoid sinus;
- a foramen magnum;
- a sigmoid sinus;
- an optic canal?

**The pterygoid process consists of the following laminae:**

- + medial and lateral;
- superior and inferior;
- anterior and posterior;
- lateral and anterior.

**The sphenoid bone according to classification is:**

- + pneumatic;
- flat;
- spongy;
- sesamoid.

**The ethmoid bone consists of the following parts:**

- + the cribriform plate, the perpendicular plate and the ethmoidal labyrinth;
- the cribriform, medial and lateral plates;
- the body and the perpendicular plate;
- the body and the ethmoidal labyrinth.

**What anatomical structure is between the superior and middle nasal conchae:**

- + superior nasal meatus;
- middle nasal meatus;

- inferior nasal meatus;
- hiatus semilunaris?

**Theme 7. The temporal bone. Canals of the temporal bone**

**The temporal bone is:**

- + the mixed bone;
- the flat bone;
- the unpaired pneumatic bone of the neurocranium;
- the paired bone of the visceral skull.

**What parts does the temporal bone consist of:**

- + the petrous, tympanic and squamous parts;
- the squamous part and the body;
- the basilar part, the squamous part and the mastoid process;
- the petrous part, the greater and lesser wings?

**What parts has the petrous part of the temporal bone:**

- + the base and the apex;
- the body and the lesser wing;
- the body and the apex;
- the base and the articular process?

**What part of the pyramid continues to the mastoid process:**

- + the base;
- the apex;
- the body;
- the lesser wing?

**What part of the pyramid is free and points forward and medially:**

- + the apex;
- the base;
- the body;
- the lesser wing?

**The following surfaces are distinguished in the pyramid:**

- + anterior, posterior, inferior;
- superior and inferior;
- medial, lateral and inferior;
- anterior, posterior and inferior.

**Where is the external opening of the musculotubal canal located:**

- + in the angle between the anterior margin of the pyramid and the squamous part of the temporal bone;
- on the posterior surface of the pyramid near the apex;
- on the inferior surface of the pyramid near the jugular fossa;
- on the inferior surface of the pyramid near the subarcuate fossa?

**Where does the musculotubal canal exit:**

- + tympanic cavity;
- internal acoustic meatus;
- petrotympanic fissure;
- at the bottom of the jugular fossa?

**What is the name of the superior portion of the musculotubal canal:**

- + canal for tensor tympani;
- canal for auditory tube;
- hiatus for lesser petrosal nerve;
- internal acoustic meatus?

**Where is tegmen tympani located:**

- + on anterior surface of the pyramid;
- on posterior surface of the pyramid;
- on superior surface of the pyramid;
- on inferior surface of the pyramid?

**What structure is located on the anterior surface near the apex of the pyramid:**

- + trigeminal impression;
- tegmen tympani;
- hiatus for greater petrosal nerve;
- internal acoustic opening?

**Where is the hiatus for lesser petrosal nerve located:**

- + on the anterior surface of the pyramid, laterally to the trigeminal impression;
- on the anterior surface of the pyramid, above arcuate eminence;
- on the posterior surface of the pyramid, laterally to the internal acoustic opening;
- on the inferior surface of the pyramid, at the bottom of the jugular fossa?

**What anatomical structures originate from hiatus for greater petrosal nerve and hiatus for lesser petrosal nerve:**

- + a groove for greater petrosal nerve and a groove for lesser petrosal nerve;
- caroticotympanic canaliculi;
- tympanic canaliculi;
- petrotympanic fissures?

**What structure is on the superior border of the pyramid:**

- + the groove for superior petrosal sinus;
- the groove for inferior petrosal sinus;
- the groove for sigmoid sinus;
- the groove for lesser petrosal nerve?

**What structure is on the posterior border of the pyramid:**

- + the groove for inferior petrosal sinus and the opening of cochlear canaliculus;
- the groove for inferior petrosal sinus and the opening of vestibular canaliculus;
- the groove for superior petrosal sinus and the opening of cochlear canaliculus;
- the groove for superior petrosal sinus and the opening of vestibular canaliculus?

**Where is the jugular fossa located:**

- + on the inferior surface of the pyramid;
- on the anterior surface of the pyramid;
- on the posterior surface of the pyramid;
- on the superior surface of the pyramid?

**Where does the mastoid canaliculus start:**

- + at the bottom of the jugular fossa;
- in the subarcuate fossa;
- in the petrosal fossula;
- at the bottom of the internal acoustic meatus?

**Where does the mastoid canaliculus open:**

- + into the tympanomastoid fissure;
- into the petrotympanic fissure;
- into the petrosquamous fissure;
- into the tympanic cavity?

**What structure is formed by the jugular notch of the temporal and occipital bones:**

- + jugular foramen;
- jugular fossa;

- foramen rotundum;
- external aperture of the carotid canal?

**What structure is located on the inferior surface of the petrous part in front of the jugular fossa:**

- + external aperture of the carotid canal;
- internal aperture of the carotid canal;
- opening of the mastoid canaliculus;
- opening of the caroticotympanic canaliculus?

**Where is the internal aperture of the carotid canal located:**

- + on the apex of the petrous part of the temporal bone;
- at the bottom of the internal acoustic meatus;
- on the anterior surface of the petrous part near the base;
- in the tympanic cavity?

**The carotid canal communicates:**

- + the external base of the skull with the internal one;
- the external base of the skull with the tympanic cavity;
- the internal base of the skull with the tympanic cavity;
- the pterygopalatine fossa with the external base of the skull.

**Where do the caroticotympanic canaliculi start:**

- + on the posterior wall of the carotid canal near the external aperture;
- at the bottom of the petrosal fossula;
- at the bottom of the jugular fossa;
- at the bottom of the internal acoustic meatus?

**Where do the caroticotympanic canaliculi open:**

- + in tympanic cavity;
- into the tympanomastoid fissure;
- into the petrotympanic fissure;
- into the petrosquamous fissure?

**What structure is located on the crest between the jugular fossa and the external aperture of the carotid canal:**

- + petrosal fossula;

- hiatus for lesser petrosal nerve;
- hiatus for greater petrosal nerve;
- opening of the mastoid canaliculus?

**What structure is located at the bottom of the petrosal fossa:**

- + inferior aperture of the tympanic canaliculus;
- hiatus for lesser petrosal nerve;
- hiatus for greater petrosal nerve;
- aperture of the carotid canal?

**Where does the tympanic canaliculus start:**

- + in the petrosal fossula;
- hiatus for lesser petrosal nerve;
- hiatus for greater petrosal nerve;
- at the bottom jugular fossa?

**Where does the tympanic canaliculus open:**

- + into the hiatus for lesser petrosal nerve;
- into the petrosal fossula;
- into the hiatus for greater petrosal nerve;
- into the tympanic cavity?

**What structure is located between the mastoid and styloid processes:**

- + stylomastoid foramen;
- petrosal fossula;
- jugular fossa;
- jugular foramen?

**What canaliculus originates from facial canal:**

- + canaliculus for chorda tympani;
- mastoid canaliculus;
- tympanic canaliculus;
- caroticotympanic canaliculus?

**Where does the canaliculus for chorda tympani begin:**

- + from facial canal above stylomastoid foramen;
- at the bottom of petrosal fossula;
- at the bottom of jugular fossa;
- on the wall of the carotid canal?

**Where does the canaliculus for chorda tympani open:**

- + into the petrotympanic fissure;
- into the tympanic cavity;
- into the tympanomastoid fissure;

– into the tympanosquamous fissure?

**Where does the facial canal begin:**

- + at the bottom of the internal acoustic meatus;
- at the bottom of the external acoustic meatus;
- on the wall of the carotid canal;
- at the bottom of the jugular fossa?

**Where does the facial canal open:**

- + into stylomastoid foramen;
- at the bottom of jugular fossa;
- at the bottom of the external acoustic meatus;
- into hiatus for lesser petrosal nerve?

**What structures are located on the inferior surface of the mastoid process:**

- + mastoid notch and the occipital groove;
- mastoid and parietal notches;
- parietal notch and the occipital groove;
- occipital groove and the groove for sigmoid sinus?

**What structures are located on the medial surface of the mastoid process:**

- + a groove for sigmoid sinus;
- a occipital groove;
- a groove for superior petrosal sinus;
- a groove for inferior petrosal sinus?

**What bones have the groove for sigmoid sinus:**

- + mastoid process of the temporal bone, parietal and occipital bones;
- sphenoid bone and mastoid process of the temporal bone;
- occipital, parietal and frontal bones;
- sphenoid and occipital bone?

**What structures are inside the mastoid process:**

- + mastoid air cells and mastoid antrum;
- mastoid air cells and tympanic cavity;
- mastoid antrum and tympanic cavity;
- mastoid antrum and stylomastoid foramen?

**What foramen is located on the tympanic part of the temporal bone:**

- + external acoustic meatus;

- internal acoustic meatus;
- external aperture of the carotid canal;
- stylomastoid foramen?

**What structure separates the tympanic part from the mastoid process of the temporal bone:**

- + tympanomastoid fissure;
- tympano–petrosal fissure;
- articular tubercle;
- zygomatic arch?

**What surfaces has the squamous part of the temporal bone:**

- + internal and external;
- superior and inferior;
- medial and lateral;
- internal and superior?

**Where is the mandibular fossa of the temporal bone located:**

- + on the squamous part near the zygomatic process;
- on the squamous part near the base of the mastoid process;
- on the tympanic part near the base of the styloid process;
- on the tympanic part below external acoustic meatus?

**Where is the articular process of the temporal bone located:**

- + on the squamous part in front of the mandibular fossa;
- on the squamous part behind of the mandibular fossa;
- on the squamous part near the base of the mastoid process;
- on the tympanic part near the base of the styloid process?

**What canals begin from the inferior surface of the petrous part of the temporal bone:**

- + carotid, tympanic, mastoid;
- carotid, facial, canaliculus for chorda tympani;
- musculotubal, carotid, caroticotympanic;
- facial, carotid, tympanic?

**Where is the petrotympanic fissure located:**

- + in the tympanosquamous fissure between the plate of the petrous part and tympanic

- parts;
- between the mastoid process and tympanic parts;
- in the tympanosquamous fissure between the plate of the petrous part and squamous parts;
- between the mastoid process and petrous part?

### **Theme 8. Bones of the facial skull**

#### ***The visceral cranium is formed by:***

- + the maxilla, the mandible, the ethmoid bone, the vomer, the zygomatic bone;
- the maxilla, the mandible, the palatine bone, the inferior nasal concha, lacrimal and nasal bones, the vomer and the zygomatic bones;
- the mandible, the palatine bone, the superior nasal concha, the middle nasal concha, the lacrimal bones, the vomer, the frontal bone;
- the maxilla, the palatine bones, the middle nasal concha, the zygomatic bones and frontal bone, the ethmoid bone?

#### ***What bones belong to the paired bones of the facial skull:***

- + the maxilla, the mandible, the inferior nasal concha, the vomer;
- the maxilla, the palatine bone, the inferior nasal concha, the lacrimal and nasal bones, the zygomatic bone;
- the mandible, the palatine bone, lacrimal and nasal bones, the zygomatic bones;
- the maxilla, the palatine bone, the zygomatic bones, the vomer, the inferior nasal concha?

#### ***What kind of bones does the maxilla belong to by classification:***

- + to flat bones;
- to pneumatic bones;
- to unpaired bones of facial skull;
- to spongy bones?

#### ***What are the components of the maxilla:***

- + main part and etmoidal, palatine process;
- the body, the frontal and zygomatic, the alveolar, the palatine processes;
- the body, the squamous part, the zygomatic, the etmoidal, the palatine processes;
- the squamous part and frontal, zygomatic, etmoidal, palatine processes?

#### ***The following surfaces are distinguished on the body of the maxilla:***

- + the anterior surface, the medial surface, the oral surface;
- the anterior surface, the orbital surface, the infratemporal surface, the nasal surface;
- the anterior surface, the posterior surface, the lateral surface;
- the anterior surface, the nasal surface, the oral surface, the orbital surface?

#### ***What is located below the infraorbital margin of the maxilla:***

- + the anterior nasal spine;
- the infraorbital foramen;
- the maxillary tuberosity;
- the maxillary hiatus?

#### ***Where is the infraorbital canal located:***

- + in the palatine process of the maxilla;
- in the body of the maxilla;
- in the zygomatic process of the maxilla; nontal process.

#### ***The infraorbital sulcus of the maxilla resides:***

- + on the infratemporal surface of the body;
- on the orbital surface of the body;
- on the frontal surface of the body;
- on the frontal process.

#### ***On the nasal surface of the body of the maxilla are located:***

- + the canine fossa, the infraorbital foramen, the infraorbital canal;
- the maxillary hiatus, the lacrimal groove, the ethmoidal crest, the conchal crest, the greater palatine groove;
- the alveolar canal, the incisive canal, the nasal crest;
- the maxillary hiatus, the incisive canal, the greater palatine groove.

#### ***The incisive canal of the maxilla is located:***

- + on the infratemporal surface of the body;
- inside the palatine processes;
- on the orbital surface of the body;
- on the frontal process.

**What anatomical structures are located on the alveolar process of the maxilla:**

- + the alveolar yokes, the infraorbital foramen;
- the dental alveoli, the interalveolar septa, the alveolar yokes the infraorbital canal;
- the alveolar hiatus, the incisive canal, the nasal crest;
- the maxillary hiatus, the incisive canal, the dental alveoli?

**What anatomical structures are located on the palatine processes of the maxilla:**

- + the alveolar yokes, the infraorbital and incisive canals;
- the nasal crest, the incisive canal;
- the alveolar canals, the incisive canal, the nasal crest;
- the maxillary hiatus, the incisive canal, dental alveoli?

**What are the components of the palatine bone:**

- + the body and the horizontal plate;
- the perpendicular and horizontal plates;
- the body and the perpendicular plate;
- the body and the processes ?

**The anterior edge of the horizontal plate of the palatine bone connects with:**

- + the same edge of the horizontal plate of contralateral bone;
- the posterior edge of palatine process of the maxilla;
- the alveolar process of the maxilla;
- the edges of the dental alveoli?

**The medial edge of the horizontal plate of the palatine bone connects with:**

- + the anterior edge of palatine process of the maxilla;
- the the same edge of the horizontal plate of the contralateral bone;
- the the ethmoidal process of the maxilla;
- the posterior edge of the nasal bone?

**The palatine processes of the maxilla and the horizontal plates of the palatine bones are formed with:**

- + the nasal septum;

- the bony palate;
- the lateral wall of the nasal cavity;
- the medial wall of the pterygopalatine fossa?

**What anatomical structures are located on the horizontal plate of the palatine bone:**

- + the alveolar yokes, infraorbital and greater palatine openings;
- the greater palatine opening, the nasal crest, the posterior nasal spine;
- the alveolar yokes, incisive canal, nasal crest;
- maxillary hiatus, incisive canal, posterior nasal spine?

**The perpendicular plate of the palatine bone is the part of:**

- + the nasal septum;
- the lateral wall of the nasal cavity;
- the hard palate;
- the lower wall of the orbital fossa.

**What processes are there on the palatine bone:**

- + the posterior sphenoidal process processes;
- the pyramidal, the orbital and sphenoidal processes;
- the pyramidal, lateral and medial processes;
- the orbital, sphenoidal, inferior and ethmoidal processes?

**What bones of the facial skull reside in the nasal cavity:**

- + the nasal bones;
- the inferior concha, the vomer;
- the vomer, the lacrimal bone;
- the inferior concha, the lacrimal bone?

**Where is the inferior concha located:**

- + on the bone palate;
- on the lateral wall of the nasal cavity, below the middle concha;
- on the nasal septum;
- on the bottom wall of the nasal cavity?

**What anatomical structure does the vomer form:**

- + the inferior wall of the nasal cavity;
- the posterior part of the bony septum;
- the lateral wall of the nasal cavity;
- the anterior part of the bone septum?

**What border of the vomer separates the right choana from the left one:**

- + anterior;
- posterior;
- lateral;
- inferior?

**The anterior edge of the vomer connects with:**

- + the nasal bones;
- the perpendicular plate of the ethmoid bone;
- the perpendicular plate of the palatine bone;
- the palatine process of the maxilla.

**The nasal bones form:**

- + the bony part of the nasal septum;
- the superior wall of the nasal cavity;
- the inferior wall of the nasal cavity
- the lateral wall of the nasal cavity.

**Where is the lacrimal bone found:**

- + in the anterior part of the lateral wall of the orbit;
- in the anterior part of the medial wall of the orbit;
- in the inferior wall of the orbit;
- in the superior wall of the orbit?

**The orbital process of the palatine bone takes place in formation of:**

- + the anterior part of the lateral wall of the orbit;
- the posterior part of the inferior wall of the orbit;
- the anterior part of the medial wall of the orbit;
- the superior wall of the orbit?

**What processes the zygomatic bone has:**

- + the frontal and maxillary processes;
- the frontal and temporal processes;
- the temporal and nasal processes;
- the frontal, maxillary and nasal processes?

**What surfaces the zygomatic bone has:**

- + orbital and nasal;
- lateral, temporal and orbital;
- medial and orbital;
- lateral, medial and temporal?

**What bones form the zygomatic arch:**

- + the zygomatic process of the frontal bone and the zygomatic bone;
- the zygomatic process of the temporal bone and the temporal process of the zygomatic bone;
- the zygomatic process of the maxilla and the zygomatic bone;
- the zygomatic process of the temporal bone and the nasal bone?

**Where is the zygomaticofacial foramen located:**

- + on the temporal surface of the zygomatic bone;
- on the lateral surface of the zygomatic bone;
- on the orbital surface of the zygomatic bone;
- on the nasal surface of the zygomatic bone?

**Where is the zygomaticotemporal foramen located:**

- + on the lateral surface of the zygomatic bone;
- on the temporal surface of the zygomatic bone;
- on the orbital surface of the zygomatic bone;
- on the nasal surface of the zygomatic bone ?

**The mandible articulates with:**

- + the zygomatic bone;
- the two temporal bones;
- the frontal bone;
- the maxilla.

**What parts does the mandible consist of:**

- + two processes and the body;
- the body and the two rami;
- the body and articular heads;
- the body and the two arches?

**The angle of the mandible is located:**

- + between the two rami of the mandible;
- between the body and the ramus of the mandible;
- between the coronoid process and the condylar process;
- between the body and the coronoid process?

**What anatomical structures are located on the external surface of the body of the mandible:**

- + the mental foramen, the sublingual fossa, the dental alveoli;
- the mental protuberance, the mental tubercle, the mental foramen, the oblique line;
- the mental spine, the digastric fossa, the mylohyoid line;
- the sublingual fossa, the submandibular fossa, the mylohyoid line, the digastric fossa, the mental spine?

**What anatomical structures are located on the internal surface of the body of the mandible:**

- + the mental foramen, the sublingual fossa, the dental alveoli;
- the sublingual fossa, the submandibular fossa, the mylohyoid line, the digastric fossa, the mental spine;
- the mental spine, the digastric fossa, the mylohyoid line;
- the mental protuberance, the mental tubercle, the mental foramen, the oblique line?

**Where is the mental spine located:**

- + in the middle of the external surface of the body of the mandible;
- in the middle of the internal surface of the body of the mandible;
- on the external surface of the angle of the mandible;
- on the inner surface of the angle of the mandible?

**What is located on the external surface of the angle of the mandible:**

- + the pterygoid tuberosity;
- the masseteric tuberosity;
- the mental foramen;
- the digastric fossa?

**What is located on the inner surface of the angle of the mandible:**

- + the masseteric tuberosity;
- the pterygoid tuberosity;
- the mental foramen;
- the digastric fossa?

**Where is mental foramen located:**

- + above pterygoid tuberosity on the external surface of the ramus of the mandible;
- above the pterygoid tuberosity on the internal surface of the ramus of the mandible;
- on the external surface of the mandibular angle;
- on the internal surface of the angle of the mandible?

**The mandibular canal reaches:**

- + the mental spine;
- the mental foramen;
- the submandibular fossa;
- the dental alveoli.

**The mandibular canal begins by:**

- + the mental spine;
- the mandibular foramen;
- the submandibular fossa;
- the dental alveoli.

**Where is the pterygoid fossa of the mandible located:**

- + on the inferior surface of the body;
- on the anterior surface of the cervix;
- on the external surface of the body;
- on the alveolar part?

**Where is the digastric fossa of the mandible located:**

- + on the external surface of the body;
- on the base of the mandible;
- on the alveolar part;
- on the anterior surface of the cervix?

**Where is the sublingual fossa of the mandible located:**

- + on the base of the mandible;
- on the inferior surface of the body;
- on the external surface of the body;
- on the alveolar part?

**Where is the mental protuberance of the mandible located:**

- + on the inferior surface of the body;
- on the external surface of the body;
- on the base of the mandible;



– on the alveolar part?

**Where is the mental spine of the mandible located:**

- + on the anterior surface of the cervix;
- on the inferior surface of the body;
- on the external surface of the body;
- on the alveolar part?

**Where is the mylohyoid line of the mandible located:**

- + on the anterior surface of the cervix;
- on the internal surface of the body;
- on the external surface of the body;
- on the alveolar part?

**Where is the oblique line of the mandible located:**

- + on the internal surface of the body;
- on the external surface of the body;
- on the external surface of the body;
- on the alveolar part?

**Where is the hyoid bone located:**

- + in the facial region of the skull;
- in the region of the neck;
- in the region of neurocranium;
- in the region of the head?

**What are the parts of the hyoid bone:**

- + the body and lesser horn;
- the body, the lesser horn, the greater horn;
- the body and greater horn;
- the body with two branches ?

**Theme 9. The skull as a whole. Topography of the orbit, bony nasal cavity, paranasal sinuses. External and internal aspects of the base of the skull. Temporal, infratemporal and pterygopalatine fossa**

**What foramen is located in the center of the posterior part of the external base of the skull:**

- + the foramen magnum;
- the foramen lacerum;
- the jugular foramen;

– the oval foramen?

**What structures are located laterally from the foramen magnum:**

- + the occipital condyle, the condylar fossa and the canal;
- the jugular foramen and the mastoid process;
- the occipital condyle and the stylomastoid foramen;
- the oval foramen and the hypoglossal canal?

**What structure penetrates the occipital condyle:**

- + the hypoglossal canal;
- the condylar canal;
- the jugular foramen;
- the musculotubal canal?

**What structure is located on the external base of the skull in front of the foramen magnum:**

- + the basilar part of the occipital bone with the pharyngeal tubercle;
- the body of the sphenoid bone with the Turkish saddle;
- the mastoid process;
- the jugular process and fossa?

**What structures bound the jugular foramen:**

- + the jugular fossa, the jugular notch of the temporal bone and the jugular notch of the occipital bone;
- the greater and lesser wings of the sphenoid bone;
- the mastoid and styloid processes;
- the body of the sphenoid bone, the apex of the temporal bone and a greater wing of the sphenoid bone?

**What structure is located between the mastoid and styloid processes:**

- + the stylomastoid foramen;
- the tympanomastoid fissure;
- the mastoid notch;
- the occipital groove?

**What bones form the zygomatic arch:**

- + the zygomatic process of the temporal bone and the temporal process of the zygomatic bone;

- the zygomatic process of the frontal bone and the frontal process of the zygomatic bone;
- the zygomatic process of the maxilla and the zygomatic process of the temporal bone;
- the coronoid and condylar processes of the mandible?

***What process of the sphenoid bone is located on the external base of the skull:***

- + the pterygoid process;
- the medial and lateral processes;
- the coronoid and condylar processes;
- the zygomatic and condylar processes?

***The bony palate is formed by:***

- + two palatine processes of the maxilla and two horizontal plates of the palatine bone;
- two palatine processes of the maxilla and a perpendicular plate of the palatine bone;
- the horizontal and perpendicular plates of the palatine bone;
- the alveolar process of the maxilla and the horizontal plate of the palatine bone.

***What cranial fossae are on the internal surface of the base of the skull:***

- + anterior, middle and posterior;
- superior and inferior;
- medial, lateral and middle;
- superior, middle and inferior?

***What bones form the anterior cranial fossa:***

- + the orbital part of the frontal bone, the lesser wing of the sphenoid bone and the cribriform plate of the ethmoid bone;
- the lesser and greater wings of the sphenoid bone;
- the orbital part of the frontal bone and the greater wing of the sphenoid bone;
- the body and the greater wing of the sphenoid bone and the cribriform plate of the ethmoid bone?

***What bones form the middle cerebral fossa:***

- + the body and the greater wing of the sphenoid bone, the anterior surface of the pyramid and the squamous part of the temporal bone;

- the body, the greater and lesser wings of the sphenoid bone;
- the body, the lesser wing of the sphenoid bone, the inferior surface of the pyramid and the squamous part of the temporal bone;
- the body, the greater wing of the sphenoid bone, the basilar part of the occipital bone, the posterior surface of the pyramid of the temporal bone?

***What anatomical structure is located on the internal base of the skull between the greater and lesser wings of the sphenoid bone:***

- + the superior orbital fissure;
- the inferior orbital fissure;
- the foramen lacerum;
- the optic canal?

***What bones form the posterior cranial fossa:***

- + the occipital bone, the posterior surface of the pyramid and the internal surface of the mastoid process of the temporal bone;
- the occipital bone, the body and the greater wing of the sphenoid bone;
- the occipital and parietal bones, the anterior surface of the temporal bone;
- the occipital bone, the inferior surface of the pyramid of the temporal bone, the body of the sphenoid bone?

***What anatomical structure is located on the apex of the orbit:***

- + the optic canal;
- the trochlear fovea;
- the zygomatico-orbital foramen;
- the inferior orbital fissure?

***What structure is located between the superior and lateral walls of the orbit:***

- + the superior orbital fissure;
- the inferior orbital fissure;
- the optic canal;
- the infraorbital canal?

***What structure is located between the inferior and lateral walls of the orbit:***

- + the inferior orbital fissure;
- the superior orbital fissure;

- the optic canal;
- the infraorbital canal?

***The temporal fossa communicates with:***

- + the infratemporal fossa;
- the anterior cranial fossa;
- the middle cranial fossa;
- the orbital cavity.

***The bony nasal septum is composed of:***

- + the perpendicular plate of the ethmoid bone and the vomer;
- the perpendicular plate of the palatine bone and the vomer;
- the palatine process of the maxilla and the vomer;
- the horizontal plate of the palatine bone and the vomer.

***The nasal cavity in the front opens with:***

- + the piriform aperture;
- the choanae;
- the aditus of the nasal cavity;
- the nasal meatus.

***What anatomical structure communicates nasal cavity with the pharynx:***

- + the choanae;
- the piriform aperture;
- the common nasal meatus;
- the sphenopalatine foramen?

***What walls has the nasal cavity:***

- + superior, inferior and two lateral;
- superior, inferior, lateral and medial;
- anterior, posterior, superior and inferior;
- lateral, inferior and anterior?

***The superior nasal meatus lies between:***

- + the superior and middle nasal conchae;
- the superior wall of the nasal cavity and the superior nasal concha;
- the nasal bone and the superior nasal concha;
- the middle nasal concha and the vomer.

***What nasal meatus is located between the middle and inferior nasal conchae:***

- + middle;
- superior;
- inferior;
- common?

***The inferior nasal meatus lies between:***

- + the inferior nasal concha and the inferior wall of the nasal cavity;
- the inferior and middle nasal conchae;
- the inferior nasal concha and the nasal bone;
- the inferior nasal concha and the vomer.

**Theme 10. Connections of bones of the trunk. The vertebral column, the thoracic cage as a whole. Connections of bones of the skull and the skull with the vertebral column**

***The vertebral bodies are articulated with each other by:***

- + synchondroses or symphyses;
- synostoses;
- syndesmosis;
- synovial joints.

***Where is the intervertebral disk located:***

- + between the bodies;
- between the superior and inferior articular processes;
- between atlas and occipital bone;
- between the vertebral arches?

***What parts has the intervertebral disk:***

- + central and peripheral;
- anterior and posterior;
- superior and inferior;
- lateral and medial?

***What ligament connects the vertebral arches:***

- + ligamentum flava;
- intertransverse ligament;
- ligamentum nuchae;
- posterior longitudinal ligament?

***What ligaments are located between spinous processes:***

- + interspinous ligaments;
- supraspinous ligaments;
- ligamentum nuchae;
- ligamentum flava?

***What ligament connects the apexes of the spinous processes:***

- + supraspinous ligament;
- interspinous ligament;
- posterior longitudinal ligament;

– ligamentum flava?

**What ligaments are located between the transverse processes:**

- + intertransverse ligaments;
- interspinous ligaments;
- ligamentum flava;
- ligamentum nuchae?

**The articular surfaces of the atlanto–occipital joint are:**

- + condyle of the occipital bone and superior articular facets of the atlas;
- condyle of the occipital bone and superior articular facets of the axis
- inferior articular facets of the atlas and superior articular facets of the axis;
- articular surface of the dens and inferior articular surface of the atlas?

**The articular surfaces of the median atlanto–axial joint are:**

- + anterior and posterior articular surfaces of the dens, facet for the dens of the atlas, the transverse ligament;
- the condyle of the occipital bone, superior articular surface of the atlas;
- inferior articular surface of the atlas, superior articular surface of the axis;
- anterior and posterior articular surfaces of the dens, superior articular surface of the axis.

**The articular surfaces of the lateral atlanto–axial joint are:**

- + inferior articular surface of the atlas, superior articular surface of the axis;
- anterior and posterior articular surfaces of the dens, facet for the dens of the atlas;
- condyle of the occipital bone, superior articular surface of the atlas;
- anterior and posterior articular surfaces of the dens, superior articular surface of the axis?

**The vertebral column consist of the following sections:**

- + cervical, thoracic, lumbar, sacral, coccygeal;
- cranial, thoracic, lumbar, sacral;
- cervical, thoracic, lumbar, pelvic;
- cranial, thoracic, abdominal, sacral, coccygeal.

**What physiological curvatures has the**

**vertebral column:**

- + cervical and lumbar lordosis, thoracic and sacral kyphosis, physiological thoracic scoliosis;
- cervical and lumbar kyphosis, thoracic and sacral lordosis, physiological thoracic scoliosis;
- cervical and thoracic lordosis, lumbar and sacral kyphosis, physiological thoracic scoliosis;
- cervical and lumbar scoliosis, thoracic and sacral lordosis, physiological thoracic kyphosis?

**Posteriorly convex curvature of the vertebral column is called:**

- + kyphosis;
- lordosis;
- left scoliosis;
- right scoliosis.

**Anteriorly convex curvature of the vertebral column is called:**

- + lordosis;
- kyphosis;
- left scoliosis;
- right scoliosis.

**Lateral convex curvature of the vertebral column is called:**

- + scoliosis;
- lordosis;
- kyphosis;
- side lordosis.

**The articular surfaces of the joint of the head of the rib are:**

- + articular surface of the head of the rib, costal facets of the bodies of thoracic vertebrae;
- articular surface of the head of the rib, articular surface of the tubercle of the rib;
- articular surface of the tubercle of the rib, costal facets of the bodies of thoracic vertebrae;
- articular surface of the head of the rib, costal facets of the transverse processes of thoracic vertebrae.

**The articular surfaces of the costovertebral joint are:**

- + articular surface of the tubercle of the rib, costal facet, on the transverse process of the

- thoracic vertebra;
- articular surface of the tubercle of the rib, costal facets on the bodies of the thoracic vertebrae;
- articular surface of the head of the rib, costal facets on the transverse process of the thoracic vertebra;
- articular surface of the tubercle of the rib, articular surface of the head of the rib.

***The costotransverse joint is reinforced by:***

- + costotransverse ligament;
- intertransverse ligament;
- costovertebral ligament;
- radiate ligament of the head of the rib.

***What rib unites with sternum by cartilage (synchondrosis):***

- + I rib;
- VII rib;
- I – VII ribs;
- II rib?

***The articular surfaces of the sternocostal joint are:***

- + cartilages of true ribs and costal notches of the sternum;
- articular surface of the head of the rib and costal notches of the sternum;
- articular surface of the tubercle of the rib and costal notches of the sternum;
- jugular notch of the sternum and cartilages of true ribs.

***What walls has the thoracic cage:***

- + anterior, posterior, two lateral;
- anterior, posterior, inferior and superior;
- superior, inferior and two lateral;
- anterior, posterior, medial?

***What wall of the thoracic cage is formed by thoracic vertebra and posterior end of the ribs:***

- + posterior;
- anterior;
- lateral;
- medial?

***What bones of the skull are joined by serrate sagittal suture:***

- + medial margin of the parietal bones;
- frontal and parietal bones;
- parietal and temporal bones;
- parietal and occipital bones?

***The coronoid serrate suture is located between the following bones:***

- + frontal and parietal bones;
- medial margin of the parietal bones;
- parietal and occipital bones;
- parietal and temporal bones.

***What suture is located between the temporal and parietal bone:***

- + squamous suture;
- plane suture;
- serrate suture;
- serrate sagittal suture?

***The sutura lambdoidea is located between the following bones:***

- + parietal and occipital bones;
- frontal and parietal bones;
- parietal and temporal bones;
- medial margin of the parietal bones.

***The facial skeleton bones are articulated by suture:***

- + plane suture;
- serrate suture;
- squamous suture;
- sagittal and coronal suture.

***The articular surfaces of the temporomandibular joint are:***

- + the head of the mandible, mandibular fossa of the temporal bone;
- coronoid process of the mandible and mandibular fossa of the temporal bone;
- condylar process of the mandible and mandibular fossa of the temporal bone;
- ramus of the mandible and articular tubercle of the temporal bone.

***The temporomandibular joint allows the following movement:***

- + elevation and depression, forward and backward, lateral movements of the mandible;

- only elevation and depression;
- only forward and backward;
- only lateral movements.

### **Theme 11. Connections of bones of shoulder girdle and the free upper limb**

#### ***The articular surfaces of the sternoclavicular joint are:***

- + clavicular notch of the sternum, sternal end of the clavicle;
- jugular notch of the sternum, sternal end of the clavicle;
- clavicular notch of the sternum, acromial end of the clavicle;
- jugular notch of the sternum, acromial end of the clavicle.

#### ***The articular surfaces of the acromioclavicular joint are:***

- + articular surface of the acromion and the acromial end of the clavicle;
- articular surface of the acromion and the sternal end of the clavicle;
- acromial end of the clavicle and the coracoid process;
- sternal end of the clavicle and the glenoid cavity of the scapula.

#### ***The articular surfaces of the shoulder joint are:***

- + glenoid cavity of the scapula and the head of the humerus;
- glenoid cavity of the scapula and the trochlea of the humerus;
- articular surface of the scapula and the head of the humerus;
- glenoid cavity of the scapula and the condyle of the humerus?

#### ***What structure enhances (increases) glenoid cavity of the scapula:***

- + glenoid labrum;
- articular disk;
- intraarticular ligament;
- meniscus?

#### ***What bones form the elbow joint:***

- + humerus, ulna and radius;
- humerus and ulna;
- humerus and radius;
- radius and ulna?

#### ***The elbow joint consists of the following joints:***

- + humero–ulnar, humeroradial, proximal radio–ulnar joints;
- humero–ulnar, humeroradial, distal radio–ulnar joints;
- shoulder, humero–ulnar, humeroradial joints
- humero–ulnar, proximal and distal radio–ulnar joints.

#### ***The proximal radio–ulnar joint acts simultaneously with:***

- + distal radio–ulnar joint;
- humero–ulnar joint;
- humeroradial joint;
- radiocarpal joint.

#### ***The articular surfaces of the distal radio– ulnar joint are:***

- + articular circumference of the ulna and the ulnar notch of the radius;
- circumference of the head of the radius and the radial notch of the ulna;
- trochlear of the humerus and trochlear notch of the ulna;
- trochlear of the humerus and the radial notch of the ulna.

#### ***The articular surfaces of the radiocarpal joint are:***

- + carpal articular surface of the radius, articular disc, articular surfaces of the scaphoid, lunate and triquetral bones;
- carpal articular surface of the radius, articular disc, articular surfaces of the hamate, capitate and pisiform bones;
- articular circumference of the ulna, articular disc, articular surfaces of the hamate, capitate and pisiform bones;
- styloid process of the ulna, articular disc, articular surfaces of the scaphoid, lunate and triquetral bones.

#### ***The radiocarpal joint is:***

- + compound;
- complex;
- combined;
- simple.

#### ***The articular surfaces of the midcarpal joint are:***

- + articular surfaces of carpal bones of the

- proximal and distal rows;
- carpal articular surface of the radius, articular surfaces of the scaphoid, lunate and triquetral bones;
- articular circumference of the ulna, articular surfaces of the hamate, capitate and pisiform bones;
- articular surfaces of the carpal bones of the distal row and bases of the II through V metacarpal bones.

***The articular surfaces of the metacarpophalangeal joints are:***

- + articular surfaces of the metacarpal heads and the bases of the proximal phalanges;
- articular surfaces of the metacarpal bases and the heads of the proximal phalanges;
- articular surfaces of the metacarpal heads and the bases of the distal phalanges;
- articular surfaces of the metacarpal heads and the heads of the proximal phalanges?

**Theme 12. Connections of bones of pelvic girdle and the free lower limb. The pelvis as a whole. Surgical joints of foot**

***The articular surfaces of the sacro–iliac joint are:***

- + auricular surfaces of the ilium and sacrum;
- lateral parts of the ilium and sacrum;
- iliac and sacral tuberosities;
- base of the sacrum and auricular surface of the ilium.

***What bones are articulated by the pubic symphysis:***

- + right and left pubic bones;
- ischium and pubic bones;
- ilium and pubis bones;
- right and left ischium bones?

***The pubic symphysis is:***

- + intermediate articulation;
- synovial joint;
- synchondrosis;
- synostosis.

***What parts has the pelvis:***

- + greater and lesser pelvis;
- superior and greater pelvis;
- inferior and lesser pelvis;

- greater and middle pelvis?

***The greater and lesser pelvis are separated by:***

- + linea terminalis;
- linea intermedia;
- linea arcuata;
- linea limitans.

***The posterior wall of the lesser pelvis is:***

- + pelvic surface of the sacrum and coccyx;
- body of the fifth lumbar vertebra;
- base and apex of the sacrum;
- dorsal surface of the sacrum.

***The obturator membrane covers:***

- + obturator foramen;
- greater sciatic foramen;
- lesser sciatic foramen;
- superior aperture of the pelvis.

***What anatomical structure is bounded by obturator membrane and groove:***

- + obturator canal;
- greater sciatic foramen;
- lesser sciatic foramen;
- inferior aperture of the pelvis?

***The articular surfaces of the hip joint are:***

- + lunate surface of the acetabulum and the head of the femur;
- fossa of the acetabulum and the head of the femur;
- notch of the acetabulum and the greater trochanter of the femur;
- lunate surface of the acetabulum and the greater and lesser trochanters of the femur.

***The knee joint is formed by the following bones:***

- + femur, tibia and patellar;
- femur, tibia, fibula and patella;
- femur and tibia;
- femur, tibia and fibula.

***The articular surfaces of the knee joint are:***

- + medial and lateral femoral condyles, superior articular the surface of tibia and articular surfaces of patella;
- superior articular surface of the tibia, popliteal surface of the femur, superior articular surface of the tibia and the head of

- the femur;
- medial and lateral femoral condyles and articular surfaces of patella?

***The articular surfaces of the tibiofibular joint are:***

- + the head of the fibula and fibular articular surface of the tibia;
- fibular notch of the tibia and articular surface of the lateral malleolus;
- superior articular surfaces of the tibia and the head of the fibular;
- interosseous borders of the tibia and fibula.

***What bones form the ankle joint:***

- + tibia, fibula, talus;
- tibia and talus;
- fibula and talus;
- talus and calcaneus?

***The articular surfaces of the ankle joint are:***

- + articular surfaces of the distal ends of the tibia and the fibula and trochlear articular surface of the talus;
- articular surfaces of the distal end of the tibia and trochlear articular surface of the talus;
- articular surfaces of the distal end of the fibula and trochlear articular surface of the talus;
- articular surfaces of the talus and calcaneus.

***The articular surfaces of the subtalar joint are:***

- + posterior articular surfaces of the talus and the calcaneus;
- anterior articular surfaces of the talus and the calcaneus;
- middle articular surfaces of the talus and the calcaneus;
- posterior articular surfaces of the talus and middle articular surfaces of the calcaneus.

***The "key" of the Chopart's joint is:***

- + bifurcate ligament;
- plantar tarsal ligament;
- long plantar ligament;
- medial cuneometatarsal ligament.

***What curvatures (arches) are distinguished in the foot:***

- + 5 longitudinal and 1 transverse curvatures;

- 1 longitudinal and 1 transverse curvatures;
- 5 longitudinal and 5 transverse curvatures;
- 1 longitudinal and 5 transverse curvatures?

**Theme 13. Muscles and fascias of the chest and the back. The diaphragm**

***How many layers are muscles of the back arranged in:***

- + 2 layers;
- 3 layers;
- 5 layers;
- 1 layer?

***Name muscles of the first layer of the superficial muscles of the back:***

- + latissimus dorsi and trapezius muscles;
- rhomboid major and rhomboid minor muscles;
- latissimus dorsi and levator scapulae muscles;
- trapezius, superior posterior serratus and inferior posterior serratus muscles.

***Name muscles of the second layer of the superficial muscles of the back:***

- + rhomboid major, rhomboid minor and levator scapula muscles;
- trapezius, serratus superior posterior and posterior inferior muscles;
- posterior superior and posterior inferior serratus muscles;
- latissimus dorsi and trapezius muscles.

***Name muscles of the third layer of the superficial muscles of the back:***

- + superior posterior and inferior posterior serratus muscles;
- latissimus dorsi and trapezius muscles;
- rhomboid major and rhomboid minor muscles;
- trapezius and levator scapulae muscles.

***What is the action on contraction of all fibres of the trapezius muscle:***

- + pulls the scapula to the spine;
- elevates the lateral angle of the scapula;
- extends the head and bends the head and the neck backwards;
- elevates the inferior angle of the scapula?



**What is the action of the latissimus dorsi muscle:**

- + extends, adducts, and medially rotates the arm;
- flexes, abducts, and laterally rotates the arm;
- pulls the scapula to the median line;
- extends the lumbar segment of the spine?

**What is the action of the levator scapulae muscle:**

- + elevates the scapula, pulls the scapula medially, bends the cervical portion of spine to the same direction when the scapula is fixed;
- elevates the scapula, pulls the scapula laterally;
- rotates the scapula upward;
- pulls the scapula downward and laterally?

**What is the action of the rhomboid major muscle:**

- + elevates the scapula, pulls the scapula medially, stabilizes the scapula;
- pulls the scapula downward;
- pulls the scapula laterally;
- extends the cervical segment of spine?

**What is the action of the rhomboid major and minor muscles:**

- + pull the scapula upward and medially;
- pull the scapula downward;
- pull the scapula laterally;
- extend the cervical segment of spine?

**What is the action of the serratus posterior superior muscle:**

- + raises the ribs (inhalation);
- pulls the ribs downwards (exhalation);
- pulls the scapula downwards;
- elevates the scapula?

**What is the action of the serratus posterior inferior muscle:**

- + pulls lower ribs downwards (exhalation);
- raises the ribs (inhalation);
- pulls the scapula downwards
- pulls the scapula upwards?

**Which fascia covers the deep muscles of the**

**back:**

- + the thoracolumbar fascia;
- the thoracocervical fascia;
- the superficial fascia;
- the deep fascia of the back?

**What are the layers of deep muscles of the back:**

- + superficial, middle, and deep layers;
- medial and lateral layers;
- superficial and medial layers;
- medial, middle, lateral layers?

**What portions the erector spinae muscle consists of:**

- + lateral, intermediate and medial tracts;
- superficial and deep tracts;
- cervical, thoracic and lumbar tracts;
- medial and lateral tracts?

**How is the lateral tract (group) of erector spinae muscle named:**

- + the iliocostalis muscle;
- the spinalis muscle;
- the longissimus muscle;
- the transversospinalis muscle?

**How is the intermediate tract (group) of erector spinae muscle named:**

- + the longissimus muscle;
- the iliocostalis muscle;
- the spinalis muscle;
- the transversospinalis muscle?

**How is the medial tract (group) of erector spinae muscle named:**

- + the spinalis muscle;
- the longissimus muscle;
- the iliocostalis muscle;
- the transversospinalis muscle?

**Which fascia covers the superficial group of the muscles of the back:**

- + common superficial (subcutaneous) fascia;
- thoracolumbar fascia;
- thoracocervical fascia;
- deep fascia of the back?

**Name the superficial layer of muscles of the chest:**

- + the pectoralis major and minor muscles, subclavius muscle and serratus anterior muscle;
- the pectoralis major and minor muscles, the diaphragm;
- the serratus anterior muscle, external intercostal muscles;
- the external and internal intercostal muscles, pectoralis major and minor muscles.

**Name the deep layer of muscles of the chest:**

- + the external and internal intercostal muscles, subcostal muscles, transverse thoracic muscle;
- the pectoralis major and minor muscles, diaphragm;
- the external and internal intercostal muscles, serratus anterior muscle;
- the subclavius muscle, the diaphragm.

**Which muscle is the most important muscle for breathing:**

- + the diaphragm;
- the pectoralis major muscle;
- the transversus thoracic muscle;
- the serratus anterior muscle?

**Which parts are distinguished in the pectoralis major muscle with regard to their origin:**

- + the clavicular, sternocostal and abdominal parts;
- the clavicular, acromial and sternocostal parts;
- the clavicular and abdominal parts;
- the costal, acromial and abdominal parts?

**What is the action of the pectoralis major muscle:**

- + adducts and medially rotates the arm, raises ribs when the upper limbs are raised (inspiration);
- abducts and laterally rotates the arm;
- extends and medially rotates the arm;
- flexes and laterally rotates the arm?

**What is the action of the pectoralis minor muscle:**

- + pulls the scapula forward and downward;
- pulls the scapula backward and upward;

- pulls the clavicle downward;
- flexes the arm?

**What is the action of the subclavius muscle:**

- + pulls the clavicle down and medially;
- pulls the clavicle backward;
- pulls the scapula down and medially;
- pulls the scapula backward?

**What is the action of the serratus anterior muscle:**

- + draws the scapula forward and laterally, rotates it as occurs in lifting the upper limb above the shoulder;
- draws the scapula down and medially, abducts the arm to the horizontal level;
- draws the scapula forward, flexes the arm forward;
- draws the scapula backward, rotates the arm medially?

**What is the action of the external intercostal muscles:**

- + elevates the ribs and increases the dimensions of the thoracic cavity (inhalation);
- draws the ribs down (exhalation);
- draws the ribs medially and downward (inhalation);
- draws the ribs laterally and downward (exhalation)?

**Where do the internal intercostal muscles originate:**

- + from the superior border of the ribs below;
- from the inferior border of the ribs above;
- from the external surface of the costal cartilages;
- from the internal surface of the costal cartilages?

**Where do the internal intercostal muscles attach:**

- + to the inferior border of the ribs above;
- to the superior border of the ribs below;
- to the anterior surface of the costal cartilages;
- to the internal surface of the costal cartilages?

**What is the action of the internal intercostal muscles:**

- + draw the ribs downward, decrease dimensions of the thoracic cavity (exhalation);
- elevate the ribs, increase dimensions of the thoracic cavity (inhalation);
- elevate the ribs upward and medially (inhalation);
- draw the ribs upward and laterally (inhalation)?

**What is the action of the subcostal muscles:**

- + draw the ribs downward (exhalation);
- elevate the ribs (inhalation);
- draw the ribs upward and medially (inhalation);
- draw the ribs upward and laterally (exhalation)?

**What is the action of the transversus thoracic muscle:**

- + draws the ribs down (exhalation);
- elevates the ribs (inhalation);
- draws the ribs upward and medially (exhalation);
- draws the ribs upward and laterally (inhalation)?

**Which are fasciae of the chest:**

- + the pectoral, clavipectoral, thoracic and endothoracic fascia;
- the pectoral fascia, the external and internal intercostal membranes;
- the clavipectoral and intercostal fasciae, the internal sternal membrane;
- the clavipectoral, clavisternal and endothoracic fascia?

**What fascia lines the inner surface of the thoracic cavity:**

- + the endothoracic fascia;
- the thoracic fascia;
- the pectoral fascia;
- the clavipectoral fascia?

**What muscle forms the partition between the thoracic and abdominal cavities:**

- + the diaphragm;
- the transversus thoracic muscle;
- the subcostal muscles;

- the pectoral major muscle?

**How does the diaphragm act as a result of contraction:**

- + contraction of the diaphragm causes it to flatten and increases the vertical dimension of the thoracic cavity, resulting in inhalation;
- contraction of the diaphragm causes it to move superiorly and decreases the vertical dimension of the thoracic cavity, resulting in exhalation;
- draws the ribs downward, resulting in exhalation;
- elevates the ribs, resulting in inhalation?

**Theme 14. Muscles and fascias of abdomen.**

**The rectus abdominis muscle sheath. The linea alba of the abdomen. The umbilical ring. The inguinal canal**

**Name the groups of muscles of the abdomen:**

- + the anterior, lateral and posterior groups;
- the medial and lateral groups;
- the anterior, posterior and superior groups;
- the superior, inferior and anterior groups.

**Name the anterior group of muscles of the abdomen:**

- + the rectus abdominis and pyramidalis muscles;
- the rectus abdominis and transversus abdominis muscles;
- the external and internal oblique muscles;
- the rectus abdominis and quadratus muscle of the loins?

**Name the posterior group of muscles of the abdomen:**

- + the quadratus muscle of the abdomen;
- the transversus abdominis muscle;
- the pyramidalis muscle;
- the external and internal oblique muscles.

**Name the lateral group of muscles of the abdomen:**

- + the external oblique, internal oblique and transversus abdominis muscles;
- the external oblique, internal oblique and rectus abdominis muscles;
- the transversus abdominis and pyramidalis muscles;
- the transversus abdominis and quadratus

muscle of the loin.

**How is the free inferior border of the aponeurosis of the external oblique muscle named:**

- + the inguinal ligament (Poupart's ligament);
- the linea alba;
- the interfoveolar ligament;
- the transversus ligament?

**What movements does the external oblique muscle carry out when acting singly (unilaterally):**

- + rotates the trunk to the contralateral side;
- rotates the trunk to the same side;
- elevates the lower ribs;
- flexes the trunk?

**What movements do the external oblique muscles carry out when acting together (bilaterally):**

- + flex the spine, pull the ribs downward;
- extend the spine, elevate the ribs;
- rotate the trunk to the right and left;
- pull the ribs downward, extend the spine?

**The anterior bundles of the internal oblique muscle are continuous with:**

- + with the aponeurosis of the internal oblique muscle;
- with the cremaster muscle;
- with the inguinal ligament;
- with the umbilical ring?

**Which movements does the internal oblique muscle carry out acting singly (unilaterally):**

- + rotates the trunk to the same side, draws the ribs downward;
- rotates the trunk to the contralateral side, elevates the ribs;
- rotates the trunk to the same side, elevates the ribs;
- flexes the vertebral column?

**Which movements do the internal oblique muscles carry out, acting together (bilaterally):**

- + flex the vertebral column;
- extend the vertebral column;
- rotate the trunk to the same side;
- rotate the trunk to the contralateral side?

**Which of muscles of the lateral group of**

**abdominal muscles is the deepest:**

- + the transversus abdominis muscle;
- the internal oblique muscle;
- the external oblique muscle;
- the rectus abdominis muscle.

**What is the action of the transversus abdominis muscle:**

- + narrows the abdominal cavity, forming the abdominal press, draws the ribs forward and medially;
- narrows the abdominal cavity, forming the abdominal press, elevates the ribs;
- rotates the trunk to the same side;
- rotates the trunk to the contralateral side.

**What structure passes between two rectus abdominis muscles:**

- + the linea alba;
- the arcuate line;
- the semilunar line;
- the inguinal ligament.

**What is the action of the rectus abdominis muscle:**

- + flexes the vertebral column, draws the ribs downward;
- extends the vertebral column, elevates the ribs;
- extends the vertebral column, rotates the vertebral column to the same side;
- rotates the vertebral column to the right and left.

**Which of muscles of the abdomen has tendinous intersections:**

- + the rectus abdominis muscle;
- the transversus abdominis muscle;
- the external oblique muscle;
- the pyramidalis muscle.

**Where is the pyramidalis muscle located:**

- + in front of the inferior part of the rectus abdominis muscle, under the anterior wall of the sheath of the rectus abdominis;
- in front of the superior part of the rectus abdominis muscle, attaches to the 1st tendinous intersection;
- behind the inferior part of the rectus

abdominis muscle, attaches to the inguinal ligament;

- behind the superior part of the rectus abdominis muscle, under the posterior wall of the sheath of the rectus abdominis.

***What is the action of the quadratus lumborum muscle, when acting together:***

- + pulls the 12th rib inferiorly (exhalation), helps to extend the lumbar portion of the spine;
- pulls the 12th rib superiorly (inhalation), flexes the lumbar portion of the spine;
- rotates the vertebral column to the same side;
- rotates the vertebral column to the contralateral side?

***What does the endoabdominal fascia line:***

- + the whole inner surface of the abdominal wall;
- the rectus abdominis muscle;
- the internal oblique muscle of the abdomen;
- all anterolateral muscles of the abdomen.

***The muscles of the abdomen are covered with fascia:***

- + the proper fascia of the abdomen;
- the inguinal fascia;
- the deep fascia;
- the psoatic fascia.

***The transversalis fascia is a part of:***

- + the endoabdominal fascia, it is located under the transversus abdominis muscles;
- the proper fascia, it is located above the transversus abdominis muscle;
- the superficial fascia of the abdomen, it is located between the transversus abdominis and internal oblique muscles;
- the endoabdominal fascia, it is located between the internal and external oblique muscles of the abdomen.

***The aponeuroses of the broad muscles of the abdomen fuse on the midline and form:***

- + the linea alba;
- the arcuate line;
- the semilunar line;
- the inguinal canal.

***Where is the linea alba extended:***

- + between the xiphoid process of the sternum and the pubic symphysis;
- between the right and left anterior superior iliac spines;
- between the pubic symphysis and anterior superior iliac spines (right and left);
- between the umbilical ring and anterior superior iliac spines (right and left).

***What structure is almost in the middle of the linea alba:***

- + the umbilical ring;
- the deep inguinal ring;
- the superficial inguinal ring;
- the adminiculum lineae albae.

***What walls has the sheath of the rectus abdominis muscle:***

- + the anterior and posterior walls;
- the superior and inferior walls;
- the medial and lateral walls;
- the superficial and deep walls.

***What structure passes through the inguinal canal in the male:***

- + the spermatic cord;
- the umbilical vein;
- the umbilical artery;
- the round ligament.

***What structure passes through the inguinal canal in the female:***

- + the round ligament;
- the spermatic cord;
- the umbilical vein;
- the umbilical artery.

***What inguinal ring is in the posterior wall of the inguinal canal at the level of the lateral inguinal fossa:***

- + the deep inguinal ring;
- the superficial inguinal ring;
- the inferior inguinal ring;
- the superior inguinal ring.

***What are the vertical folds of the peritoneum on the posterior surface of the anterior abdominal wall:***

- + the lateral and medial umbilical folds and median umbilical fold;
- the superior and inferior umbilical folds;
- the lateral and medial umbilical folds;
- the median, deep and superficial umbilical folds.

**Theme 15. Muscles and fasciae of the head. Muscles and fasciae of the neck. Interfacial spaces. Topography of the neck**

***The muscle of the head can be divided into two groups:***

- + muscles of mastication and muscles of facial expression;
- superficial and deep muscles;
- facial and deep muscles;
- muscles of the mandible and muscles of the skull.

***The occipitofrontalis part of the epicranius muscle is made up of two bellies:***

- + frontal and occipital;
- frontoparietal and occipitoparietal;
- frontotemporal and occipitotemporal;
- lateral bellies.

***What is the action of the frontal belly of the occipitofrontalis muscle:***

- + raises eyebrows, draws the scalp anteriorly, wrinkles the skin of forehead horizontally;
- draws eyebrows inferiorly and causes vertical wrinkles above the bridge of the nose;
- raises eyebrows and wrinkles the skin of the forehead vertically;
- draws the galea aponeurotica posteriorly.

***What is the action of the occipital belly of the occipitofrontalis muscle:***

- + draws the scalp posteriorly;
- draws the scalp anteriorly;
- wrinkles the skin of the occipital region horizontally;
- raises eyebrows, draws the scalp anteriorly?

***Which of the muscles are around the auricle:***

- + the auricularis anterior, superior and posterior muscles;

- the temporoparietalis and auricularis posterior muscles;
- the procerus, auricularis anterior and posterior muscles;
- the auricularis superior and corrugator supercilii muscles?

***What group of muscles of facial expression is poor developed in the human:***

- + muscles surrounding the auricle;
- muscles of the scalp;
- muscles around the mouth;
- muscles surrounding the nose?

***Which of the muscles are around the orbit:***

- + the orbicularis oculi and corrugator supercilii muscles;
- the orbicularis oculi and procerus muscles;
- the corrugator supercilii, occipitofrontalis and orbicularis oculi muscles;
- the orbicularis oculi, nasal and procerus muscles?

***Which of the muscles are around the nose:***

- + the nasal muscle and the depressor septi nasi muscles;
- the nasal, zygomaticus minor and major muscles;
- the depressor septi nasi and levator labii superioris muscles;
- the nasal and buccinator muscles?

***Which parts has the nasal muscle:***

- + the transverse and alar parts;
- the transverse and vertical parts;
- the medial and lateral parts;
- the external and internal parts?

***The orbicularis oris muscle consists of two parts:***

- + the labial and marginal;
- the superficial and deep;
- the labial and internal;
- the marginal and central.

***What is the action of the orbicularis oris muscle:***

- + closes and protrudes lips, compresses lips against teeth, and shapes lips during speech;

- opens the mouth;
- pulls the angle of the mouth upward and laterally: it is the most important in laughing;
- pulls the angle of the mouth downward and laterally?

***What muscles are the most important in the expression of laughter on the face:***

- + the zygomaticus major and risorius (often absent) muscles;
- the zygomaticus major and minor muscles;
- the orbicularis oris and risorius (often absent) muscles;
- the buccinator and levator anguli oris muscles?

***Which of the muscle is a quadrangular muscle forming the lateral wall of the oral cavity:***

- + the buccinator muscle;
- the zygomaticus major muscle;
- the orbicularis oris muscle;
- the lateral pterygoid muscle?

***Name muscles of mastication:***

- + the masseter, temporal, medial and lateral pterygoid muscles;
- the masseter, buccinator and medial pterygoid muscles;
- the temporal, zygomaticus major and minor muscles;
- the masseter, zygomaticus major and minor muscles.

***What is the action of the temporal muscle:***

- + elevates the mandible (biting), posterior bundles retract mandible;
- lowers the mandible, posterior bundles retract the mandible;
- elevates the mandible, draws mandible laterally;
- lowers the mandible, moves the mandible from side to side?

***What is the action of the masseter muscle:***

- + elevates and protracts (draws forward) the mandible;

- elevates and retracts (draws back) the mandible;
- elevates mandible and moves it from side to side;
- depresses and protracts (draws forward) the mandible?

***What is the action of the lateral pterygoid muscle:***

- + acting singly, displaces the mandible to the contralateral side; acting together, protracts (draws forward) the mandible;
- acting singly, protracts (draws forward) the mandible; acting together retracts (draws back) the mandible;
- elevates the mandible and moves it from side to side;
- depresses the mandible, moves it to the contralateral side?

***What is the action of the medial pterygoid muscle:***

- + elevates, protracts (draws forward) displaces the mandible to the contralateral side;
- displaces the mandible forward and backward
- elevates, retracts (draws back), displaces the mandible to the same side;
- depresses and displaces the mandible to the contralateral side;

***What structures does the buccopharyngeal fascia enclose:***

- + the buccinator muscle and lateral wall of the pharynx;
- the medial and lateral pterygoid muscles;
- the masseter muscle and lateral wall of the pharynx;
- all muscles of facial expression and lateral wall of the pharynx?

***Which structure is the temporal fascia covered by:***

- + the temporal muscle;
- the masseter muscle and the parotid salivary gland;
- all muscles of mastication;
- all muscles of facial expression?

***Which fascia are the muscles of facial***

**expression covered by:**

- + they are devoid of fasciae, except the buccinator muscle;
- the buccopharyngeal fascia;
- the temporal fascia;
- the buccopharyngeal and parotid fasciae?

**Name groups of muscles of the neck:**

- + the superficial, deep group and middle muscles (muscles of the hyoid bone);
- the anterior, lateral group and muscles of the mandible;
- the lateral, medial group and muscles of the sternum;
- the anterior, posterior and lateral group.

**The superficial muscles of the neck are:**

- + the sternocleidomastoid and platysma muscles;
- the platysma, digastric, anterior, middle and posterior scalene muscles;
- the sternocleidomastoid, longus cervicis and longus capitis muscles;
- the platysma, mylohyoid, rectus capitis anterior and lateralis muscles.

**The deep lateral muscles of the neck are:**

- + the anterior, middle and posterior scalene muscles
- the medial, lateral and median scalene muscles;
- the superior and inferior scalene muscles;
- the anterior and posterior scalene, longus cervicis and capitis muscles.

**The group of the suprahyoid muscles is:**

- + the digastric, mylohyoid, stylohyoid and geniohyoid muscles;
- the digastric, thyrohyoid, omohyoid and geniohyoid muscles;
- the omohyoid, digastric, stylohyoid and platysma muscles;
- the mylohyoid, digastric, anterior scalene and sternothyroid muscles.

**The group of the infrahyoid muscles is:**

- + the sternohyoid, sternothyroid, thyrohyoid and omohyoid muscles;
- the digastric, stylohyoid, mylohyoid and geniohyoid muscles;
- the sternohyoid, sternothyroid, anterior and lateral scalene muscles;

- the omohyoid, thyrohyoid, digastric and stylohyoid muscles?

**What is the action of the platysma muscle:**

- + pulling the skin of the neck, it protects the subcutaneous veins from compression; depresses the angle of the mouth;
- draws the angle of the mouth laterally (it is the most important while laughing);
- depresses the mandible;
- elevates the hyoid bone and floor of the mouth?

**What is the action of the sternocleidomastoid muscle during unilateral contraction:**

- + laterally flexes the head to the same side, and the face is turned to the opposite side;
- laterally flexes the head to the opposite side, and the face is turned to the same side;
- flexes the head anteriorly and to the same side;
- flexes the head anteriorly and to the opposite side?

**What is the action of the sternocleidomastoid muscles during bilateral contraction:**

- + flex the cervical portion of spine, extend the head (head-holder), and elevate the sternum during forced inhalation;
- flex the head anteriorly and to the same side;
- flex the head anteriorly and to the opposite side;
- elevate the mandible?

**What is the name of the structure above the clavicle between the lateral and medial limbs of the sternocleidomastoid muscle:**

- + the supraclavicularis minor fossa;
- the supraclavicularis major fossa;
- the suprasternal fossa;
- the cervical minor fossa?

**What is the action of the digastric muscle:**

- + elevates the hyoid bone; depresses the mandible, when the hyoid bone is steadied;
- elevates the mandible, when the hyoid bone is steadied;
- depresses the hyoid bone, raises the tongue during swallowing;
- elevates the mandible, raises the tongue



during swallowing?

**What is the origin and insertion of the stylohyoid muscle:**

- + the styloid process of the temporal bone; the body of the hyoid bone;
- the body of the hyoid bone; the styloid process of the temporal bone;
- the body of the hyoid bone; the mastoid notch of the temporal bone;
- the mastoid notch of the temporal bone; the body of the hyoid bone?

**What is the action of the stylohyoid muscle:**

- + acting together, draws the hyoid bone upward and backward acting singly, draws it to the same side;
- acting together, draws the hyoid bone downward and backward;
- acting singly, draws it to the contralateral side;
- depresses the mandible;
- elevates the mandible, raises the tongue during swallowing?

**What structures are located above the mylohyoid muscle:**

- + the geniohyoid muscle and sublingual salivary gland;
- the anterior belly of the digastric muscle and submandibular salivary gland;
- the posterior belly of the digastric muscle and sublingual salivary gland;
- the sublingual and submandibular salivary gland?

**What is the action of the geniohyoid muscle if the fixed point of its attachment is located on the hyoid bone:**

- + depresses the mandible as in opening the mouth;
- elevates the mandible as in closing the mouth;
- depresses the hyoid bone;
- elevates the hyoid bone?

**What is the action of the thyrohyoid muscle:**

- + depresses the hyoid bone or elevates the larynx (depending on fixed point);
- depresses the larynx and hyoid bone

(depending on fixed point);

- elevates the hyoid bone;
- depresses the larynx?

**What is the action of the longus cervicis, longus capitis and rectus capitis anterior muscles:**

- + flex the head and cervical spine forward;
- extend the cervical spine and the head backward;
- flex the cervical spine to the same side;
- flex the cervical spine to the opposite side?

**What is the action of the rectus capitis lateralis muscle:**

- + flexes the head to the same side;
- flexes the head to the opposite side;
- flexes the cervical spine forward;
- extends the cervical spine backward?

**Name the space located above the manubrium of sternum between the superficial and pretracheal layers of the cervical fasciae:**

- + the suprasternal interaponeurotic space;
- the superficial space;
- the suprajugular interaponeurotic space;
- the supraclavicular interaponeurotic space.

**The neck is divided into regions:**

- + the anterior, sternocleidomastoid (right and left), lateral (right and left) and posterior regions;
- the anterior, posterior and medial regions;
- the submandibular, sternocleidomastoid (right and left) and lateral (right and left) regions;
- the anterior, submandibular, carotid, submental and posterior regions?

**The anterior region of the neck is bounded laterally:**

- + by the anterior margins of the two sternocleidomastoid muscles;
- by the anterior margins of the two trapezius muscles;
- by the omohyoid muscles;
- by the posterior margins of the two sternocleidomastoid muscles.

**The anterior midline of the neck divides the anterior region of the neck into trigones:**

- + the right and left medial trigones;
- the right and left medial and lateral trigones;
- the right and left carotid and lateral trigones;
- the right and left submandibular, carotid, lingual and omoclavicular trigones.

**Which trigone of the neck is bounded superiorly by the base of the mandible:**

- + the submandibular;
- the lingual;
- the mental;
- the carotid?

**The lingual trigone (Pirogov's trigone) is located in the area of:**

- + the submandibular trigone;
- the mental trigone;
- the carotid trigone;
- the muscular (omotracheal) trigone?

**Where can one bandage the lingual artery when damaging the tongue:**

- + in the lingual trigone;
- in the mental trigone;
- in the submandibular trigone;
- in the carotid trigone?

**What trigones are distinguished in the lateral region of the neck:**

- + the omoclavicular and omotrapezoid trigones;
- the submandibular, claviculoscapular and muscular trigones;
- the carotid, submandibular and omotrapezoid trigones;
- the submandibular, lingual, omoclavicular and muscular trigones?

**Triangular spaces that are formed between the muscles of the neck, they are:**

- + the spatium interscalene and spatium antescalenum;
- the spatium antescalenum and spatium retroscalenum;
- the spatium antescalenum and spatium presternohyoid;
- the spatium presternohyoid and spatium intersternohyoid?

**The posterior region of the neck is behind the lateral border of:**

- + the trapezius muscle;
- the latissimus dorsi muscle;
- the longus cervicis and longus capitis muscles;
- the suboccipital group of the cervical muscles.

**What is the region of the neck corresponding to the projection of the muscle of the same name:**

- + the sternocleidomastoid region;
- the subcutaneous region;
- the omohyoid region;
- the sternohyoid region?

**The fascia cervicalis is divided into layers as follows:**

- + 3 layers: the superficial, pretracheal and prevertebral;
- 2 layers: the superficial and prevertebral;
- 5 layers: the superficial, proper, endocervical, pretracheal and prevertebral;
- 2 layers: the superficial and endocervical.

**The superficial layer of fascia cervicalis forms fascial sheaths for the following muscles of the neck:**

- + the sternocleidomastoid and trapezius muscles;
- the sternocleidomastoid and infrahyoid group of muscles of the neck;
- the platysma muscle;
- the suprahyoid and infrahyoid groups of muscles of the neck.

**The pretracheal layer of the fascia cervicalis is stretched like a trapezium between the following muscles of the neck:**

- + the omohyoid muscles;
- the digastric muscles;
- the sternohyoid muscles;
- the sternothyroid and thyrohyoid muscles.

**The prevertebral layer of the fascia cervicalis covers muscles of the neck forming sheaths for these muscles:**

- + the deep group;
- the suprahyoid group;
- the infrahyoid group;
- the transversospinalis.

## **Theme 16. Muscles of the shoulder girdle and the upper limb**

### ***Muscles of the shoulder joint region are:***

- + the deltoid, supraspinatus, infraspinatus, teres minor and major, subscapularis muscles;
- the deltoid, rhomboid major and minor, teres minor and major muscles;
- the deltoid, supraspinatus and infraspinatus, subscapularis and suprascapularis muscles;
- the deltoid, subscapularis, subclavius, teres minor and major muscles.

### ***Where does the deltoid muscle attach:***

- + to the deltoid tuberosity of the humerus;
- to the greater tubercle of the humerus;
- to the clavicle;
- to the acromion of the scapula?

### ***What is the action of the whole deltoid muscle:***

- + abducts the arm from the trunk to 70 degrees, forms protective and reinforced vault of the shoulder joint;
- adducts the arm and forms the vault of the shoulder joint;
- flexes the arm and rotates it medially;
- extends the arm and rotates it laterally?

### ***Which muscle located superficially covers the shoulder joint with lateral, anterior, superior and posterior sides:***

- + the deltoid muscle;
- the supraspinatus muscle;
- the teres major muscle;
- the infraspinatus muscle?

### ***What is the origin of the supraspinatus muscle:***

- + the supraspinous fossa of the scapula;
- the spine of the scapula;
- the anterior (costal) surface of the scapula;
- the medial border of the scapula?

### ***What is the action of the supraspinatus muscle:***

- + abducts the arm at the shoulder joint;

- adducts the arm at the shoulder joint;
- rotates the arm medially (pronation);
- rotates the arm laterally (supination)?

### ***What is the origin of the infraspinatus muscle:***

- + the infraspinous fossa and infraspinous fascia;
- the spine of the scapula and infraspinous fascia;
- the lateral border of scapula;
- the acromion of scapula?

### ***What is the action of the infraspinatus muscle:***

- + laterally rotates the arm (supination);
- medially rotates the arm (pronation);
- flexes the arm and medially rotates;
- extends the arm and laterally rotates?

### ***What is the action of the teres minor muscle:***

- + laterally rotates the arm (supination);
- medially rotates the arm (pronation);
- flexes and medially rotates the arm;
- extends and laterally rotates the arm?

### ***What is the action of the teres major muscle:***

- + extends, adducts and medially rotates the arm at shoulder joint;
- flexes and laterally rotates the arm at shoulder joint;
- laterally rotates the arm at shoulder joint;
- abducts the arm above the horizontal level?

### ***What is the origin of the subscapularis muscle:***

- + the subscapular fossa of the scapula;
- the dorsal surface of the scapula;
- the inferior angle and spine of the scapula;
- the medial border of the scapula?

### ***What is the action of the subscapularis muscle:***

- + adducts and medially rotates the arm (pronation);
- laterally rotates the arm (supination);
- abducts the arm from the trunk to 70 degrees;
- flexes the arm?

### ***Muscles of the upper arm are divided into groups:***

- + anterior muscles (flexors) and posterior muscles;
- anterior muscles (extensors) and posterior

- muscles (flexors) of the upper arm;
- medial muscles (pronators) and lateral muscles (supinators) of the upper arm;
- superficial muscles (flexors) and deep muscles (extensors) of the upper arm.

**Anterior muscles of the upper arm are:**

- + the biceps brachii, coracobrachialis and brachialis muscles;
- the biceps brachii and triceps brachii muscles;
- the biceps brachii, brachialis and brachioradialis muscles;
- the biceps brachii, deltoid and brachialis muscles.

**Posterior muscles of the upper arm are:**

- + the triceps brachii and anconeus muscles;
- the triceps brachii and biceps brachii muscles;
- the triceps brachii, brachialis and brachioradialis muscles;
- the biceps brachii, brachialis and coracobrachialis muscles.

**The biceps brachii muscle consists of two heads:**

- + the long and short heads;
- the lateral and medial heads;
- the superficial and deep heads;
- the superior and inferior heads.

**Where does the long head of the biceps brachii muscle arise:**

- + from the supraglenoid tubercle of the scapula;
- from the infraglenoid tubercle of the scapula;
- from the coracoid process of the scapula;
- from the acromion of the scapula?

**What is the action of the biceps brachii muscle:**

- + flexes the arm and forearm, supinates the forearm;
- extends the arm and forearm, supinates the forearm;
- flexes the arm and extends the forearm, pronates the forearm;
- extends the arm and flexes the forearm, supinates the forearm?

**What is the action of the coracobrachialis**

**muscle:**

- + flexes and adducts the arm, supinates the arm if it was pronated;
- extends the arm, supinates the arm, if it was pronated;
- abducts the arm from the trunk to the horizontal level;
- adducts the arm to the trunk, pronates the arm?

**The triceps brachii muscle consists of three heads:**

- + the long, lateral and medial heads;
- the long, short and medial heads;
- the superficial, deep and lateral heads;
- the long, superior and inferior heads.

**What is the action of the triceps brachii muscle:**

- + extends and adducts the arm at the shoulder joint and extends the forearm at the elbow joint;
- flexes the arm and forearm;
- extends the arm at the shoulder joint and flexes the forearm at the elbow joint;
- flexes and adducts the arm at the shoulder joint and extends the forearm at the elbow joint?

**What is the action of the anconeus muscle:**

- + extends the forearm at the elbow joint;
- flexes the forearm at the elbow joint;
- pronates the forearm;
- supinates the forearm?

**Muscles of the forearm are separated into two groups according to their position:**

- + the anterior group or flexors and pronators, the posterior group or extensors and supinator;
- the anterior group or extensors, the posterior group or flexors;
- the superficial group or flexors, the deep group or extensors;
- the medial group or flexors and supinators, the lateral group or extensors and pronators.

**How many layers have muscles of the anterior**

**group of muscles of the forearm:**

- + 4 layers;
- 2 layers;
- 5 layers;
- 1 layer?

**What muscles form the 1st layer of the anterior group of muscles of the forearm:**

- + the pronator teres, flexor carpi radialis, palmaris longus, flexor carpi ulnaris muscles;
- the pronator teres, flexor carpi radialis, brachioradialis, flexor digitorum superficialis muscles;
- the pronator teres, flexor carpi radialis, flexor carpi ulnaris, flexor pollicis longus muscles;
- the pronator teres, brachioradialis, flexor carpi ulnaris, pronator quadratus muscles?

**What muscles form the 2nd layer of the anterior group of muscles of the forearm:**

- + the flexor digitorum superficialis muscle;
- the flexor carpi radialis and flexor carpi ulnaris muscles;
- the brachioradialis muscle;
- the flexor pollicis longus muscle?

**What muscles form the 3rd layer of the anterior group of muscles of the forearm:**

- + the flexor pollicis longus and flexor digitorum profundus muscles;
- the flexor digitorum superficialis and flexor digitorum profundus muscles;
- the pronator quadratus muscle;
- the pronator teres and pronator quadratus muscles?

**What muscles form the 4th layer of the anterior group of muscles of the forearm:**

- + the pronator quadratus muscle;
- the pronator teres muscle;
- the flexor pollicis longus and flexor digitorum profundus muscles;
- the flexor digitorum superficialis and flexor digitorum profundus muscles?

**Where do all muscles of the anterior group of muscles of the forearm arise, except the pronator quadratus muscle:**

- + from the medial epicondyle of humerus;

- from the lateral epicondyle of humerus;
- from the capsule of the shoulder joint;
- from the anterior surfaces of ulna and radius and capsule of radiocarpal joint?

**What is the action of the pronator teres muscle:**

- + pronates the forearm at radioulnar joints, flexes forearm at elbow joint;
- supinates forearm at radioulnar joint;
- extends and abducts the hand at wrist joint;
- pronates and flexes the arm at shoulder joint?

**What is the action of the flexor carpi radialis muscle:**

- + flexes and abducts the hand (radial deviation) at the wrist joint;
- flexes and adducts the hand, supinates the forearm;
- extends and abducts the hand at the wrist joint;
- tenses the palmar aponeurosis and weakly flexes the hand at the wrist joint?

**What is the action of the palmaris longus muscle:**

- + tenses the palmar aponeurosis and weakly flexes the hand at the wrist joint;
- relaxes the palmar aponeurosis;
- extends the hand at the wrist joint and pronates the forearm;
- supinates the forearm together with the hand?

**What is the action of the flexor carpi ulnaris muscle:**

- + flexes and adducts the hand (ulnar deviation) at the wrist joint;
- extends and abducts the hand at the wrist joint;
- tenses the palmar aponeurosis and weakly flexes the hand at the wrist joint;
- flexes the hand at the wrist joint and flexes the distal phalanx of little finger?

**What is the action of the flexor digitorum superficialis muscle:**

- + flexes middle phalanges of the 2nd – 5th

- fingers, flexes the hand at the wrist joint;
- flexes distal phalanges of the 2nd– 5th fingers, flexes the hand at the wrist joint;
- flexes middle phalanges of the 1st – 5th fingers, extends the hand at the wrist joint;
- flexes all phalanges of the 1st – 5th fingers, flexes the hand at the wrist joint?

***What is the action of the flexor digitorum profundus muscle:***

- + flexes distal phalanges of the 2nd – 5th fingers, flexes the hand at the wrist joint;
- flexes middle phalanges of the 2nd – 5th fingers;
- flexes proximal phalanges of the 1st – 5th fingers, flexes the hand at the wrist joint;
- flexes proximal and middle phalanges of the 1st – 5th fingers, flexes the hand at the wrist joint?

***What is the action of the flexor pollicis longus muscle:***

- + flexes the distal phalanx of the thumb, flexes the hand;
- flexes the proximal phalanx of the thumb, flexes the hand;
- flexes the distal phalanx of the thumb, extends the hand;
- flexes the proximal and distal phalanges of 2nd – 5th fingers?

***What is the action of the pronator quadratus muscle:***

- + pronates the forearm and the hand;
- supinates the forearm and the hand;
- flexes and pronates the hand;
- flexes and supinates the hand?

***How many layers have muscles of the posterior group of muscles of the forearm:***

- + 2 layers;
- 4 layers;
- 1 layer;
- 3 layers?

***Where do all muscles of the posterior group of muscles of the forearm arise:***

- + from the lateral epicondyle of the humerus;
- from the medial epicondyle of the humerus;
- from the capsule of the elbow joint;
- from the posterior surfaces of the radius and ulna and the capsule of the wrist joint?

***What is the action of the extensor carpi radialis longus muscle:***

- + flexes the forearm at the elbow joint, extends and abducts the hand at the wrist joint;
- flexes the forearm and the hand, abducts the hand at the wrist joint;
- extends the forearm and the hand, adducts the hand at the wrist joint;
- extends the hand at the wrist joint, pronates the forearm and the hand?

***What is the action of the extensor carpi radialis brevis muscle:***

- + extends and abducts the hand at the wrist joint;
- extends and adducts the hand at the wrist joint;
- extends the hand, tenses the palmar aponeurosis;
- extends the hand, pronates the forearm together with the hand?

***What is the action of the extensor carpi ulnaris muscle:***

- + extends and adducts the hand at the wrist joint;
- extends and abducts the hand at the wrist joint;
- extends the hand, pronates the forearm together with hand;
- extends the hand, supinates the forearm together with the hand?

***Muscles of the hand are divided into groups:***

- + the thenar, hypothenar and middle groups;
- the medial, lateral and dorsal groups;
- the superficial and deep groups;
- the thenar, hypothenar, dorsal groups and muscles of fingers.

***Muscles of the hollow of the hand (middle group) are:***

- + the lumbrical, palmar and dorsal interosseal muscles;
- the short and long palmar, lumbrical muscles;
- the superficial and deep flexor digitorum, palmar interosseal muscles;
- the extensor digitorum, dorsal interosseal, lumbrical muscles.

**How many lumbrical muscles are in one hand:**

- + 4 muscles;
- 5 muscles;
- 2 muscles;
- 3 muscles?

**What is the action of the palmar interossei muscles:**

- + adduct the 2nd, 4th and 5th fingers to the 3rd finger, flex the proximal phalanges and extend the middle and distal phalanges;
- flex the proximal phalanges at metacarpophalangeal joints and extend middle and distal phalanges at interphalangeal joints;
- abduct the 2nd, 4th and 5th fingers from the 3rd finger, flex the fingers at metacarpophalangeal joints;
- flex the 2nd – 5th fingers at metacarpophalangeal and interphalangeal joints?

**Theme 17. Fasciae and topography of the upper limb**

**Muscles of the region of the shoulder joint are:**

- + the deltoid, supraspinatus, infraspinatus, teres minor and major, subscapularis muscles;
- the deltoid, rhomboid major and minor, teres minor and major muscles;
- the deltoid, supraspinatus and infraspinatus, subscapularis and suprascapularis muscles;
- the deltoid, subscapularis, subclavius, teres minor and major muscles?

**Where does the deltoid muscle attach:**

- + to the deltoid tuberosity of the humerus;
- to the greater tubercle of the humerus;
- to the clavicle;
- to the acromion of the scapula?

**What is the action of the whole deltoid muscle:**

- + abducts the arm from the trunk to 70 degrees, forms protective and reinforced vault of the shoulder joint;
- adducts the arm and forms the vault of the shoulder joint;

- flexes the arm and rotates it medially;
- extends the arm and rotates it laterally?

**What muscle located superficially covers the shoulder joint with lateral, anterior, superior and posterior sides:**

- + the deltoid muscle;
- the supraspinatus muscle;
- the teres major muscle;
- the infraspinatus muscle?

**What is the origin of the supraspinatus muscle:**

- + the supraspinous fossa of the scapula;
- the spine of the scapula;
- the anterior (costal) surface of the scapula;
- the medial border of the scapula?

**What is the action of the supraspinatus muscle:**

- + abducts the arm at the shoulder joint;
- adducts the arm at the shoulder joint;
- rotates the arm (pronation) medially;
- rotates the arm (supination) laterally?

**What is the origin of the infraspinatus muscle:**

- + the infraspinous fossa and infraspinous fascia;
- the spine of the scapula and infraspinous fascia;
- the lateral border of scapula;
- the acromion of scapula?

**What is the action of the infraspinatus muscle:**

- + laterally rotates the arm (supination);
- medially rotates the arm (pronation);
- flexes the arm and medially rotates it;
- extends the arm and laterally rotates it?

**What is the action of the teres minor muscle:**

- + laterally rotates the arm (supination);
- medially rotates the arm (pronation);
- flexes and medially rotates the arm;
- extends and laterally rotates the arm?

**What is the action of the teres major muscle:**

- + extends, adducts and medially rotates the arm at the shoulder joint;
- flexes and laterally rotates the arm the shoulder joint;
- laterally rotates the arm at the shoulder joint;
- abducts the arm above the horizontal level?

**What is the origin of the subscapularis muscle:**

- + the subscapular fossa of scapula;
- the dorsal surface of scapula;
- the inferior angle and spine of scapula;
- the medial border of scapula?

**What is the action of the subscapularis muscle:**

- + adducts and medially rotates the arm (pronation);
- laterally rotates the arm (supination);
- abducts the arm from the trunk to 70 degrees;
- flexes the arm?

**Muscles of the upper arm are divided into the following groups:**

- + anterior muscles (flexors) and posterior muscles (extensors) of the upper arm;
- anterior muscles (extensors) and posterior muscles (flexors) of the upper arm;
- medial muscles (pronators) and lateral muscles (supinators) of the upper arm;
- superficial muscles (flexors) and deep muscles (extensors) of the upper arm?

**Anterior muscles of the upper arm are:**

- + the biceps brachii, coracobrachialis and brachialis muscles;
- the biceps brachii and triceps brachii muscles;
- the biceps brachii, brachialis and brachioradialis muscles;
- the biceps brachii, deltoid and brachialis muscles.

**Posterior muscles of the upper arm are:**

- + the triceps brachii and anconeus muscles;
- the triceps brachii and biceps brachii muscles;
- the triceps brachii, brachialis and brachioradialis muscles;
- the biceps brachii, brachialis and coracobrachialis muscles.

**The biceps brachii muscle consists of two heads:**

- + the long and short heads;
- the lateral and medial heads;
- the superficial and deep heads;
- the superior and inferior heads.

**Where does the long head of the biceps brachii muscle arise from:**

- + the supraglenoid tubercle of scapula;

- the infraglenoid tubercle of scapula;
- the coracoid process of scapula;
- the acromion of scapula?

**What is the action of the biceps brachii muscle:**

- + flexes the arm and forearm, supinates the forearm;
- extends the arm and forearm, supinates the forearm;
- flexes the arm and extends the forearm, pronates the forearm;
- extends the arm and flexes the forearm, supinates the forearm?

**What is the action of the coracobrachialis muscle:**

- + flexes and adducts the arm, supinates the arm, if it was pronated;
- extends the arm, supinates the arm if it was pronated;
- abducts the arm from the trunk to the horizontal level;
- adducts the arm to the trunk, pronates the arm?

**The triceps brachii muscle consists of three heads:**

- + the long, lateral and medial heads;
- the long, short and medial heads;
- the superficial, deep and lateral heads;
- the long, superior and inferior heads.

**What is the action of the triceps brachii muscle:**

- + extends and adducts the arm at the shoulder joint and extends the forearm at the elbow joint;
- flexes the arm and forearm;
- extends the arm at the shoulder joint and flexes the forearm at the elbow joint;
- flexes and adducts the arm at the shoulder joint and extends the forearm at the elbow joint?

**What is the action of the anconeus muscle:**

- + extends the forearm at the elbow joint;
- flexes the forearm at the elbow joint;
- pronates the forearm;
- supinates the forearm?



***Muscles of the forearm are separated into two groups according to their position:***

- + the anterior group or flexors and pronators, the posterior group or extensors and supinators;
- the anterior group or extensors, the posterior group or flexors;
- the superficial group or flexors, the deep group or extensors;
- the medial group or flexors and supinators, the lateral group or extensors and pronators.

***How many layers have muscles of the anterior group of muscles of the forearm:***

- + 4 layers;
- 2 layers;
- 5 layers;
- 1 layer?

***What muscles form the 1st layer of the anterior group of muscles of the forearm:***

- + the pronator teres, flexor carpi radialis, palmaris longus, flexor carpi ulnaris muscles;
- the pronator teres, flexor carpi radialis, brachioradialis, flexor digitorum superficialis muscles;
- the pronator teres, flexor carpi radialis, flexor carpi ulnaris, flexor pollicis longus muscles;
- the pronator teres, brachioradialis, flexor carpi ulnaris, pronator quadratus muscles?

***What muscles form the 2nd layer of the anterior group of muscles of the forearm:***

- + the flexor digitorum superficialis muscle;
- the flexor carpi radialis and flexor carpi ulnaris muscles;
- the brachioradialis muscle;
- the flexor pollicis longus muscle?

***What muscles form the 3rd layer of the anterior group of muscles of the forearm:***

- + the flexor pollicis longus and flexor digitorum profundus muscles;
- the flexor digitorum superficialis and flexor digitorum profundus muscles;
- the pronator quadratus muscle;
- the pronator teres and pronator quadratus muscles?

***What muscles form the 4th layer of the anterior group of muscles of the forearm:***

- + the pronator quadratus muscle;
- the pronator teres muscle;
- the flexor pollicis longus and flexor digitorum profundus muscles;
- the flexor digitorum superficialis and flexor digitorum profundus muscles?

***Where do all muscles of the anterior group of muscles of the forearm arise, except the pronator quadratus muscle:***

- + from the medial epicondyle of the humerus;
- from the lateral epicondyle of the humerus;
- from the capsule of the shoulder joint;
- from the anterior surfaces of the ulna and radius and the capsule of the radiocarpal joint?

***What is the action of the pronator teres muscle:***

- + pronates the forearm at the radioulnar joints, flexes forearm at elbow joint;
- supinates the forearm at the radioulnar joint;
- extends and abducts the hand at the wrist joint;
- pronates and flexes the arm at the shoulder joint?

***What is the action of the flexor carpi radialis muscle:***

- + flexes and abducts the hand (radial deviation) at the wrist joint;
- flexes and adducts the hand, supinates the forearm;
- extends and abducts the hand at the wrist joint;
- tenses the palmar aponeurosis and weakly flexes the hand at the wrist joint?

***What is the action of the palmaris longus muscle:***

- + tenses the palmar aponeurosis and weakly flexes the hand at the wrist joint;
- relaxes the palmar aponeurosis;
- extends the hand at the wrist joint and pronates the forearm;
- supinates the forearm together with the hand?

***What is the action of the flexor carpi ulnaris muscle:***

- + flexes and adducts the hand (ulnar deviation) at the wrist joint;

- extends and abducts the hand at the wrist joint;
- tenses the palmar aponeurosis and weakly flexes the hand at the wrist joint;
- flexes the hand at the wrist joint and flexes the distal phalanx of the little finger?

***What is the action of the flexor digitorum superficialis muscle:***

- + flexes middle phalanges of the 2nd – 5th fingers, flexes the hand at the wrist joint;
- flexes distal phalanges of the 2nd – 5th fingers, flexes the hand at the wrist joint;
- flexes middle phalanges of the 1st – 5th fingers, extends the hand at the wrist joint;
- flexes all phalanges of the 1st – 5th fingers, flexes the hand at the wrist joint?

***What is the action of the flexor digitorum profundus muscle:***

- + flexes distal phalanges of the 2nd – 5th fingers, flexes the hand at the wrist joint;
- flexes middle phalanges of the 2nd – 5th fingers;
- flexes proximal phalanges of the 1st – 5th fingers, flexes the hand at the wrist joint;
- flexes proximal and middle phalanges of the 1st – 5th fingers, flexes the hand at the wrist joint?

***What is the action of the flexor pollicis longus muscle:***

- + flexes the distal phalanx of the thumb, flexes the hand;
- flexes the proximal phalanx of the thumb, flexes the hand;
- flexes the distal phalanx of the thumb, extends the hand;
- flexes the proximal and distal phalanges of the 2nd – 5th fingers?

***What is the action of the pronator quadratus muscle:***

- + pronates the forearm and the hand;
- supinates the forearm and the hand;
- flexes and pronates the hand;
- flexes and supinates the hand?

***How many layers have muscles of the posterior group of muscles of the forearm:***

- + 2 layers;
- 4 layers;
- 1 layer;
- 3 layers?

***Where do all muscles of the posterior group of muscles of the forearm arise from:***

- + the lateral epicondyle of the humerus;
- the medial epicondyle of the humerus;
- the capsule of the elbow joint;
- the posterior surfaces of the radius and ulna and the capsule of the wrist joint?

***What is the action of the extensor carpi radialis longus muscle:***

- + flexes the forearm at elbow joint; extends and abducts the hand at wrist joint;
- flexes the forearm and hand; abducts the hand at the wrist joint;
- extends the forearm and the hand, adducts the hand at the wrist joint;
- extends the hand at wrist joint; pronates the forearm and the hand?

***What is the action of the extensor carpi radialis brevis muscle:***

- + extends and abducts the hand at the wrist joint;
- extends and adducts the hand at the wrist joint;
- extends the hand, tenses the palmar aponeurosis;
- extends the hand, pronates the forearm together with the hand?

***What is the action of the extensor carpi ulnaris muscle:***

- + extends and adducts the hand at the wrist joint;
- extends and abducts the hand at the wrist joint;
- extends the hand, pronates the forearm together with the hand;
- extends the hand, supinates the forearm together with the hand?

***Muscles of the hand are divided into the following groups:***

- + the thenar, hypothenar and middle groups;
- the medial, lateral and dorsal groups;

- the superficial and deep groups;
- the thenar, hypothenar, dorsal groups and muscles of fingers.

***Muscles of the hollow of the hand (middle group) are:***

- + the lumbrical, palmar and dorsal interossei muscles;
- the short and long palmar, lumbrical muscles;
- the superficial and deep flexor digitorum, palmar interossei muscles;
- the extensor digitorum, dorsal interossei, lumbrical muscles.

***How many lumbrical muscles are in one hand:***

- + 4 muscles;
- 5 muscles;
- 2 muscles;
- 3 muscles?

***What is the action of the palmar interossei muscles:***

- + adduct the 2nd, 4th and 5th fingers to the 3rd finger, flex the proximal phalanges and extend the middle and distal phalanges;
- flex the proximal phalanges at the metacarpophalangeal joints and extend the middle and distal phalanges at the interphalangeal joints;
- abduct the 2nd, 4th and 5th fingers from the 3rd finger, flex the fingers at the metacarpophalangeal joints;
- flex the 2nd – 5th fingers at the metacarpophalangeal and the interphalangeal joints?

**Theme 18. Muscles of the pelvic girdle and the lower limb**

***The muscles of the hip region are classified into:***

- + the internal and external groups;
- the medial and lateral groups;
- the superior and inferior groups;
- the anterior, posterior and medial groups.

***The internal group of the muscles of the hip region consists of the following muscles:***

- + the iliopsoas, psoas minor, obturator internus and piriformis muscles;

- the iliacus, psoas minor and major, obturator internus and externus muscles;
- the piriformis, superior and inferior gemellus, obturator internus muscles;
- the iliopsoas, piriformis, obturator internus and externus muscles.

***Name the muscle which consists of the iliacus and psoas major muscles:***

- + the iliopsoas muscle;
- the piriformis muscle;
- the gluteus maximus muscle;
- the quadratus femoris muscle.

***Where does the iliacus muscle of the iliopsoas muscle arise from:***

- + the iliac fossa and internal lip of the iliac crest;
- from the iliac fossa and external lip of the iliac crest;
- the anterior superior iliac spine;
- the external surface of the iliac wing?

***Where does the psoas major muscle of the iliopsoas muscle arise from:***

- + from the lateral surfaces of bodies and transverse processes of the T12 – L5;
- from the spinous processes of T12 – L5;
- from the pelvic surface of the sacrum lateral to the anterior sacral foramina;
- from the internal surface of the iliac wing?

***Where does the iliopsoas muscle attach:***

- + to the lesser trochanter of the femur;
- to the greater trochanter of the femur;
- to the gluteal tuberosity of the femur;
- to the inguinal ligament and iliopubic eminence?

***The iliopsoas muscle lies on the anterior surface of the hip joint and passes to the thigh through:***

- + the lacuna musculorum from under the inguinal ligament;
- the lacuna vasorum from under the inguinal ligament;
- the greater sciatic foramen;
- the obturator canal.

***What is the action of the iliopsoas muscle:***

- + flexes the thigh at the hip joint; when the lower limb is steadied, the muscle flexes the pelvis and the trunk forward;
- extends the thigh at the hip joint; when the lower limb is steadied, the muscle extends the trunk;
- abducts and medially rotates the thigh;
- abducts and laterally rotates the thigh?

***Where is the psoas minor muscle inserted:***

- + into the inguinal ligament and iliopubic eminence;
- into the lesser trochanter of the femur;
- into the greater trochanter of the femur;
- into the pubic symphysis?

***What is the action of the psoas minor muscle:***

- + tenses the iliac fascia and iliopectineal arch;
- flexes the thigh at the hip joint;
- abducts the thigh and flexes the trunk forward;
- adducts the thigh?

***Where does the obturator internus muscle originate:***

- + on the inner surface of the hip bone from the margin of the obturator foramen and the obturator membrane;
- from the margin of the obturator foramen and the external surface of the obturator membrane;
- from the inner surface of the iliac wing;
- from the pubic symphysis?

***What is the insertion of the obturator internus muscle:***

- + the trochanteric fossa on the femur;
- the lesser trochanter of the femur;
- the gluteal tuberosity of the femur;
- the pubic symphysis?

***What is the action of the obturator internus muscle:***

- + laterally rotates and abducts the thigh;
- adducts the thigh;
- extends the thigh;
- flexes the thigh?

***The obturator internus muscle passes from the pelvic cavity onto the gluteal region through:***

- + the lesser sciatic foramen;
- the greater sciatic foramen;
- the lacuna musculorum;
- the lacuna vasorum.

***The external group of the muscles of the hip region consists of the following muscles:***

- + the gluteus maximus, medius, minimus; the tensor fasciae latae; the quadratus femoris; the obturator externus; the superior and inferior gemellus;
- the gluteus maximus, medius, minimus; the obturator externus and internus; the superior and inferior gemellus; the psoas minor;
- the gluteus maximus, medius, minimus; the psoas minor and major; the quadratus femoris; the obturator externus and internus;
- the gluteus maximus, medius, minimus; the tensor fasciae latae; the piriformis; the obturator externus and internus.

***Where does the piriformis muscle arise:***

- + on the pelvic surface of the sacrum lateral to the sacral foramina;
- on the dorsal surface of the sacrum lateral to the sacral foramina;
- on the internal surface of the iliac wing;
- on the external surface of the iliac wing?

***Where does the piriformis muscle attach:***

- + to the apex of the greater trochanter of the femur;
- to the apex of the lesser trochanter of the femur;
- to the gluteal tuberosity of the femur;
- to the neck of the femur?

***What is the action of the piriformis muscle:***

- + laterally rotates and abducts the thigh;
- medially rotates and abducts the thigh;
- extends the thigh;
- flexes the thigh?

***The piriformis muscle passes from the pelvic cavity onto the gluteal region through:***

- + the greater sciatic foramen;

- the lesser sciatic foramen;
- the lacuna vasorum;
- the lacuna musculorum.

***The external group of the muscles of the hip region consists of the layers:***

- + the external, middle and internal layers;
- the medial and lateral layers;
- the external and internal layers;
- the superior, middle and inferior layers.

***Which muscles form the superficial layer of the external group of muscles of the hip region:***

- + the gluteus maximus and tensor fasciae latae muscles;
- the gluteus maximus, medius and minimus muscles;
- the gluteus maximus and quadratus femoris muscles;
- the gluteus maximus and obturator externus muscles?

***What muscles form the middle layer of the external group of muscles of the hip region:***

- + the gluteus medius, quadratus femoris, superior and inferior gemellus muscles;
- the gluteus medius and tensor fasciae latae muscles;
- the quadratus femoris, gluteus medius and minimus muscles;
- the gluteus medius, obturator externus and internus muscles?

***What muscles form the deep layer of the external group of muscles of the hip region:***

- + the gluteus minimus and obturator externus muscles;
- the gluteus minimus, obturator externus and internus muscles;
- the gluteus minimus, quadratus femoris, superior and inferior gemellus muscles;
- the gluteus medius and minimus, superior and inferior gemellus muscles?

***What is the origin of the gluteus maximus muscle:***

- + the external surface of the iliac wing, posterior surface of the sacrum and coccyx, sacrotuberal ligament;
- the external lip of the iliac crest, pelvic

- surface of the sacrum;
- the internal surface of the iliac wing, pelvic surface of the sacrum;
- the external lip of the iliac crest, anterior superior iliac spine?

***Where is the gluteus maximus muscle attached:***

- + to the gluteal tuberosity of the femur; the anterior part of its tendon is continuous with the iliotibial tract;
- to the greater trochanter; the anterior part of its tendon is continuous with the iliotibial tract;
- to the lesser trochanter; the posterior part of its tendon is continuous with the iliotibial tract;
- to the neck of the femur?

***What is the action of the gluteus maximus muscle:***

- + extends, abducts and supinates the thigh, when the lower limb is held fast, it extends the pelvis and trunk, maintains the upright posture;
- flexes and adducts the thigh, maintains the upright posture;
- adducts the thigh and flexes the trunk;
- flexes the thigh and the trunk?

***What is the origin of the gluteus medius muscle:***

- + the external surface of iliac wing between the anterior and posterior gluteal lines, the fascia lata;
- the external lip of the iliac crest;
- the anterior superior iliac spine and fascia lata;
- the internal surface of the iliac wing?

***Where is the gluteus medius muscle attached:***

- + to the greater trochanter of the femur;
- to the lesser trochanter of the femur;
- to the gluteal tuberosity of the femur;
- to the neck of the femur?

***What is the action of the gluteus medius muscle:***

- + abducts the thigh; the anterior fibers medially rotate the thigh, the posterior fibers rotate it laterally;
- adducts the thigh; the anterior fibers laterally

rotate the thigh, the posterior fibers rotate it medially;

- abducts and medially rotates the thigh;
- extends the thigh?

***Where does the gluteus minimus muscle originate:***

- + from the external surface of the iliac wing between the anterior and inferior gluteal lines, from the margin of the greater sciatic notch;
- from the internal surface of the iliac wing and the margin of the lesser sciatic notch;
- from the anterior superior iliac spine and the fascia lata;
- from the external lip of the iliac crest and the sacrotuberous ligament?

***Where is the gluteus minimus muscle attached:***

- + to the greater trochanter of the femur and the capsule of the hip joint;
- to the lesser trochanter and the capsule of the hip joint;
- to the gluteal tuberosity of the femur;
- to the neck of the femur?

***What is the action of the gluteus minimus muscle:***

- + abducts the thigh; the anterior fibers medially rotate the thigh, the posterior fibers rotate it laterally;
- adducts the thigh; the anterior fibers laterally rotate the thigh, the posterior fibers rotate it medially;
- adducts and medially rotates the thigh;
- extends the thigh?

***Where does the tensor fasciae latae muscle originate:***

- + from the anterior superior iliac spine;
- from the anterior inferior iliac spine;
- from the external lip of the iliac crest;
- from the external surface of the iliac wing?

***Where is the tensor fasciae latae muscle attached:***

- + it is continuous with the iliotibial tract, which attaches to the lateral tibial condyle;
- it is continuous with the iliotibial tract, which attaches to the medial tibial condyle;

- to the head of the fibula;
- to the body of the tibia?

***Where does the quadratus femoris muscle originate:***

- + from the ischial tuberosity;
- from the posterior superior iliac spine;
- from the posterior inferior iliac spine;
- from the ischial spine?

***Where is the quadratus femoris muscle attached:***

- + to the intertrochanteric crest of the femur;
- to the lesser trochanter of the femur;
- to the greater trochanter of the femur;
- to the intertrochanteric line of the femur?

***What is the action of the quadratus femoris muscle:***

- + laterally rotates the thigh;
- medially rotates the thigh;
- flexes the thigh;
- extends the thigh?

***What is the origin of the obturator externus muscle:***

- + the outer surface of the obturator membrane and the outer margin of the obturator foramen;
- the ischial tuberosity;
- the inner surface of the obturator membrane and the inner margin of the obturator foramen;
- the posterior superior and inferior iliac spines?

***Where is the obturator externus muscle attached:***

- + to the trochanteric fossa of the greater trochanter of the femur;
- to the lesser trochanter of the femur;
- to the intertrochanteric crest of the femur;
- to the linea aspera of the femur?

***What is the action of the obturator externus muscle:***

- + laterally rotates the thigh;
- medially rotates the thigh;

- adducts the thigh;
- flexes the thigh?

**Where do the superior and inferior gemellus muscles arise:**

- + from the ischial spine and ischial tuberosity;
- from the outer surface of the obturator membrane;
- from the ramus of the ischium and inferior ramus of the pubis;
- from the posterior superior and inferior iliac spine?

**Where are the superior and inferior gemellus muscles attached:**

- + to the trochanteric fossa of the greater trochanter of the femur;
- to the lesser trochanter of the femur;
- to the intertrochanteric crest of the femur;
- to the linea aspera of the femur?

**What is the action of the superior and inferior gemellus muscles:**

- + laterally rotate and abduct the thigh at the hip joint;
- medially rotate the thigh at the hip joint;
- adduct and medially rotate the thigh at the hip joint;
- flex and abduct the thigh at the hip joint?

**The muscles of the thigh are divided into the groups:**

- + anterior, posterior and medial;
- anterior, posterior and lateral;
- lateral and medial.
- superficial and deep.

**Where does the sartorius (tailor's) muscle originate:**

- + from the anterior superior iliac spine;
- from the anterior inferior iliac spine;
- from the external lip of the iliac crest;
- from the posterior surface of the iliac wing?

**Where is the sartorius (tailor's) muscle attached:**

- + to the tibial tuberosity;
- to the head of the fibula;
- to the medial condyle of the tibia;

- to the lateral condyle of the tibia?

**What is the action of the sartorius (tailor's) muscle:**

- + flexes, abducts and laterally rotates the thigh at the hip joint; flexes and medially rotates the leg at the knee joint;
- extends the thigh and the leg, medially rotates the leg at the knee joint;
- adducts the thigh at the hip joint and flexes the leg at the knee joint;
- flexes the thigh at the hip joint and extends the leg at the knee joint?

**The quadriceps femoris muscle is formed of heads fused to each other. These heads are as follows:**

- + the rectus femoris, vastus lateralis, medialis and intermedius muscles;
- the long, short, vastus lateralis and vastus medialis muscles;
- the rectus, oblique medialis, oblique lateralis and vastus intermedius muscles;
- the superficial, deep, lateral and medial muscles.

**What is the origin of the rectus femoris muscle:**

- + the anterior inferior iliac spine;
- the anterior superior iliac spine;
- the intertrochanteric line of the femur;
- the greater trochanter of the femur?

**What is the origin of the vastus lateralis muscle:**

- + the intertrochanteric line, greater trochanter, lateral lip of the linea aspera of the femur;
- the lesser trochanter and intertrochanteric crest of the femur;
- the greater and lesser trochanters of the femur;
- the anterior superior iliac spine?

**What is the origin of the vastus medialis muscle:**

- + the medial lip of the linea aspera and intertrochanteric line of the femur;
- the greater and lesser trochanters of the femur;
- the lesser trochanter and intertrochanteric

- crest of the femur;
- the inferior ramus of the pubis?

***Where is the quadriceps femoris muscle inserted:***

- + to tibial tuberosity; to apex and sides of the patella forming the patellar ligament and retinaculum of the patella;
- to the lateral and medial condyles of the tibia forming the patellar ligament;
- to the head of the fibula; to the lateral sides of the patella forming the retinaculum of the patella;
- to the anterior surfaces of the tibial and fibular bodies?

***What is the action of the quadriceps femoris muscle:***

- + extends the leg at the knee joint; the rectus femoris flexes the thigh at the hip joint;
- flexes the leg at the knee joint; the rectus femoris extends the thigh at the hip joint;
- extends the thigh at the hip joint and extends the leg at the knee joint;
- flexes the thigh at the hip joint and flexes the leg at the knee joint?

***The quadriceps femoris and sartorius muscles are classified as:***

- + the anterior group of thigh muscles;
- the medial group of thigh muscles;
- the posterior group of thigh muscles;
- the lateral group of thigh muscles.

***What muscles of the thigh are classified as the posterior group:***

- + the semitendinosus, semimembranosus and biceps femoris muscles;
- the biceps femoris and quadriceps femoris muscles;
- the biceps femoris, gracilis, pectineus and sartorius muscles;
- the adductor longus, brevis and magnus muscles, biceps femoris and sartorius muscles?

***What is the origin of the long head of the biceps femoris muscle:***

- + the ischial tuberosity;
- the posterior surface of the body of the

- femur;
- the inferior ramus of the pubis;
- the pubic symphysis?

***What is the origin of the short head of the biceps femoris muscle:***

- + the lateral lip of the linea aspera of the femur;
- the ischial tuberosity;
- the inferior ramus of the pubis;
- the medial lip of the linea aspera of the femur?

***Where is the biceps femoris muscle inserted:***

- + to the head of the fibula and lateral condyle of the tibia;
- to the tibial tuberosity;
- to the medial condyle of the tibia;
- to the posterior surface of the body of the tibia?

***What is the action of the biceps femoris muscle:***

- + flexes the leg and extends the thigh;
- flexes the thigh and extends the leg;
- extends the thigh and the leg;
- flexes the thigh and the leg?

***What heads has the biceps femoris muscle:***

- + long and short;
- medial and lateral;
- superficial and deep;
- long and intermediate?

***What is the origin of the semitendinosus muscle:***

- + the ischial tuberosity;
- the inferior ramus of the pubis;
- the lateral lip of the linea aspera of the femur;
- the anterior inferior iliac spine?

***What is the insertion of the semitendinosus muscle:***

- + the tibial tuberosity;
- the head of the fibula;
- the posterior surface of the tibial shaft;
- the posterior surface of the shaft of the fibula?



**What is the action of the semitendinosus muscle:**

- + extends the thigh and flexes the leg;
- flexes the thigh and extends the leg;
- extends the thigh and the leg;
- flexes the thigh and the leg?

**What is the origin of the semimembranosus muscle:**

- + the ischial tuberosity;
- the inferior ramus of the pubis;
- the posterior inferior iliac spine;
- the linea aspera of the femur?

**Where is the semimembranosus muscle attached:**

- + to the ligamentum collaterale tibiale, to the popliteal fascia and soleus line of the tibia, to the posterior surface of the lateral condyle of the femur by 3 bands forming the "deep goose's foot"
- to the posterior surface of the proximal epiphysis of the tibia by 3 bands forming the "deep goose's foot";
- to the tibial tuberosity by 3 bands forming the "superficial goose's foot";
- to the medial and lateral condyles of the tibia and to the head of the fibula by 3 bands?

**What is the action of the semimembranosus muscle:**

- + extends the thigh and flexes the leg;
- flexes the thigh and extends the leg;
- extends the thigh and the leg;
- flexes the thigh and the leg?

**Where does the medial group of muscles of the thigh originate:**

- + from the rami of the pubis and ischium;
- from the linea aspera of the femur;
- from the greater and lesser trochanters of the femur;
- from the posterior surface of the sacrum?

**What muscles of the thigh are classified as the medial group:**

- + the pectineus, gracilis, adductor longus, brevis and magnus muscles;

- the biceps femoris, gracilis and pectineus muscles;
- the adductor longus, brevis and magnus muscles, gracilis and sartorius muscles;
- the gracilis, sartorius and semitendinosus muscles?

**Where is the gracilis muscle attached:**

- + to the tibial tuberosity;
- to the medial and lateral condyles of the tibia;
- to the head of the fibula;
- to the medial lip of the linea aspera of the femur?

**Where is the adductor magnus muscle attached:**

- + to the medial lip of the linea aspera and to the medial condyle of the femur;
- to the medial lip of the linea aspera of the femur and to the medial condyle of the tibia;
- to the tibial tuberosity;
- to the lateral lip of the linea aspera of the femur and to the head of the fibula?

**What is the principal action of the medial group of muscles of the thigh:**

- + adducts the thigh;
- abducts the thigh;
- flexes the thigh;
- extends the thigh?

**What muscles form the "superficial goose's foot":**

- + the gracilis, sartorius and semitendinosus muscles;
- 3 bands of the semimembranosus muscle;
- the biceps and quadriceps muscles;
- the biceps, semitendinosus and semimembranosus muscles?

**Muscles of the leg and foot. Topography of the lower limb. The muscles of the leg are separated into groups according to position:**

- the anterior group (extensors), posterior group (flexors) and lateral group;
- the anterior group (flexors), posterior group (extensors) and lateral group;

- the lateral group (extensors) and medial group (flexors).

***The muscles of the anterior group of muscles of the leg are:***

- + the tibialis anterior, extensor digitorum longus and extensor hallucis longus muscles;
- the tibialis anterior, flexor digitorum longus and flexor hallucis longus muscles;
- the tibialis anterior, peroneus longus and brevis muscles;
- the tibialis anterior, gastrocnemius and soleus muscles.

***Where does the tibialis anterior muscle arise:***

- + from the lateral condyle, lateral surface of the tibial body, the interosseous membrane and crural fascia;
- from the medial condyle, medial surface of the tibial body, interosseous membrane and crural fascia;
- from the bodies of tibia and fibula, from the crural fascia;
- from the lateral condyle of the femur?

***Where is the tibialis anterior muscle attached:***

- + to the plantar surface of the medial cuneiform bone and the base of the 1st metatarsal bone;
- to the dorsal surface of the cuneiform bones;
- to the plantar surface of the bases of the 1st – 2nd metatarsal bones;
- to the dorsal surface of the navicular bone?

***What is the action of the tibialis anterior muscle:***

- + extends and supinates the foot, strengthens the longitudinal arches of the foot, holds the leg vertically;
- flexes and supinates the foot, holds the leg vertically;
- extends the leg and the foot, pronates the foot;
- flexes the leg and the foot, strengthens the longitudinal arches of the foot?

***Where does the extensor digitorum longus muscle arise:***

- + from the lateral tibial condyle, the head and anterior surface of the fibula;
- from the lateral and medial tibial condyles

- and interosseous membrane;
- from the lateral and medial femoral condyles and crural fascia;
- from the interosseous membrane and crural fascia, from lateral surface of the body of the femur?

***Where is the extensor digitorum longus muscle attached:***

- + to the dorsal surfaces of the bases of the middle and distal phalanges of the 2nd – 5th toes;
- to the plantar surfaces of the bases of the middle and distal phalanges of the 1st – 5th toes;
- to the dorsal surfaces of the bases of the proximal phalanges of the 2nd – 5th toes;
- to the plantar surfaces of the bases of the proximal phalanges of the 1st – 5th toes?

***What is the action of the extensor digitorum longus muscle:***

- + extends the 2nd – 5th toes and the foot, pronates and everts the foot, holds the leg vertically;
- extends the 1st – 5th toes and the foot, strengthens the longitudinal arches of the foot;
- extends the 2nd – 5th toes and the foot, supinates and inverts the foot;
- extends the 1st – 5th toes and the foot, holds the leg vertically?

***Where is the extensor hallucis longus muscle attached:***

- + to the distal phalanx of the 1st toe;
- to the proximal phalanx of the 1st toe;
- to the distal phalanges of the 1st – 2nd toes;
- to the proximal phalanges of the 1st – 2nd toes?

***The posterior group of muscles of the leg is divided into:***

- + the superficial and deep layers;
- the medial and lateral layers;
- flexors and extensors;
- the superior and inferior layers.

***The superficial layer of the posterior group of muscles of the leg (muscles of the calf) are:***

- + the triceps surae and plantaris muscles;
- the gastrocnemius and plantaris muscles;
- the soleus, tibialis posterior and plantaris muscles;
- the triceps surae, peroneus longus and brevis muscles.

***The triceps surae muscle is made up of:***

- + the gastrocnemius and soleus muscles;
- the gastrocnemius and popliteus muscles;
- the gastrocnemius, soleus and tibialis posterior muscles;
- the soleus and popliteus muscles.

***Where does the gastrocnemius muscle originate:***

- + by two heads from the lateral and medial condyles of the femur;
- by two heads from the lateral and medial condyles of the tibia;
- by two heads from the posterior surface of the tibia and fibula;
- from the fibula by the lateral and medial heads?

***Where does the soleus muscle originate:***

- + from the soleus line of the tibia and proximal end of the fibula;
- from the lateral and medial condyles of the femur;
- from the lateral and medial condyles of the tibia;
- from the posterior surface of the bodies of the tibia and femur?

***What anatomical structure is formed by fusing the tendon of the gastrocnemius muscle with the tendon of the soleus muscle:***

- + the calcaneal (Achilles) tendon;
- the common tendon of the posterior group of muscles of the leg;
- the common tendon of the deep layer of the posterior group of muscles of the leg;
- the lateral and medial synovial bursae of the gastrocnemius muscle?

***Where is the triceps surae muscle attached:***

- + by the calcaneal (Achilles) tendon to the calcaneal tuber;
- by the calcaneal (Achilles) tendon to the

- cuboid bone;
- to the bases of the 1st – 5th metatarsal bones;
- to the navicular and cuneiform bones?

***What is the action of the triceps surae muscle:***

- + flexes the leg at the knee joint and plantar flexes the foot at the ankle joint;
- extends the leg at the knee joint and extends the foot (dorsiflexes) at the ankle joint;
- flexes the leg at the knee joint and extends the foot (dorsiflexes) at the ankle joint;
- extends the leg at the knee joint and plantar flexes the foot at the ankle joint?

***Where is the plantaris muscle attached:***

- + to the calcaneal tuber;
- to the cuboid bone;
- to the navicular bone;
- to the base of the 1st metatarsal bone?

***The popliteus muscle is classified as:***

- + the deep layer of the posterior group of muscles of the leg;
- the superficial layer of the posterior group of muscles of the leg;
- the lateral group of muscles of the leg;
- the posterior group of muscles of the thigh?

***Where is the popliteus muscle inserted:***

- + into the proximal part of the posterior surface of the tibia above the soleus line;
- into the proximal part of the posterior surface of the fibula;
- into the calcaneal (Achilles) tendon;
- into the calcaneal tuber?

***What is the action of the popliteus muscle:***

- + flexes the leg at the knee joint and rotates it medially;
- extends the leg at the knee joint;
- flexes the leg at the knee joint and the foot at the ankle joint;
- extends the leg at the knee joint and the foot at the ankle joint?

***The flexor digitorum longus muscle of the foot is classified as:***

- + the deep layer of the posterior group of the leg muscles;
- the superficial layer of the posterior group of

- the muscles of the leg;
- the anterior group of muscles of the leg;
- the lateral layer of muscles of the leg.

**Where is the flexor digitorum longus muscle of the foot inserted:**

- + to the bases of the distal phalanges of the 2nd – 5th toes;
- to the bases of the distal phalanges of the 1st – 5th toes;
- to the bases of the proximal phalanges of the 2nd – 5th – toes;
- to the bases of the proximal phalanges of the 1st – 5th toes?

**What is the action of the flexor digitorum longus muscle of the foot:**

- + flexes the distal phalanges of the 2nd – 5th toes, flexes the foot and supinates it;
- flexes the proximal phalanges of the 1st – 5th toes, flexes the foot and supinates it;
- flexes the distal phalanges of the 2nd – 5th toes and pronates the foot;
- flexes the distal phalanges of the 2nd – 5th toes and extends the foot?

**The flexor hallucis longus muscle is classified as:**

- + the deep layer of the posterior group of muscles of the leg;
- the superficial layer of the posterior group of muscles of the leg;
- the anterior group of muscles of the leg;
- the lateral group of muscles of the leg.

**Where does the flexor hallucis longus muscle originate:**

- + from the posterior surface of the shaft of the fibula and interosseous membrane;
- from the posterior surface of the tibial shaft and interosseous membrane;
- from the lateral and medial condyles of the tibia;
- from the head of the fibula?

**Where is the flexor hallucis longus muscle attached:**

- + to the base of the distal phalanx of the hallux;
- to the base of the proximal phalanx of the hallux;

- to the bases of the distal phalanges of the 1st – 5th toes;
- to the to the bases of the proximal phalanges of the 1st – 2nd toes?

**What is the action of the flexor hallucis longus muscle:**

- + flexes the great toe, flexes and adducts the foot, strengthens the longitudinal arch of the foot;
- flexes the great toe, flexes and supinates the foot;
- flexes the great toe, extends and pronates the foot;
- flexes the great toe, pronates and abducts the foot, strengthens the longitudinal arch of the foot.

**The tibialis posterior muscle is classified as:**

- + the deep layer of the posterior group of muscles of the foot;
- the superficial layer of the posterior group of muscles of the foot;
- the lateral group of muscles of the foot;
- the anterior group of muscles of the foot?

**Where does the tibialis posterior muscle originate:**

- + from the posterior surfaces of the tibia and fibula, from the interosseous membrane and crural fascia;
- from the lateral and medial condyles of the femur and interosseous membrane;
- from the lateral and medial condyles of the tibia and crural fascia;
- from the head of the fibula?

**Where is the tibialis posterior muscle attached:**

- + to the tuberosity of the navicular bone, to the three cuneiform bones and the bases of the 2nd – 4th metatarsal bones;
- to the cuboid and calcaneus;;
- to the tuberosity of the navicular bone and bases of the 1st – 5th metatarsal bones;
- to the bases of the proximal phalanges of the 2nd – 5th toes?

**What is the action of the tibialis posterior muscle:**

- + flexes, adducts and supinates the foot;

- flexes, abducts and pronates the foot;
- extends, abducts and supinates the foot;
- extends, adducts and pronates the foot?

**What muscles belong to the lateral group of muscles of the leg:**

- + the peroneus (fibularis) longus and brevis muscles;
- the popliteus and plantaris muscles;
- the flexor digitorum longus and flexor hallucis longus muscles;
- the extensor digitorum longus and extensor hallucis longus muscles?

**Where does the peroneus (fibularis) longus muscle originate:**

- + from the head and body of the fibula, lateral condyle of the tibia, crural fascia;
- from the lateral and medial condyles of the tibia;
- from the lateral and medial condyles of the femur, crural fascia;
- from the posterior surfaces of the tibia and fibula, crural fascia?

**Where is the peroneus (fibularis) longus muscle inserted:**

- + to the medial cuneiform bone and the bases of the 1st – 2nd metatarsal bones;
- to the calcaneal bone;
- to the navicular bone and the bases of the 2<sup>nd</sup> metatarsal bone;
- to the 4th metatarsal bones;
- to the cuboid bone?

**What is the action of the peroneus (fibularis) longus muscle:**

- + flexes and pronates the foot, strengthens the longitudinal and transverse arches of the foot;
- extends and pronates the foot, strengthens the transverse arch of the foot;
- flexes the foot and the 2nd – 5th toes, strengthens the longitudinal arch of the foot
- extends and supinates the foot?

**Where does the peroneus (fibularis) brevis muscle originate:**

- + from the lateral surface of the fibular body;
- from the lateral surface of the tibial body;
- from the interosseous membrane of the leg;
- from the lateral condyle of the tibia?

**Where is the peroneus (fibularis) brevis muscle attached:**

- + to the tuberosity of the 5th metatarsal bone;
- to the bases of the 1st – 2nd metatarsal bones;
- to the calcaneal and cuboid bones;
- to the tuberosity of the navicular bone?

**What is the action of the peroneus (fibularis) brevis muscle:**

- + flexes the foot, raises the lateral border of the foot (everts);
- extends the foot, raises the lateral border of the foot;
- flexes the foot, raises the medial border of the foot;
- extends and abducts the foot?

**Muscles of the foot are divided into groups:**

- + the dorsal and plantar muscles;
- the deep and superficial plantar muscles;
- the medial and lateral muscles;
- the lateral, medial and middle muscles.

**The extensor digitorum brevis muscle of the foot is classified as:**

- + the dorsal muscle of the foot;
- the medial group of the plantar muscles;
- the middle group of the plantar muscles;
- the lateral group of the plantar muscles.

**The extensor hallucis brevis muscle is classified as:**

- + the dorsal muscle of the foot;
- the medial group of the plantar muscles;
- the middle group of the plantar muscles;
- the lateral group of the plantar muscles.

**Muscles of the sole of the foot form the groups:**

- + the lateral, middle and medial groups;
- the superficial and deep groups;

- the anterior and posterior groups;
- the flexors and extensors.

***The medial group of the plantar muscles consists of:***

- + the abductor hallucis, flexor hallucis brevis and adductor hallucis muscles;
- the flexor hallucis brevis, quadratus extensor hallucis and quadratus plantae muscles;
- the adductor hallucis, abductor hallucis and lumbrical muscles;
- the abductor digiti minimi, flexor digiti minimi and opponens digiti minimi muscles.

***The muscles of the lateral group of the plantar muscles are:***

- + the abductor digiti minimi, flexor digiti minimi and opponens digiti minimi muscles;
- the abductor hallucis, flexor hallucis brevis and adductor hallucis muscles;
- the dorsal interossei, quadratus plantae and lumbrical muscles;
- the dorsal and plantar interossei muscles.

***The muscles of the middle group of the plantar muscles are:***

- + the flexor digitorum brevis, quadratus plantae, lumbrical, dorsal and plantar interossei muscles;
- the extensor digitorum brevis, extensor hallucis brevis muscles;
- the flexor hallucis brevis, extensor hallucis brevis and quadratus plantae muscles;
- the lumbrical, flexor digiti minimi and abductor digiti minimi muscles.

***What is the action of the dorsal interossei muscles:***

- + flex the toes at the metatarsophalangeal joints and extend the toes at the interphalangeal joints; abduct the toes from the 2nd toe;
- adduct the toes to the 2nd toe, flex the toes at the metatarsophalangeal joints;
- adduct the toes to the 1st toe, flex the 2nd – 5th toes at the metatarsophalangeal joints;
- extend the toes at the metatarsophalangeal joints, adducts the toes to the 2nd toe?

***What is the action of the plantar interossei muscles:***

- + adduct the 3rd – 5th toes to the 2nd toe, flex the toes at the metatarsophalangeal joints and extend the toes at the interphalangeal joints;
- adduct the toes to the 1st toe, flex the 2nd – 5th toes at the metatarsophalangeal joints;
- extend the toes at the metatarsophalangeal joints, abduct the 3rd – 5th toes from the 2nd toe;
- extend the toes at the interphalangeal joints, abduct the toes from the 3rd toe?

**Theme 19. Fasciae and topography of the lower limb**

***The iliopectineal arch passing between the inguinal ligament and the iliopubic eminence is the part of:***

- + the iliac fascia;
- the gluteal fascia;
- the fascia lata;
- the superficial fascia.

***The iliopectineal arch divides the space below the inguinal ligament into two parts:***

- + the muscular part (lacuna musculorum) and vascular part (lacuna vasorum);
- the foramen suprapiriforme and foramen infrapiriforme;
- the obturator canal and femoral canal;
- the obturator canal and femoral groove.

***What is the lacuna musculorum bounded medially by:***

- + the iliopectineal arch;
- the lateral process of the inguinal ligament;
- the ilium;
- the lacunar ligament?

***What is the lacuna musculorum bounded anteriorly by:***

- + the inguinal ligament;
- the iliopectineal arch;
- the ilium;
- the lacunar ligament?

**What is the lacuna musculorum bounded posteriorly by:**

- + the ilium;
- the lacunar ligament;
- the iliopectineal arch;
- the inguinal ligament?

**What is the lacuna vasorum bounded anteriorly by:**

- + the inguinal ligament;
- the iliopectineal arch;
- the lacunar ligament;
- the pectineal ligament?

**What is the lacuna vasorum bounded posteriorly by:**

- + the pectineal ligament;
- the inguinal ligament;
- the iliopectineal arch;
- the lacunar ligament?

**What is the lacuna vasorum bounded laterally by:**

- + the iliopectineal arch;
- the inguinal ligament;
- the lacunar ligament;
- the pectineal ligament?

**What is the lacuna vasorum bounded medially by:**

- + the lacunar ligament;
- the pectineal ligament;
- the inguinal ligament;
- the iliopectineal arch?

**What passes through the lacuna musculorum:**

- + the iliopsoas muscle and femoral nerve;
- the femoral artery, femoral vein and femoral nerve;
- the iliopsoas muscle, femoral artery and vein;
- the piriformis muscle and obturator nerve?

**What passes through the lacuna vasorum:**

- + the femoral artery and vein;
- the iliopsoas muscle and femoral nerve;
- the femoral artery, vein and nerve;
- the piriformis muscle and obturator nerve?

**The piriformis muscle passes through the greater sciatic foramen: above it, there is a**

**narrow opening:**

- + the suprapiriform foramen;
- the infrapiriform foramen;
- the lacuna musculorum;
- the canalis obturatorius.

**The piriformis muscle passes through the greater sciatic foramen: below it, there is a narrow opening:**

- + the infrapiriform foramen;
- the suprapiriform foramen;
- the lacuna vasorum;
- the saphenous hiatus.

**What fascia invests the muscles of the thigh:**

- + the fascia lata;
- the deep layer of the gluteal fascia;
- the fascia iliaca;
- the iliopectineal fascia?

**Where does the fascia lata divide into superficial and deep layers:**

- + below the inguinal ligament within the boundaries of the femoral triangle;
- within the boundaries of the posterior region of the thigh;
- within the boundaries of the medial region of the thigh;
- within the boundaries of the lower part of the anterior region of the thigh?

**What anatomical structure is located between two muscles, the pectineus muscle and the iliopsoas muscle:**

- + the iliopectineal groove;
- the femoral groove;
- the femoral canal;
- the obturator canal?

**What anatomical structure is formed by the superficial layer of the fascia lata below the middle 1/3 of the inguinal ligament:**

- + the hiatus saphenus;
- the femoral ring;
- the lacuna vasorum;
- the obturator canal?

**What is the hiatus saphenus bounded by:**

- + the falciform margin laterally, the superior and the inferior horns of the falciform margin above and below;
- the falciform margin medially, the superior and inferior horns of the falciform margin above and below;
- the inguinal ligament above, below the falciform ligament;
- the femoral vein laterally, the lacunar ligament medially, the superior and inferior horns of the falciform margin above and below?

***Which muscles of the thigh does the lateral intermuscular septum separate:***

- + the quadriceps femoris muscle from the posterior group of muscles of the thigh;
- the quadriceps femoris muscle from the adductor muscles;
- the adductor muscles from the posterior group of muscles of the thigh;
- the heads of the quadriceps femoris muscle?

***Which muscles of the thigh does the medial intermuscular septum separate:***

- + the quadriceps femoris muscle from the adductor muscles;
- the quadriceps femoris muscle from the posterior group of the muscles of the thigh;
- the adductor muscles from the posterior group of the muscles of the thigh;
- the heads of the quadriceps muscle?

***What is the obturator canal formed by:***

- + the obturator groove of the pubis and the superior margin of the obturator internus muscles;
- the obturator groove of the pubis and the quadratus femoris muscles;
- the obturator foramen of the hip bone and the piriformis muscle;
- the obturator foramen of the hip bone, the obturator internus and externus muscles and the gemelli muscles?

***What closes the external opening of the obturator canal:***

- + the pectineus muscle;
- the adductor brevis muscle;

- the obturator externus muscle;
- the iliopsoas muscle?

***What is the femoral triangle bounded superiorly by:***

- + the inguinal ligament;
- the sartorius muscle;
- the adductor longus muscle;
- the adductor magnus muscle?

***What is the femoral triangle bounded laterally by:***

- + the sartorius muscle;
- the inguinal ligament;
- the adductor brevis muscle;
- the gracilis muscle?

***What is the femoral triangle bounded medially by:***

- + the adductor longus muscle;
- the sartorius muscle;
- the inguinal ligament;
- the gracilis muscle?

***What is the iliopectineal groove bounded medially by:***

- + the pectineus muscle;
- the iliopsoas muscle;
- the adductor brevis muscle;
- the adductor longus muscle?

***What is the iliopectineal groove bounded laterally by:***

- + the iliopsoas muscle;
- the pectineus muscle;
- the sartorius muscle;
- the adductor longus muscle?

***The sulcus iliopectineus is continuous inferiorly with:***

- + the femoral groove;
- the femoral triangle;
- the adductor canal;
- the obturator canal.

***What is the femoral groove bounded laterally by:***

- + the vastus medialis muscle;
- the adductor longus muscle;
- the sartorius muscle;



– the pectineus muscle?

**What is the femoral groove bounded medially by:**

- + the adductor longus muscle;
- the vastus medialis muscle;
- the sartorius muscle;
- the pectineus muscle?

**The femoral groove is continuous inferiorly with:**

- + the adductor canal;
- the femoral canal;
- the obturator canal;
- the popliteal fossa.

**What is the anterior wall of the femoral canal:**

- + the superficial layer of the fascia lata;
- the deep layer of the fascia lata;
- the femoral vein;
- the inguinal ligament?

**What is the posterior wall of the femoral canal:**

- + the deep layer of the fascia lata covering the pectineus muscle;
- the superficial layer of the fascia lata;
- the femoral vein;
- the superior and inferior horns of the falciforme margin?

**What is the lateral wall of the femoral canal:**

- + the femoral vein;
- the femoral artery;
- the falciforme margin;
- the deep layer of the fascia lata?

**What is the internal opening of the femoral canal (the inlet when the protrusion of a femoral hernia occurs):**

- + the femoral ring;
- the hiatus saphenus;
- the lacuna vasorum;
- the lacuna musculorum?

**The femoral ring is bounded anteriorly by:**

- + the inguinal ligament;
- the pectineal ligament;
- the lacunar ligament;
- the femoral vein.

**The femoral ring is bounded posteriorly by:**

- + the pectineal ligament;
- the inguinal ligament;
- the lacunar ligament;
- the femoral vein.

**The femoral ring is bounded medially by:**

- + the lacunar ligament;
- the pectineal ligament;
- the inguinal ligament;
- the femoral vein.

**The femoral ring is bounded laterally by:**

- + the femoral vein;
- the lacunar ligament;
- the pectineal ligament;
- the inguinal ligament.

**What is the external opening of the femoral canal (the outlet when the protrusion of a femoral hernia occurs):**

- + the hiatus saphenus;
- the femoral ring;
- the lacuna vasorum;
- the lacuna musculorum?

**Where does the adductor canal rise from:**

- + the apex of the femoral triangle;
- the femoral canal;
- the obturator canal;
- the upper part of the cruropliteal canal?

**What regions of the lower limb does the adductor canal connect:**

- + the anterior region of the thigh with the popliteal fossa;
- the pelvic cavity with the medial region of the thigh;
- the pelvic cavity with the lateral region of the thigh;
- the anterior and medial regions of the thigh?

**What walls has the adductor canal:**

- + the lateral, medial and anterior;
- the lateral, medial and posterior;
- the anterior and posterior;
- the superior and inferior?

**What openings has the adductor canal:**

- + the superior (inlet), inferior (outlet) and anterior;
- the medial (inlet), lateral (outlet) and anterior;
- the posterior (inlet) and inferior (outlet);
- the deep (inlet) and superficial (outlet)?

**What forms the medial wall of the adductor canal:**

- + the adductor magnus muscle;
- the adductor longus muscle;
- the vastus medialis muscle;
- the vastus lateralis muscle?

**What forms the lateral wall of the adductor canal:**

- + the vastus medialis muscle;
- the vastus lateralis muscle;
- the adductor magnus muscle;
- the adductor longus muscle?

**What form the anterior wall of the adductor canal:**

- + lamina vastoadductoria;
- the sartorius muscle;
- the tendinous plate between the adductor magnus and adductor longus muscles;
- the vastus medialis muscle?

**Where is the anterior opening of the adductor canal located:**

- + on the anterior wall of the adductor canal (in lamina vastoadductoria);
- between the tendons of the adductor magnus muscle on the posterior surface of the thigh;
- between the tendons of the adductor longus and adductor magnus muscles on the medial wall of the adductor canal;
- between the tendons of the vastus medialis and vastus intermedius on the lateral wall of the adductor canal?

**The crural fascia gives off the intermuscular septa:**

- + the anterior and posterior septa;
- the medial and lateral septa;
- the anterior and lateral septa;
- the posterior and medial septa.

**The anterior intermuscular septum separates the muscles of the leg:**

- + the anterior group from the lateral group;
- the anterior group from the medial group;
- the anterior group from the posterior group;
- the lateral group from the medial group.

**Between the lateral and posterior groups of the muscles of the leg, there is:**

- + the posterior intermuscular septum;
- the anterior intermuscular septum;
- the medial intermuscular septum;
- the lateral intermuscular septum.

**What is the anatomical position of the superior extensor retinaculum:**

- + draws over the anterior border of the tibia and lateral surface of the fibula above the malleoli;
- draws over the calcaneus and talus;
- draws over the head of talus and lateral surface of the fibula;
- draws over the head of talus and anterior border of the tibia?

**What is the anatomical position of the inferior extensor retinaculum:**

- + originates from the calcaneus by its stem and separates into two bands, the superior and inferior;
- draws over the anterior border of the tibia and lateral surface of the fibula above the malleoli;
- draws over the calcaneus and talus and separates into two bands, the superior and inferior;
- originates from the medial malleolus and attaches to the lateral malleolus?

**What passes through the fibrous canals located under the inferior extensor retinaculum:**

- + 3 synovial tendon sheaths of extensor muscles and the 4th canal for vessels and the nerve;
- 4 synovial tendon sheaths of extensor muscles;
- 1 synovial sheath for vessels and the nerve;
- 2 synovial sheaths of tendons of extensor muscles and the 3rd canal for vessels and

the nerve?

**How are the synovial tendon sheaths of the extensor muscles arranged under the inferior extensor retinaculum (named from the great toe):**

- + the synovial tendon sheaths of the tibialis anterior muscle, the extensor hallucis longus muscle and the extensor digitorum longus muscle;
- the synovial tendon sheaths of the extensor digitorum longus muscle, the extensor hallucis longus muscle and the tibialis anterior muscle;
- the synovial tendon sheaths of the tibialis anterior muscle, the extensor digitorum longus muscle and the extensor hallucis longus muscle;
- the synovial tendon sheaths of the tibialis anterior muscle, the extensor hallucis longus muscle and the peroneus brevis muscle?

**What is the anatomical position of the flexor retinaculum of the foot:**

- + passes from the medial malleolus to the medial surface of the calcaneus;
- passes from the lateral malleolus to the lateral surface of the calcaneus;
- passes between the anterior margin of the tibia and the lateral surface of the fibula;
- passes between the malleoli and separates into two limbs?

**How are the synovial tendon sheaths of the flexor muscles arranged under the flexor retinaculum of the foot (from anterior to posterior):**

- + the synovial tendon sheaths of the tibialis posterior muscle, the flexor digitorum longus muscle and the flexor hallucis longus muscle;
- the synovial tendon sheaths of the flexor hallucis longus muscle, the tibialis posterior muscle and fibrous canal for vessels and the nerve;
- the synovial tendon sheaths of the flexor digitorum longus muscle, the flexor hallucis longus muscle and the tibialis posterior muscle;
- the synovial tendon sheaths of the tibialis

posterior muscle, the peroneus longus muscle and the peroneus brevis muscle?

**What is the anatomical position of the superior and inferior peroneal retinaculum:**

- + passes between the lateral malleolus and lateral surface of the calcaneus;
- passes between the medial malleolus to the medial surface of the calcaneus;
- passes between the tibia and fibula at the level of bases of malleoli;
- passes between the lateral and medial malleoli?

**What synovial sheaths are under the superior peroneal retinaculum:**

- + the common synovial tendon sheath of the peroneal muscles;
- the common synovial tendon sheath of the tibialis anterior and posterior muscles;
- the synovial sheaths of the extensor digitorum longus and the peroneus tertius muscles;
- the synovial sheaths of the peroneus longus and tibialis anterior muscles?

**What anatomical structure stretches under the skin in the middle of the sole from calcaneal tuberosity to the base of toes:**

- + the plantar aponeurosis;
- the intermuscular septa;
- the flexor retinaculum of the foot;
- the inferior extensor retinaculum of the foot?

**What anatomical structure is located on the posterior surface of the knee joint, shaped like a rhomb:**

- + the popliteal fossa;
- the rhomboid fossa;
- the iliopectineal fossa;
- the cruro–popliteal canal?

**What angles have the popliteal fossa:**

- + the superior and inferior angles;
- the medial and lateral angles;
- the superficial and deep angles;
- the anterior and posterior angles?

**The superior angle of the popliteal fossa is formed by:**

- + the biceps femoris muscle laterally and the semimembranosus muscles medially;
- the semimembranosus muscle laterally and the biceps femoris muscle medially;
- the semitendinosus muscle laterally and the semimembranosus muscle medially;
- the sartorius muscle laterally and the biceps femoris muscle medially.

***What is the inferior angle of the popliteal fossa formed by:***

- + both heads of the gastrocnemius muscle;
- lateral and medial heads of the soleus muscle;
- the plantaris muscle laterally, the popliteus muscle medially;
- the popliteus muscle laterally, the soleus muscle medially?

***The floor of the popliteal fossa is formed by:***

- + the popliteal surface of the femur and the posterior wall of the knee joint;
- the popliteal muscle;
- the triceps surae muscle;
- the fascia lata.

***What walls has the cruropliteal canal:***

- + the anterior and posterior walls;
- the medial, lateral and anterior walls;
- the anterior, posterior and lateral walls;
- the superior and inferior walls?

***What is the anterior wall of the cruropliteal canal formed by:***

- + the tibialis posterior and flexor hallucis longus muscles;
- the soleus muscle;
- the gastrocnemius muscle;
- the flexor hallucis longus, flexor digitorum longus and plantaris muscles?

***What is the posterior wall of the cruropliteal canal formed by:***

- + the soleus muscle;
- the tibialis posterior muscle;
- the triceps surae muscle;
- the flexor hallucis longus muscle?

***The cruropliteal canal has openings:***

- + the superior, anterior and inferior openings;

- the superior, inferior and posterior openings;
- the posterior and anterior openings;
- the medial and lateral openings.

***Which opening is the inlet into the cruropliteal canal:***

- + the superior opening;
- the inferior opening;
- the anterior opening;
- the posterior opening.

***Which openings are the outlets of the cruropliteal canal:***

- + the anterior and inferior openings;
- the anterior and posterior openings;
- the superior and inferior openings;
- the superior and anterior openings?

***What is the superior opening of the cruropliteal canal bounded by:***

- + the popliteus muscle anteriorly, the tendinous arch of the soleus muscle posteriorly;
- the tendinous arch of the soleus muscle anteriorly, the popliteus muscle posteriorly;
- the tibialis posterior muscle anteriorly, the soleus muscle posteriorly;
- the soleus muscle anteriorly, the gastrocnemius muscle posteriorly?

***Where is the anterior opening of the cruropliteal canal located:***

- + in the proximal part of the interosseous membrane between the leg bones;
- in the distal part of the interosseous membrane between the leg bones;
- between the tendinous arch of the soleus muscle and the popliteus muscle;
- in the upper 1/3 of the leg between the fibula and peroneus longus muscle?

***Where is the inferior opening of the cruropliteal canal located:***

- + in the lower 1/3 of the leg on the medial side of the tendon of soleus muscle;
- in the lower 1/3 of the leg on the lateral side of the tendon of the soleus muscle;
- in the lower part of the interosseous membrane between the leg bones;

- between the tendons of the flexor hallucis longus and flexor digitorum longus muscles.

**What anatomical structure originates in the upper 1/3 of the leg from the cruropopliteal canal passing downward and laterally:**

- + the inferior musculoperoneal canal;
- the superior musculoperoneal canal;
- the anterior peroneal canal;
- the anterior peroneal groove?

**What is the inferior musculoperoneal canal formed by:**

- + the fibula anteriorly, the flexor hallucis longus muscle posteriorly;
- the fibula anteriorly, the peroneus longus muscle posteriorly;
- the peroneus longus and brevis muscles;
- the fibula anteriorly, the flexor digitorum longus muscle posteriorly?

**What structure is the upper third of the leg between the fibula and peroneus longus muscle:**

- + the superior musculoperoneal canal;
- the inferior musculoperoneal canal;
- the cruropopliteal canal;
- the popliteal fossa?

**What is the superior musculoperoneal canal formed by:**

- + the fibula and the peroneus longus muscle;
- the peroneus longus and brevis muscles;
- the fibula and the flexor hallucis longus muscle;
- the fibula and plantaris muscle?

**The medial groove of the sole is found between the following muscles:**

- + the flexor digitorum brevis and the abductor hallucis muscles;
- the abductor hallucis and abductor digiti minimi muscles;
- the flexor digitorum brevis and flexor hallucis brevis muscles;
- the flexor hallucis brevis and flexor digiti minimi muscles.

**The lateral groove of the sole is found between the following muscles:**

- + the flexor digitorum brevis and the abductor digiti minimi muscles;
- the flexor hallucis brevis and flexor digiti minimi muscles;
- the flexor digitorum brevis and flexor hallucis brevis muscles;
- the abductor hallucis and abductor digiti minimi muscles.

## MODULE I. CLINICAL TASKS

**To what anatomical formation is it necessary to press a common carotid artery to stop bleeding:**

- + body of VII cervical vertebra;
- anterior tubercle of transverse process of VI cervical vertebra;
- anterior tubercle of transverse process of V cervical vertebra;
- transverse process of VII cervical vertebra;
- posterior tubercle of transverse process of VI cervical vertebra.

**A 12-month-old normally developed child can hold a head, sit and stand. What curvatures of vertebral column were formed:**

- + thoracic and sacral;
- cervical, thoracic, lumbar and sacral;
- cervical and lumbar;
- thoracic and lumbar;
- cervical, thoracic and sacral?

**What part of the vertebral column was injured if the blood supply to the posterior part of the brain is disturbed:**

- + thoracic part;
- cervical part;
- lumbar part;
- sacral part;
- coccygeal part?

**A spinal hernia (protrusion of a spinal cord) is determined in the region of XII thoracic vertebra. Nonfusion of what anatomic formation was the cause of the spinal**

**hernia:**

- + body of a vertebra;
- arch of a vertebra;
- intervertebral disk;
- articular processes;
- spinous processes?

**Nonfusion of arches of III and IV lumbar vertebrae was revealed on X-ray film. What fusion anomaly is this:**

- + kyphosis;
- spina bifida;
- palatum fissum;
- lordosis;
- scoliosis?

**A 10-year-old child has a flexure of the thoracic part of the vertebral column to the left. What can be diagnosed in the patient:**

- + cervical kyphosis;
- left side thoracic scoliosis;
- right side lumbar scoliosis;
- thoracic lordosis;
- lumbar lordosis?

**A boy jumped from a tower in water and had hit on a stone in the lower region of the sternum. Fracture of what formation of the sternum has taken place:**

- + handle of the sternum;
- xiphoid process;
- angle of the sternum;
- body of the sternum;
- acinaciform process?

**A patient has received a trauma in the region of the handle of the sternum in a road accident. What ribs are damaged:**

- + III – IV ribs;
- I – II ribs;
- V – VI ribs;
- I – III ribs;
- IX – X ribs?

**A patient had pneumonia after which the pleuritis developed. How to perform a pleurocentesis:**

- + by insertion of aspirating needle on the inferior edge of the rib;
- by insertion of aspirating needle on the

superior edge of a rib;

- by insertion of aspirating needle between spinous processes of thoracic vertebrae;
- by insertion of aspirating needle between transverse processes of thoracic vertebrae;
- by insertion of an aspirating needle between articular processes of thoracic vertebrae?

**As a result of a road accident there was a fracture of 3 – 4 – 5 ribs on the right side in the middle part of the ribs. What parts of ribs have undergone trauma:**

- + necks of ribs;
- bodies of ribs;
- heads of ribs;
- articular processes of ribs;
- crests of ribs?

**During medical examination of the patient a flat shape of a thoracic cage has been found out. What type of body build is such shape specific for:**

- + brachimorphic;
- dolichomorphic;
- dolichocephal;
- brachicephal;
- mesomorphic?

**In man, on the right side in the area of the inferior angle of scapula there are determined fractures of ribs. What ribs have been damaged:**

- + VIII – IX;
- VI – VII;
- X – XI;
- XI;
- I – III?

**After a road accident a patient had fractures of bones at the region of the deltoid muscle. What parts of bones have trauma:**

- + the superior third of metatarsal the humerus and a coracoid process;
- the superior third of the humerus and acromion of the scapula;
- the acromial end of the clavicle and infraspinatus fossa;
- acromion and the inferior third of the humerus;

- acromion and tubercles of the a humerus?

**After falling on the right hand adducted to a trunk the victim has a fracture of the superior third of the right arm. What bones has been injured:**

- + sternum;
- humerus;
- scapula;
- clavicle;
- ribs?

**A patient has been delivered to a hospital with a fracture of the humerus. What part of the humerus is most frequently injured:**

- + in the region of lateral epicondyle;
- in the region of surgical neck;
- in the region of the body;
- in the region of anatomical neck;
- in the region of the head of the humerus?

**The most often fractures of bones happen in the region of the surgical neck. Specify where the surgical neck is located:**

- + radius;
- humerus;
- femur;
- fibula;
- talus.

**Why do fractures of the distal epiphysis of the humerus happen more often in children:**

- + due to the weakness of ligaments;
- since there is a cartilage between the epiphysis and diaphysis (the uncompleted ossification);
- due to insufficient blood supply;
- due to the underdevelopment of the capsule of the joint;
- due to delicacy of surrounded muscles.

**A patient has an abruption of medial humeral epicondyle resulting in disturbance of innervation. What nerve was damaged:**

- + interosseous nerve;
- ulnar nerve;
- radial nerve;
- median nerve;
- radial nerve?

**A patient has an injury in the region of the**

**middle third of the humerus; thus the extension of the forearm is affected. What bone formation is injured:**

- + groove of the biceps brachii muscle;
- groove of the radial nerve;
- groove of the median nerve;
- groove of the humeral nerve;
- groove of the ulnar nerve?

**After a fall on the right arm, the man has felt a severe pain in the region of a posterior part of the elbow joint. What process and what bone have undergone trauma:**

- + radial process of the radius;
- olecranon of the ulna;
- styloid process of the ulna;
- coronoid process of the ulna;
- radial process of the radius?

**A trauma was received in the region of the middle of the lateral part of the forearm. What bone and what its part has undergone trauma:**

- + apophysis of the radius;
- diaphysis of the radius;
- apophysis of the ulna;
- epiphysis of the ulna;
- diaphysis of the ulna?

**A fracture of a laterally situated bone of the forearm in the inferior third is found on X-ray film. What bone of the forearm and what its part are fractured:**

- + ulna, metaphysis;
- radius, an epiphysis;
- ulna, an epiphysis;
- ulna, a diaphysis;
- radius, a diaphysis?

**A trauma was received in the region of the medial part of the wrist. Which of the wrist bones has, most likely, undergone trauma:**

- + cuboid;
- pisiform;
- capitate;
- trapezoid;
- scaphoid?

**After a road accident, there was a trauma in the region of the posterior part of the lesser pelvis. What bone formations of a lesser**

***pelvis have undergone trauma:***

- + coccyx;
- sacrum;
- ischium;
- ilium;
- pubic bone?

***After a road accident a woman had a trauma in the region of the anterior part of the hip bone. Which bone of the pelvis is injured:***

- + ischium;
- pubic;
- ilium;
- sacral;
- femur?

***An obstetrician has measured the distance between two superior anterior iliac spines in the pregnant woman. What size of the big pelvis has been determined:***

- + distantia cristarum;
- distantia spinarum;
- distantia trochanterica;
- conjugata vera;
- conjugata anatomica?

***After a fall, a 70-year-old man had a fracture of a femur. What is the most frequent place of fracture of this bone at the given age:***

- + superior third of femur;
- neck of femur;
- body of femur;
- greater trochanter;
- inferior third of femur?

***A 78-year-old woman has traumatized the upper segment of free lower limb after falling. What bone was traumatized:***

- + fibula;
- femur;
- tibia;
- talus;
- calcaneus?

***A patient got trauma on the medial side of the superior third of the leg. Which the bones of the leg and what its part are injured:***

- + diaphysis of the fibula;

- metaphyseal zone of the tibia;
- metaphyseal zone of the fibula;
- diaphysis of the tibia;
- apophysis of a tibia?

***A man got trauma as a result of the direct impact on the internal surface of the middle third of the shin. Fracture of what anatomic formation is the most possible:***

- + distal epiphysis of the fibula;
- diaphysis of the tibia;
- distal epiphysis of the tibia;
- proximal epiphysis of the tibia;
- proximal epiphysis of the fibula?

***A patient complains of pain in the region of the medial side of the dorsum of the foot. What tarsal bones fracture is the most probable in this case:***

- + calcaneus;
- navicular;
- cuboid;
- lateral cuneiform;
- talus?

***There is only one ossification center within the femoral head on the radiograph. How old is a child:***

- + 8 years-old;
- 1 year-old;
- 5 years-old;
- 15 years-old;
- 7 years-old?

***An ossification center in the lateral cuneiform bone is revealed on the radiograph of the child foot. How old is the child:***

- + 5 year-old;
- 1 year-old;
- 8 year-old;
- 15 year-old;
- 7 year-old?

***A football player got a knee joint. X-ray examination revealed a fracture of the bone placed within a tendon of the quadriceps femoris muscle. What kind of bone is it:***



- + tubular;
- sesamoid;
- flat;
- pneumatic;
- mixed?

***In the posterior superior part of the head, there is a scalped wound. What bones are damaged:***

- + sphenoid and lacrimal bones;
- parietal and occipital bones;
- ethmoid bone and mandible;
- frontal and nasal bones;
- temporal bone and maxilla?

***The lacrimal gland together with the bone, on which it is lying, was damaged in a road accident. What bone was damaged:***

- + maxilla;
- frontal;
- lacrimal;
- nasal;
- ethmoid?

***The line of the fracture of the skull base passes through the round spinous foramen. What bone is injured as a result of trauma:***

- + temporal;
- sphenoid;
- frontal;
- ethmoid;
- occipital?

***At the X-ray film of the skull the fracture line passes a border of temporal and occipital bones. What aperture is injured as a result of trauma:***

- + stylomastoid;
- jugular;
- mastoid;
- condyloid;
- foramen magnum?

***In the patient, during an inflammation of the middle ear, the innervation of the muscles of facial expression is damaged. What canal is involved in the process:***

- + tympanic canal;

- facial nerve canal;
- mastoid canal;
- canalis musculotubarius;
- chorda tympani canal?

***What anatomic formation can infection penetrate through into the tympanic cavity from nasopharynx:***

- + canaliculus tympanicus;
- semicanalis tubae auditivae;
- semicanalis m. tensor tympani;
- canaliculus caroticotympanicus;
- canalis caroticus?

***As a result of infection in nasopharynx, the otitis has developed in the child. What canal has the infection penetrated through into a tympanic cavity:***

- + carotico–tympanic;
- musculotubarius;
- carotid;
- facial;
- chorda tympani?

***A right–side fracture of the middle third of the mandible is revealed in the victim. What canalis injured:***

- + greater palatine;
- mandibular;
- pterygoid;
- infraorbital;
- lesser palatine?

***As a result of trauma of the maxilla, a numbness is marked in the region of the molars and gum. Which of the listed formations is damaged:***

- + infraorbital canal;
- alveolar foramina of the maxilla;
- ethmoid aperture of the maxilla;
- infraorbital foramen of the maxilla;
- supraorbital foramen of the maxilla?

***A man cannot move the mandible, eat and talk because of a pain in the region of a temporomandibular joint. What osteal formation is damaged:***

- + coronal process of the mandible;

- condyloid process of the mandible;
- styloid process of the temporal bone;
- mastoid process of the temporal bone;
- zygomatic process of a temporal bone?

***At a purulent highmoritis (inflammation of the maxillary air sinus mucosa) the puncture for washing the sinus is made through:***

- + the infraorbital foramen;
- the region of a middle nasal meatus;
- the major palatine canal;
- the region of the superior nasal meatus;
- the nasolacrimal canal.

***A patient suffers from frontal sinusitis. What department of the nasal cavity may infection spread from in a frontal sinus:***

- + from the sphenothmoid recess;
- from the middle nasal meatus;
- from the superior nasal meatus;
- from the inferior nasal meatus;
- from vestibule of the nasal cavity?

***The inflammation of a sphenoid sinus is observed in the patient. Where does its aperture open:***

- + frontal air sinus;
- meatus nasi superior;
- meatus nasi medius;
- meatus nasi inferior;
- meatus nasi communis?

***The patient's nasal cavity contains an abundance of mucus that covers nasal mucosa and blocks olfactory receptors. Where are they located:***

- + middle nasal concha;
- superior nasal concha;
- inferior nasal concha;
- common nasal meatus;
- inferior nasal meatus.

***A patient suffers from frontitis and highmoritis (inflammation of the paranasal sinuses mucosa). Where does the exudation from these sinuses discharge to:***

- + superior nasal meatus;
- middle nasal meatus;
- inferior nasal meatus;

- nasal vestibule;
- nasolacrimal canal?

***A patient with chronic rhinitis (inflammation of the nasal mucosa) has the inflammation of maxillary sinus mucosa. What formation has the infection been spread through:***

- + ethmoid infundibulum;
- semilunar hiatus;
- sphenopalatine foramen;
- sphenothmoid recess;
- ethmoid air cells?

***A patient with chronic rhinitis (inflammation of the nasal mucosa) has inflammation of the frontal sinus mucosa. What formation has the infection spread through:***

- + semilunar hiatus.;
- ethmoid infundibulum;
- sphenopalatine foramen;
- sphenothmoid recess;
- ethmoid air cells?

***A doctor has detected the discharge of pus from the left middle nasal meatus during nasal examination. Inflammation of which sinuses can be supposed in this situation:***

- + maxillary and sphenoid;
- maxillary, frontal, anterior and middle ethmoid air cells;
- frontal, sphenoid, anterior and posterior ethmoid air cells;
- anterior, middle and posterior ethmoid air cells;
- sphenoid, posterior ethmoid air cells?

***During a street fight a young man got a fracture of the anterior part of the nasal septum. Which of bones forming the septum has been damaged:***

- + nasal;
- ethmoid;
- vomer;
- palatine;
- rostrum of the sphenoid bone?

***As a result of the nasal trauma the woman lost the sense of smell. What bones of a skull***

**have been traumatised:**

- + frontal;
- ethmoid;
- zygomatic;
- temporal;
- sphenoid?

**In the patient an inflammation of a nasal mucosa has become complicated by the inflammation of an eye conjunctiva. What anatomic formation has an infection penetrated through:**

- + sphenopalatine foramen;
- nasolacrimal canal;
- hiatus semilunaris;
- greater palatine canal;
- lesser palatine canal?

**As a result of trauma of the right orbit the impairment of movement of the right eyeball is observed. What from the listed formation is damaged:**

- + inferior orbital fissure;
- superior orbital fissure;
- optic canal;
- anterior occipital aperture;
- posterior ethmoid aperture?

**In the patient the complete blindness has occurred after a road accident. What canal and nerve have been damaged:**

- + superior orbital fissure and an optic nerve;
- optic canal and an optic nerve;
- inferior orbital fissure and an optic nerve;
- optic canal and an orbital branch of a trigeminal nerve;
- superior orbital fissure and an optic canal?

**As the result of trauma to the eye, there was a festering of soft tissues of an orbit. Through what anatomic formation can pus distribute into the pterygopalatine fossa:**

- + the round foramen;
- the inferior orbital fissure;
- the zygomatico-orbital foramen;
- sphenopalatine foramen;
- the superior orbital fissure?

**As a result of purulent otitis the superior wall of a tympanic cavity has been damaged. In**

**what fossa of a skull has the pus from the tympanic cavity distributed:**

- + in the orbit;
- in the middle cranial fossa;
- in the pterygopalatine fossa;
- in the anterior cranial fossa;
- in the posterior cranial fossa?

**In a patient a fracture of the central part of the roof of a skull has been revealed on the X-ray film. Which of bones of the skull is damaged:**

- + sphenoid;
- parietal;
- occipital;
- temporal;
- frontal?

**As a result of the road accident there was damage of the hypophysis and the central part of the base of the skull. Which of bones has been damaged:**

- + frontal;
- sphenoid;
- temporal;
- parietal;
- ethmoid?

**How can inflammatory process spread from the occipital region into the cranial cavity:**

- + via parietal foramen;
- via condyloid canal;
- via mastoid foramen;
- via foramen spinosum;
- via foramen ovale?

**Dissolution of the orbital wall may happen as a result of a purulent inflammation of the maxilla. The orbital wall can dissolve:**

- + superiorly;
- inferiorly;
- medially;
- laterally;
- posterior?

**Inflammation of the tympanic mucosa was complicated by the inflammation of the cerebral meninges. Through which tympanic wall may infection penetrate into the cranial cavity:**

- + inferior;
- superior;
- lateral;
- medial;
- posterior?

**What is the most probable source of spreading purulent inflammation into mastoid cells:**

- + sterno–cleido–mastoid muscle;
- tympanic cavity;
- diploe of the occipital bone;
- subcutaneous fatty tissue;
- middle cranial fossa?

**Which of listed below is the most probable channel for spreading infection from pterygopalatine fossa:**

- + subaponeurotic space;
- orbit;
- tympanic cavity;
- frontal sinus;
- interpterygoid space?

## MYOLOGY

**A disturbance of eyelid closure is detected in patients during the examination. What muscle damage can be suspected:**

- + m. procerus;
- m. orbicularis oculi;
- m. orbicularis oris;
- m. corrugator supercilii?

**During the examination the patient cannot round the lips and whistle, oral fissure stretches to the sides (a transversal smile). What muscle atrophy do these symptoms point out:**

- + zygomatic major muscle;
- orbicularis oris muscle;
- buccinator muscle;
- masseter muscle;
- risorius muscle?

**A patient's cheek was deeply cut with a dental instrument during the treatment of an upper second premolar tooth. What muscle is damaged:**

- + masseter muscle;

- buccinator muscle;
- orbicularis oris muscle;
- greater zygomatic muscle;
- mylohyoid muscle?

**A patient cannot lift the lowered mandible.**

**What muscles cannot function:**

- + levator angulis oris muscle;
- masseter muscle;
- orbicularis oris muscle;
- muscles of the facial expression;
- epicranial muscle?

**An old patient was delivered to the emergency department with a wound in the posterior region of his neck (region nuchae). What muscle does this area occupy:**

- + scalenus posterior;
- trapezius;
- sternocleidomastoideus;
- latissimus dorsi;
- rhomboideus?

**An old patient was delivered to the emergency ward with a wound in his neck within a triangle bounded by m. trapezius posteriorly. Within what triangle should operation be performed:**

- + trigonum omoclaviculare;
- trigonum omotrapezoideum;
- trigonum omotracheale;
- trigonum caroticum;
- trigonum submandibulare?

**An abscess is detected in the posterior wall of a pharynx in the patient after the examination. What is the most probable way of spreading the inflammatory process:**

- + through the retrovisceral space to the anterior mediastinum;
- through the retrovisceral space to the posterior mediastinum;
- through the previsceral space to the posterior mediastinum;
- through the previsceral space to the anterior mediastinum;
- through the interaponeurotic space to the posterior mediastinum?

**A doctor has established the diagnosis to a patient after the examination: a retropharyngeal abscess. What interfascial spaces the purulent inflammation can be spread to:**

- + anterior mediastinum;
- posterior mediastinum;
- suprasternal interfascial space of the neck;
- anterior fascial space of the neck;
- posterior fascial space of the neck?

**The massage of the muscle antagonist to abduction is necessary because of the difficult abduction of an arm. What muscle's region massage should the doctor prescribe:**

- + brachial muscle;
- latissimus dorsi muscle;
- deltoid muscle;
- trapezius muscle;
- biceps brachii muscle?

**A conductor of an orchestra cannot get a handkerchief out from a back pocket of the trousers. What muscle does not carry out the function:**

- + rhomboid muscle;
- latissimus dorsi muscle;
- deltoid muscle;
- pectoralis major muscle;
- trapezius muscle?

**A patient cannot abduct the upper limb. What muscle does not carry out the function:**

- + teres major muscle;
- deltoid muscle;
- infraspinatus muscle;
- teres minor muscle;
- latissimus dorsi muscle?

**A diagnosis of diaphragmatic hernia has been put to a patient. What are the weak spots distinguished in a diaphragm:**

- + lumbar part;
- sternocostal and lumbocostal triangles;
- tendinous center;
- sternocostal and sternolumbar triangles;
- sternolumbar and lumbocostal triangles?

**A patient has pain along one of the muscles of the trunk on the same side during the rotating movements in the vertebral column. What muscle inflammation (myositis) is observed:**

- + external oblique abdominal muscle;
- internal oblique abdominal muscle;
- rectus abdominis muscle;
- quadratus lumborum muscle;
- transverse muscle of abdomen?

**In sequence of muscular layers of the anterior abdominal wall there is made an incision for appendectomy (removing the vermiform process):**

- + transverse muscle of abdomen, external oblique abdominal muscle, internal oblique abdominal muscle;
- external oblique abdominal muscle, internal oblique abdominal muscle, transverse muscle of abdomen;
- internal oblique abdominal muscle, transverse muscle of abdomen, external oblique abdominal muscle;
- rectus abdominis muscle, external oblique abdominal muscle, internal oblique abdominal muscle;
- external oblique abdominal muscle, internal oblique abdominal muscle, rectus abdominis muscle.

**A patient has a dislocation of the shoulder joint with displacement of the head of the humerus upwards and forward. What muscle tendon can be damaged:**

- + short head of biceps brachii;
- long head of biceps brachii;
- long head of triceps brachii;
- brachialis;
- coracobrachialis?

**A victim has a gunshot wound of the anterior wall of the axillary fossa. Which muscles can be damaged thus:**

- + deltoid and coracobrachialis muscles;
- greater and lesser pectoral muscles;
- biceps brachii and brachialis muscles;
- serratus anterior and subscapularis muscles;

– teres major and minor muscles?

**A function of the posterior group of muscles of the upper arm was broken in the victim as a result of a trauma. What functional disturbance of an elbow joint will arise:**

- + pronation;
- extension;
- flexion;
- supination;
- rotation?

**A worker has received a deep cut wound of an anterior surface of the right upper arm. The muscles are injured. What muscles has the surgeon to put sutures on:**

- + lateral and medial heads of the triceps brachii muscle;
- biceps brachii and brachialis muscles;
- coracobrachialis and brachialis muscles;
- brachial and anconeus muscles;
- brachialis and brachioradialis muscles?

**A fracture of the radial bone is below the place of attachment of the pronator teres muscle in the injured patient. Where is the proximal fragment displaced:**

- + forward;
- backward;
- inward;
- outward;
- sharp displacement is possible?

**The patient cannot extend the arm in an elbow joint after an injury. What basic muscle function disturbance can it cause:**

- + musculus infraspinatus;
- musculus triceps brachii;
- musculus levator scapulae;
- musculus teres major;
- musculus subscapularis?

**As a result of an open fracture, the anterior group muscles of a forearm are damaged by the bone splinters. What functional disturbance of a radiocarpal joint will arise:**

- + extension of the hand;
- flexion of the hand;
- abduction of the hand;
- adduction of the hand;
- rotation of the hand?

**A victim has damage to the 4th synovial sheath of the hand because of the blow by a dorsum of the hand with a sharp object. Which muscles' tendons have received the trauma:**

- + extensor carpi ulnaris muscle;
- extensor digitorum muscle;
- extensor carpi radialis muscle;
- flexor digitorum profundus muscle;
- brachioradialis muscle?

**A patient, 32–years–old with affection of an ulnar nerve cannot adduct to a median line the II and IV fingers. What muscles function is broken:**

- + dorsal interosseous muscles;
- palmar interosseous muscles;
- lumbrical muscle;
- palmaris brevis muscle;
- abductor digiti minimi muscle?

**During the examination of the patient, there was detected a cut wound in a thenar region of the right hand; distal phalanx of the thumb does not flex. What muscle is damaged:**

- + adductor pollicis muscle;
- flexor pollicis longus muscle;
- flexor pollicis brevis muscle;
- abductor pollicis brevis muscle;
- opponens pollicis muscle?

**During the examination of the patient there was detected a cut wound in a thenar region of the left hand, the proximal phalanx of the thumb does not flex. What the muscle is damaged:**

- + opponens pollicis muscle;
- flexor pollicis brevis muscle;
- flexor pollicis longus muscle;
- abductor pollicis brevis muscle;
- adductor pollicis muscle?

**A crack of the posterior surface of the shaft of the humerus is diagnosed at the patient. There are signs of injury of the radial nerve canal. What formations does this canal compose:**

- + anterior surface of the humerus and m. biceps brachii;
- posterior surface of the humerus and m. triceps brachii;
- anterior surface of the humerus and m. coracobrachialis;
- anterior surface of the humerus and m. brachialis;
- posterior surface of the humerus and m. anconeus?

**How is the median cubital vein (widespread place of intravenous injections) fixed within a cubital fossa:**

- + by brachial muscle;
- by biceps brachii aponeurosis;
- by triceps brachii tendon;
- by brachioradialis muscle;
- by anconeus muscle?

**Paronychia of the little finger has been complicated by phlegmon of the hand and forearm. Purulent process was distributed to:**

- + vagina tendinis m. flexor carpi radialis;
- vagina synovialis communis mm. flexorum;
- vagina tendinis m. flexor pollicis longi;
- canalis carpalis;
- interfascial spaces?

**A patient cannot perform the abduction of a thigh because of the pain in the gluteal region. What muscle has suffered because of the injury:**

- + gluteus maximus muscle;
- gluteus minimus and medius muscles;
- piriformis;
- iliopsoas muscle;
- quadratus femoris muscle?

**A function of the thigh flexion in a hip joint was broken during the closed trauma of the abdominal cavity. What muscle has suffered because of the trauma:**

- + quadratus femoris muscle;
- iliopsoas muscle;
- rectus abdominis muscle;
- externus abdominis muscle;
- transversus abdominis muscle?

**A victim can't extend the leg after a gunshot.**

**What muscle is damaged:**

- + biceps femoris;
- quadriceps femoris;
- sartorius;
- gracilis;
- popliteus?

**What movement would be affected by trauma of medial muscles of the thigh:**

- + abduction of the thigh;
- adduction of the thigh;
- flexion of the thigh;
- extension of the thigh;
- supination of the thigh?

**Sciatic nerve lesion results in paralysis of the posterior thigh muscles. What function would be affected:**

- + flexion of the thigh;
- flexion of the leg and extension of the thigh;
- extension of the leg;
- rotation of the thigh laterally;
- rotation of the leg medially?

**A patient has the cut wound on the posterior surface of the thigh. He cannot flex his leg. What muscles are damaged:**

- + biceps femoris, adductor and gracilis;
- semitendinosus, semimembranosus and biceps femoris;
- semitendinosus adductor and gracilis;
- semitendinosus, semimembranosus and gracilis;
- biceps femoris, gracilis and adductor?

**A patient complains of impossibility of leg extension in a knee joint after the falling.**

**What muscle is injured:**

- + semimembranosus;
- quadriceps femoris;
- semitendinosus;
- biceps femoris;
- triceps surae?

**A patient complains of an acute pain above the region of the heel and impossibility to lift a body standing on tiptoe after a trauma of the lower leg. What muscle tendon is damaged:**

- + tibialis posterior muscle;

- triceps surae muscle;
- tibialis anterior muscle;
- peroneus brevis muscle;
- peroneus longus muscle?

***Because of trauma a victim had intense pain and swelling of the anterior surface of a leg. Dorsiflexion of the foot is laboure.***

***Which muscle function is disrurbed:***

- + m. flexor hallucis longus;
- m. tibialis anterior;
- m. flexor digitorum longus;
- m. peroneus brevis;
- m. peroneus longus?

***The fracture of the medial malleolus of the tibia with a damage of muscle tendons of the leg have been found out um the patient after the trauma. What muscle tendons have suffered:***

- + long and short peroneus muscles;
- posterior tibial muscle, flexor hallucis longus, flexor digitorum longus;
- anterior tibial muscle, extensor hallucis longus, extensor digitorum longus;
- triceps surae and plantaris muscles;
- extensor hallucis brevis, extensor digitorum brevis?

***A sportsman has the rupture of Achilles' tendon. Define what muscle is damaged:***

- + triceps surae muscle;
- anterior tibial;
- posterior tibial;
- peroneus longus;
- biceps femoris muscle?

***The anterior group of muscles of the leg were damaged because of fracture of the tibia.***

***What muscles' function can be broken:***

- + peroneus longus muscle;
- extensor hallucis longus muscle;
- flexor digitorum longus;
- soleus muscle;
- extensor digitorum brevis muscle?

***A female patient has a deep cut wound on the dorsum of the foot caused by the edge of a fallen pane. What muscles' tendons can be suffered because of the trauma:***

- + plantaris muscles;
- extensor digitorum longus and brevis muscle;
- peroneus longus muscle;
- peroneus brevis muscle;
- flexor digitorum longus muscle?



## MODULE 1 CLINICAL TASKS – SUPPORTING AND LOCOMOTOR APPARATUS

The student should be able to name and show:

### ***Skull as a whole***

1. Fossa temporalis
2. Fossa infratemporalis
3. Fossa pterygopalatina
4. Fossa cranii anterior
5. Fossa cranii media
6. Fossa cranii posterior
7. Clivus
8. Basis cranii externa
9. Foramen jugulare
10. Foramen lacerum
11. Palatum osseum
12. Foramen palatinum majus
13. Median palatine suture
14. Transverse palatine suture
15. Choane
16. Petrospenoidal fissure
17. Petrooccipital fissure
18. Canalis incisivus
19. Margo supraorbitalis
20. Fossa sacci lacrimalis
21. Fissura orbitalis superior
22. Fissura orbitalis inferior
23. Foramen sphenopalatinum
24. Clivus

### ***The occipital bone***

25. Sulcus sinus sigmoidei
26. Sulcus sinus sagittalis superioris
27. Protuberantia occipitalis interna
28. Crista occipitalis interna
29. Sulcus sinus transversi
30. Foramen magnum
31. Tuberculum pharyngeum
32. Sulcus sinus petrosi inferioris
33. Condylus occipitalis
34. Canalis nervi hypoglossi
35. Fossa condylaris
36. Protuberantia occipitalis externa
37. Crista occipitalis externa
38. Linea nuchalis superior
39. Linea nuchalis inferior
40. Eminentia cruciformis

### ***The sphenoid bone***

41. Sulcus prechiasmaticus
42. Tuberculum sellae
43. Fossa hypophysialis
44. Dorsum sellae
45. Ala minor
46. Canalis opticus
47. Fissura orbitalis superior
48. Ala major
49. Crista infratemporalis
50. Foramen rotundum
51. Foramen ovale
52. Foramen spinosum
53. Processus pterygoideus
54. Fossa pterygoidea
55. Pars petrosa

### ***The parietal bone***

56. Tuber parietale; Eminentia parietalis
57. The sagittal border
58. The frontal border
59. The occipital border
60. The squamosal border
61. The frontal angle
62. The sphenoidal angle
63. The occipital angle
64. The mastoid angle

### ***The frontal bone***

65. Tuber frontale; Eminentia frontalis
66. Arcus superciliaris
67. Glabella
68. Margo supraorbitalis
69. Incisura supraorbitalis / Foramen supraorbitale
70. Processus zygomaticus
71. Foramen caecum
72. Facies orbitalis

### ***The temporal bone***

79. Pars petrosa
80. The squamous part
81. The tympanic part
82. Processus mastoideus
83. Incisura mastoidea

84. Foramen mastoideum
85. Canalis nervi facialis
86. Canaliculus chordae tympani
87. Apertura externa canalis carotici
88. Apertura interna canalis carotici
89. Canalis musculotubarius
90. Facies anterior partis petrosae
91. Tegmen tympani
92. Eminentia arcuata
93. Hiatus canalis nervi petrosi majoris
94. Sulcus nervi petrosi majoris
95. Hiatus canalis nervi petrosi minoris
96. Sulcus nervi petrosi minoris
97. Impressio trigeminalis
98. Sulcus sinus petrosi superioris
99. Porus acusticus internus
100. Meatus acusticus internus
101. Sulcus sinus petrosi inferioris
102. Facies inferior partis petrosae
103. Canaliculus mastoideus
104. Processus styloideus
105. Foramen stylomastoideum
106. Canaliculus tympanicus
107. Fossula petrosa
108. Porus acusticus externus
109. Meatus acusticus externus
110. Processus zygomaticus
111. Fossa mandibularis
112. Fissura petrosquamosa
113. Fissura tympanomastoidea

#### ***The ethmoid bone***

114. Lamina cribrosa
115. Crista galli
116. Labyrinthus ethmoidalis
117. Lamina orbitalis
118. Concha nasalis superior
119. Concha nasalis media
120. The perpendicular plate

#### ***Bones of the visceral cranium***

121. Os lacrimale
122. Os nasale
123. Vomer
124. Os palatinum
125. Os zygomaticum
126. Foramen zygomaticoorbitale
127. Foramen zygomaticofaciale
128. Foramen zygomaticotemporale

#### ***The maxilla***

129. Canalis infraorbitalis
130. Sulcus infraorbitalis
131. Margo infraorbitalis
132. Foramen infraorbitale
133. Fossa canina
134. Facies infratemporalis
135. Tuber maxillae; Eminentia maxillae
136. Hiatus maxillaris
137. Processus zygomaticus
138. Processus palatinus
139. Processus alveolaris
140. Arcus alveolaris
141. Alveoli dentales
142. Septa interalveolaria
143. Juga alveolaria

#### ***The mandible***

144. Protuberantia mentalis
145. Tuberculum mentale
146. Foramen mentale
147. Fossa digastrica
148. Linea mylohyoidea
149. Fovea sublingualis
150. Fovea submandibularis
151. Ramus mandibulae
152. Angulus mandibulae
153. Tuberositas masseterica
154. Tuberositas pterygoidea
155. Foramen mandibulae
156. Canalis mandibulae
157. Processus coronoideus
158. Processus condylaris
159. Caput mandibulae; Condylus mandibulae
160. Collum mandibulae
161. Fovea pterygoidea

#### ***Components of the skeleton***

162. The vertebral body.
163. The vertebral arch.
164. The vertebral foramen
165. The intervertebral foramen.
166. The anterior arch of atlas.
167. The posterior arch of atlas.
168. The lateral mass of atlas.
169. The superior articular process of vertebra.

170. The inferior articular process of vertebra.
171. The transverse process of vertebra.
172. The dens of the axis.
173. The transverse foramen of vertebra.
174. The spinous process.
175. The costal facet of transverse process.
176. The superior vertebral notch
177. The inferior vertebral notch
178. The thoracic vertebrae.
179. The cervical vertebrae.
180. The lumbar vertebrae.
181. The base of the sacrum.
182. The apex of the sacrum.
183. The pelvic surface of the sacrum.
184. The dorsal surface of the sacrum.
185. The promontory
186. The lateral part of sacrum
187. The transverse line of sacrum
188. The anterior sacral foramen
189. The posterior sacral foramen
190. The median sacral crest
191. The intermediate sacral crest
192. The lateral sacral crest
193. The sacral hiatus
194. The sacral cornua
195. The sacral tuberosity
196. The auricular surface of sacrum
197. The sacral canal
198. The coccyx
199. The first rib
200. The scalene tubercle of first rib
201. The head of the rib.
202. The neck of the rib.
203. The costal tubercle.
204. The costal angle.
205. The costal groove.
206. The manubrium of the sternum.
207. The jugular notch.
208. The sternal angle.
209. The body of sternum.
210. The xiphoid process.
211. The clavicular notch
212. The costal notches
213. The spine of scapula.
214. The coracoid process.
215. The acromion.
216. The glenoid cavity of the scapula.
217. The supraspinous fossa
218. The infraspinous fossa
219. The suprascapular notch
220. The neck of scapula
221. The subscapular fossa
222. The shaft of clavicle
223. The sternal end of clavicle
224. The acromial end of clavicle
225. The sternal end of clavicle
226. The trapezoid line of clavicle
227. The humerus (right, left).
228. The head of humerus.
229. The anatomical neck of humerus.
230. The surgical neck.
231. The greater tubercle of humerus.
232. The lesser tubercle of humerus
233. The crest of greater tubercle
234. The crest of lesser tubercle
235. The intertubercular groove
236. The capitulum of humerus.
237. The medial epicondyle of humerus.
238. The lateral epicondyle of humerus.
239. The olecranon fossa
240. The coronoid fossa
241. The radial fossa
242. The groove for ulnar nerve
243. The trochlea of humerus.
244. The ulna (right, left).
245. The shaft of ulna.
246. The head of ulna.
247. The coronoid process of ulna.
248. The olecranon.
249. The trochlear notch.
250. The styloid process of ulna.
251. The radial notch
252. The articular circumference of ulna
253. The interosseous border of ulna
254. The radius (right, left).
255. The head of radius.
256. The neck of radius.
257. The shaft of radius.
258. The radial styloid process.
259. The articular facet of radius
260. The articular circumference of radius
261. The interosseous border of radius
262. The carpal articular surface of radius
263. The ulnar notch
264. The carpal bone.
265. The metacarpal bones.
266. The proximal phalanx of fingers.

267. The middle phalanx of fingers  
 268. The distal phalanx of fingers  
 269. The acetabulum  
 270. Fossa acetabuli  
 271. Incisura acetabuli  
 272. Facies lunata  
 273. The ala of ilium.  
 274. The body of ilium.  
 275. The anterior inferior iliac spine.  
 276. The posterior superior iliac spine.  
 277. The posterior inferior iliac spine  
 278. The iliac crest.  
 279. The anterior superior iliac spine.  
 280. The iliac fossa  
 281. The arcuate line  
 282. The auricular surface of iliac bone  
 283. The gluteal surface of iliac bone  
 284. The obturator foramen.  
 285. The body of pubis  
 286. The superior pubic ramus  
 287. Facies symphyialis  
 288. Ramus superior ossis pubis  
 289. Eminentia iliopubica  
 290. Pecten ossis pubis  
 291. Sulcus obturatorius  
 292. Ramus inferior ossis pubis  
 293. The ishium.  
 294. The body of ishium.  
 295. The ramus of ishium.  
 296. The greater sciatic notch.  
 297. The lesser sciatic notch.  
 298. The ischial tuberosity  
 299. The ischial spine  
 300. The neck of femur.  
 301. The greater trochanter.  
 302. Caput femoris  
 303. Fovea capitis femoris  
 304. Fossa trochanterica  
 305. Trochanter minor  
 306. Crista intertrochanterica  
 307. Linea aspera  
 308. Facies poplitea  
 309. Condylus medialis  
 310. Condylus lateralis  
 311. Facies patellaris  
 312. Fossa intercondylaris  
 313. Patella  
 314. Tibia  
 315. Condylus medialis  
 316. Condylus lateralis  
 317. Area intercondylaris anterior  
 318. Area intercondylaris posterior  
 319. Eminentia intercondylaris  
 320. Tuberositas tibiae  
 321. Linea musculi solei  
 322. Malleolus medialis  
 323. Incisura fibularis  
 324. Inferior articular surface  
 325. Caput fibulae  
 326. Apex capitis fibulae  
 327. Malleolus lateralis  
 328. Fossa malleoli lateralis  
 329. Ossa tarsi; Ossa tarsalia  
 330. Talus  
 331. Head of talus  
 332. Calcaneus  
 333. Tuber calcanei  
 334. Os naviculare  
 335. Os cuneiforme mediale  
 336. Os cuneiforme intermedium  
 337. Os cuneiforme laterale  
 338. Os cuboideum  
 339. Ossa metatarsi; Ossa metatarsalia [I–V]  
 340. Proximal, middle, distal phalanx of toes
- Articular system**
341. Sutura coronalis  
 342. Sutura sagittalis  
 343. Sutura lambdoidea  
 344. Sutura squamosa  
 345. Synchondrosis sphenoccipitalis  
 346. Synchondrosis sphenopetrosa  
 347. Synchondrosis petrooccipitalis  
 348. Articulatio temporomandibularis  
 349. Lig. longitudinale anterius  
 350. Lig. longitudinale posterius  
 351. Discus intervertebralis  
 352. The atlantoaxial joint  
 353. Articulationes sternocostales  
 354. The costovertebral joints  
 355. Lig. coracoacromiale  
 356. Lig. transversum scapulae superius  
 357. Membrana interossea antebrachii  
 358. The shoulder joint  
 359. Articulatio cubiti  
 360. Lig. collaterale ulnare  
 361. Lig. collaterale radiale  
 362. Lig. anulare radii

363. Articulatio radiocarpalis  
364. Lig. collaterale carpi ulnare  
365. Lig. collaterale carpi radiale  
366. Articulatio mediocarpalis  
367. Canalis carpi  
368. Articulationes interphalangeae manus  
369. Linea terminalis  
370. Diameter transversa of pelvic inlet  
371. Diameter transversa of pelvic outlet  
372. Diameter obliqua  
373. Conjugata anatomica  
374. Conjugata vera  
375. Conjugata recta  
376. Distantia interspinosa  
377. Distantia intercrystalis  
378. Distantia intertrochantrica  
379. Membrana obturatoria  
380. Canalis obturatorius  
381. Symphysis pubica  
382. Articulatio sacroiliaca  
383. Lig. sacrotuberale  
384. Lig. sacrospinale  
385. Foramen ischiadicum majus  
386. Foramen ischiadicum minus  
387. Membrana interossea cruris  
388. The medial meniscus of knee j.  
389. The laterall meniscus of knee j.  
390. Lig. cruciatum anterius  
391. Lig. cruciatum posterius  
392. Lig. collaterale fibulare  
393. Lig. collaterale tibiale  
394. Lig. patellae  
395. Articulatio talocruralis  
396. Articulatio tarsi transversa Chopart`s j.)  
397. Lig. bifurcatum  
398. Lig. plantare longum  
399. The tarsometatarsal j. (Lisfranc`s j.)  
400. The medial cuneometatarsal lig.  
401. Articulationes metatarsophalangeae  
402. Articulationes interphalangea pedis
- Muscular system**
403. M. orbicularis oculi  
404. M. orbicularis oris  
405. M. depressor anguli oris  
406. M. risorius  
407. M. zygomaticus major  
408. M. zygomaticus minor  
409. M. levator labii superioris  
410. M. levator labii superioris  
411. M. depressor labii inferioris  
412. M. levator anguli oris  
413. M. buccinator  
414. M. mentalis  
415. M. masseter  
416. M. temporalis  
417. M. pterygoideus lateralis  
418. M. pterygoideus medialis  
419. Platysma  
420. M. scalenus anterior  
421. M. scalenus medius  
422. M. scalenus posterior  
423. M. sternocleidomastoideus  
424. M. digastricus  
425. M. stylohyoideus  
426. M. mylohyoideus  
427. M. sternohyoideus  
428. M. omohyoideus  
429. M. ternothyreoideus  
430. M. thyrohyoideus  
431. M. trapezius  
432. M. latissimus dorsi  
433. M. rhomboideus major  
434. M. rhomboideus minor  
435. M. levator scapulae  
436. M. serratus posterior inferior  
437. M. serratus posterior superior  
438. Musculus erector spinae  
439. M. pectoralis major  
440. M. pectoralis minor  
441. M. serratus anterior  
442. Mm. intercostales externi  
443. Mm. intercostales interni  
444. M. transversus thoracis  
445. Pars lumbalis diaphragmatis  
446. Pars costalis diaphragmatis  
447. Pars sternalis diaphragmatis  
448. Hiatus aorticus  
449. Hiatus oesophageus  
450. Centrum tendineum  
451. Foramen venae cavae  
452. Trigonum sternocostale  
453. Trigonum lumbocostale  
454. M. rectus abdominis  
455. Vagina muscoli recti abdominis  
456. M. obliquus externus abdominis  
457. Lig inguinale, Arcus inguinalis  
458. Anulus inguinalis superficialis  
459. M. obliquus internus abdominis  
460. M. transversus abdominis

461. Anulus inguinalis profundus  
462. Linea alba  
463. Anulus umbilicalis  
464. Linea semilunaris  
465. Canalis inguinalis  
466. M. quadratus lumborum  
467. Arcus iliopectineus  
468. M. deltoideus  
469. M. supraspinatus  
470. M. infraspinatus  
471. M. teres minor  
472. M. teres major  
473. M. subscapularis  
474. M. biceps brachii  
475. Caput longum  
476. Caput breve  
477. M. coracobrachialis  
478. M. brachialis  
479. M. triceps brachii  
480. M. pronator teres  
481. M. flexor carpi radialis  
482. M. palmaris longus  
483. M. flexor carpi ulnaris  
484. M. flexor digitorum superficialis  
485. M. flexor digitorum profundus  
486. M. flexor pollicis longus  
487. M. pronator quadratus  
488. M. brachioradialis  
489. M. extensor carpi radialis longus  
490. M. extensor carpi radialis brevis  
491. M. extensor digitorum  
492. M. extensor digiti minimi  
493. M. extensor carpi ulnaris  
494. M. supinator  
495. M. abductor pollicis longus  
496. M. extensor pollicis longus  
497. M. extensor indicis  
498. M. palmaris brevis  
499. Mm. lumbricales  
500. Aponeurosis palmaris  
501. Retinaculum musculorum flexorum  
502. The axillary cavity  
503. The triangular opening.  
504. The quadrangular opening.  
505. The radial groove of forearm.  
506. The ulnar groove of forearm.  
507. The median groove of forearm.  
508. The cubital fossa  
509. The common flexor sheath  
510. M. iliopsoas  
511. M. iliacus  
512. M. psoas major  
513. M. gluteus maximus  
514. M. gluteus medius  
515. M. gluteus minimus  
516. M. tensor fasciae latae  
517. M. piriformis  
518. M. obturatorius internus  
519. M. quadratus femoris  
520. M. sartorius  
521. M. rectus femoris  
522. M. vastus lateralis  
523. M. vastus intermedius  
524. M. vastus medialis  
525. M. pectineus  
526. M. adductor longus  
527. M. adductor brevis  
528. M. adductor magnus  
529. M. gracilis  
530. M. obturatorius externus  
531. M. biceps femoris  
532. M. semitendinosus  
533. M. semimembranosus  
534. M. tibialis anterior  
535. M. extensor digitorum longus  
536. M. extensor hallucis longus  
537. M. fibularis longus; M. peroneus longus  
538. M. fibularis brevis; M. peroneus brevis .  
539. M. triceps surae  
601. M. gastrocnemius  
602. M. soleus  
603. M. plantaris  
604. M. popliteus  
605. M. tibialis posterior  
606. M. flexor digitorum longus  
607. M. flexor hallucis longus  
608. M. quadratus plantae;  
620. Tractus iliotibialis  
621. Canalis adductorius  
622. Lacuna musculorum  
623. Lacuna vasorum  
624. Trigonum femorale  
625. Anulus femoralis  
626. Hiatus saphenus  
627. The suprapiriform foramen.  
628. The superior musculo-peroneal canal.  
629. The inferior musculo-peroneal canal.  
630. The cruro-popliteal canal.  
631. The lateral plantar groove.  
632. The medial plantar groove.

## REFERENCES

1. Gilliland K., Kernick E. Musculoskeletal tissues and anatomy. Clinical Foundations of Musculoskeletal Medicine. 2021. P. 11–21.
2. Halliday N. L., Chung H. M., Chung K. W. Gross anatomy. Philadelphia : Wolters Kluwer Health, 2020.
3. Fundamentals of Anatomy & Physiology / F. Martini et al. Harlow : Pearson, 2021.
4. McKinley M. P., O'Loughlin V. D., Pennefather-O'Brien E. E. Human anatomy. New York : McGraw-Hill Education, 2021.
5. Mitchell T. The musculoskeletal system. Green Forest : Master Books, 2015.
6. Schünke M., Schulte E., Schumacher U. Thieme Atlas of anatomy. Thieme, 2021.
7. Tortora G. J. Principles of anatomy and physiology. Milton Qld : John Wiley & Sons, Ltd, 2022.
8. Supporting and Locomotor Apparatus : study guide / V. I. Bumeister, L. G. Sulim, O. O. Prykhodko et al. Sumy : Sumy State University, 2015. 134 p.
9. Muscular system – muscles of the human body. Innerbody [cited 2022 Feb. 3]. URL: <https://www.innerbody.com/image/musfov.html>.
10. Sendic G. Musculoskeletal system. Kenhub. Kenhub, 2021 [cited 2022 Feb. 3]. URL: <https://www.kenhub.com/en/library/anatomy/the-musculoskeletal-system>.

Навчальне видання

**Бумейстер** Валентина Іванівна,  
**Ярошенко** Ольга Сергіївна,  
**Приходько** Ольга Олексіївна та ін.

# ОПОРНО-РУХОВИЙ АПАРАТ

Навчальний посібник

(Англійською мовою)

За редакцією В. І. Бумейстер

Художнє оформлення обкладинки О. О. Приходько  
Редактор І. А. Іванов  
Комп'ютерне верстання А. В. Удальцева

Формат 60x84/8. Ум. друк. арк. 24,18. Обл.- вид. арк. 26,88. Тираж 300 пр. Зам. №

Видавець і виготовлювач  
Сумський державний університет,  
вул. Римського-Корсакова, 2, м. Суми, 40007  
Свідоцтво суб'єкта видавничої справи ДК № 3062 від 17.12.2007.

---

Навчальний посібник призначений для студентів медичних закладів вищої освіти IV рівня акредитації, які вивчають анатомію людини англійською мовою.