



Case report

Case report: Metastasis of Merkel cell carcinoma in the small intestine

Ruslana Chyzhma, Artem Piddubnyi, Anatolii Romaniuk, Roman Moskalenko*

Sumy State University, Sumy 40000, Ukraine

ARTICLE INFO

Keywords:

Merkel cell carcinoma
Metastasis
Small intestine

ABSTRACT

Merkel cell carcinoma is a rare primary neuroendocrine malignant neoplasm of the skin, which recurs in about 40 % of cases. The main factors are Merkel cell polyomavirus (MCPyV) and mutations caused by ultraviolet radiation [Paulson, 2018]. In this study, we report a case of Merkel cell carcinoma with metastasis to the small intestine. In a 52-year-old woman, a subcutaneous formation of a nodule up to 2.0 cm in diameter was detected during the examination. This neoplasm was removed and sent for histological analysis. Dot-like expression of CK pan, CK 20, chromogranin A, and Synaptophysin was observed in tumor cells, and Ki-67 in 40 % of tumor cells. There is no reaction in tumor cells to CD 45, CK 7, TTF 1, and S100. The morphological picture corresponded to Merkel cell carcinoma. A year later, the patient underwent surgery for intestinal obstruction. The pathohistological changes and immunophenotype of the small bowel tumor were consistent with Merkel cell carcinoma metastasis.

1. Introduction

Merkel cell carcinoma (MCC) is a rare primary neuroendocrine malignant neoplasm of the skin which recurs in 40 % of cases. The main causative factors of this neoplasm are Merkel cell polyomavirus and UV-driven mutations [1]. At the time of diagnosis, MCC usually has local spread or distant metastatic dissemination. This disease has an adverse prognosis which depends on the tumor stage. At the same time, the five-year survival rate is 51 % and 14 % for local and metastatic neoplasms, respectively [2]. The mortality rate of MCC is 46 %, which is almost four-fold higher than for invasive melanoma but with 100 fold lower incidence [3]. The risk factors for MCC are age, immunodeficiency and tumors of the skin or blood system [4].

MCC has a progressive and often asymptomatic course. It manifests as a painless red or purple rounded-shaped nodule with dense consistency with a predominant localization in the head and neck region [5]. The overlying skin is smooth with rare telangiectases. It can be presented as a subcutaneous nodule with no skin changes [4,5]. However, extracutaneous localizations, such as salivary glands and the nasal cavity, have been reported [5,6]. MCC can metastasize to the gastrointestinal tract (stomach, pancreas), heart, pleura, testis, prostate and bladder [6,7]. MCC has predominant lymphogenic dissemination.

In this study, we report a case of MCC with metastases to the small intestine.

2. Case report

A 52-year-old female patient was admitted to the surgical department with complaints of pain and swelling in the area of the left gluteal region, hyperthermia up to 37.9 °C and weakness. During the examination, the subcutaneous nodule with a diameter of up to 2.0 cm was detected. Regional lymph nodes were not enlarged. Computed tomography of the pelvis revealed a vascularized tumor of the subcutaneous fat tissue of the left gluteal region. The patient was diagnosed with a primary mesenchymal tumor (sarcoma) with metastases. After the surgery, the tumor was sent for histological examination.

During the grossing, the tumor had a shape of pink rounded formation with dense consistency. The tumor was tightly connected with an overlying skin. The skin fragment had a size 3.0 × 2.5 × 0.5 cm and had single point inclusions of dirty gray color on the surface.

Microscopically, the tumor had a trabecular structure and was represented by medium-sized monomorphic cells. The nuclei were round-shaped, large, with a scanty rim of cytoplasm and fine-grained chromatin, numerous mitoses (up to 3–4 in the field of view).

To estimate the histogenesis of the tumor, immunohistochemistry (IHC) was performed with the following antibodies: chromogranin A (Clone PHE5, ThermoFisher Scientific, USA), CK pan (Clone C11, ThermoFisher Scientific, USA), CK 7 (Clone C46, ThermoFisher Scientific, USA), CK 20 (Clone RM283, ThermoFisher Scientific, USA), Ki-67 (Clone SolA15, ThermoFisher Scientific, USA), CD 45 (Clone 30-F11,

* Corresponding author.

E-mail address: r.moskalenko@med.sumdu.edu.ua (R. Moskalenko).

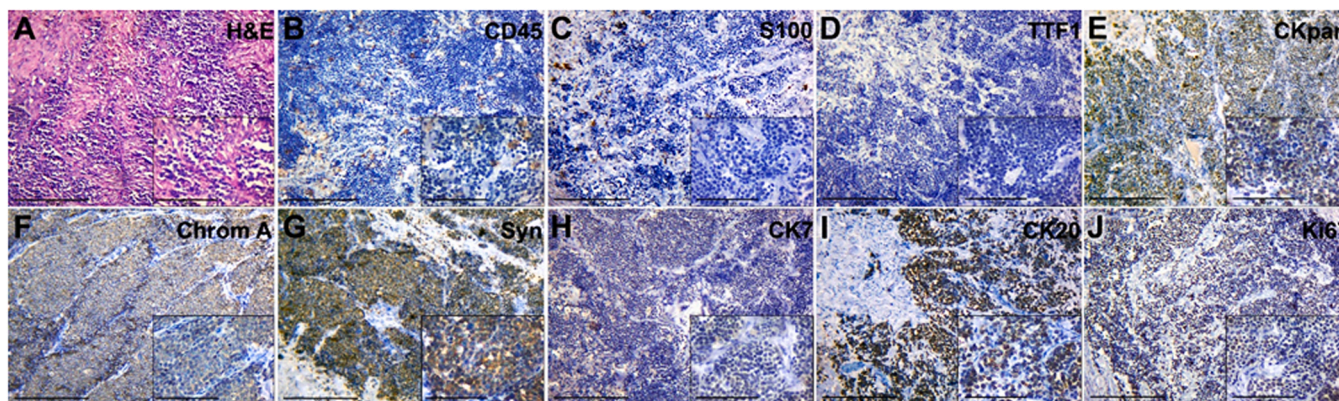


Fig. 1. Merkel cell carcinoma of the gluteal region (primary tumor). (A) –hematoxylin–eosin staining. IHC detection of (B) – CD45; (C) – S100; (D) – TTF1; (E) – CK pan; (F) – Chromogranin A; (G) – Synaptophysin; (H) – CK7; (I) – CK 20; (J) – Ki-67.

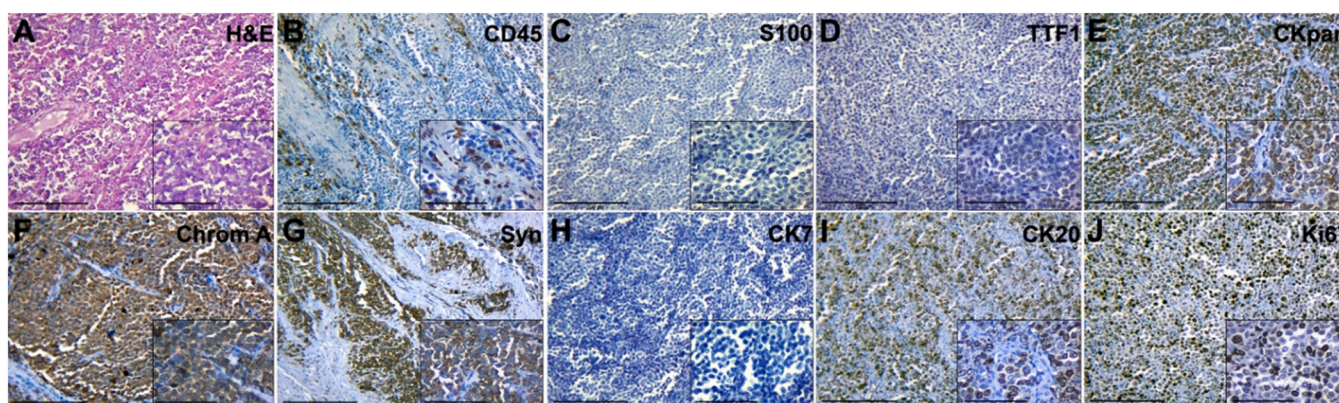


Fig. 2. The tumor of the small intestine (metastasis of MCC to small intestine). (A) – hematoxylin–eosin staining. IHC detection of (B) – CD45; (C) – S100; (D) – TTF1; (E) – CK pan; (F) – Chromogranin A; (G) – Synaptophysin; (H) – CK7; (I) – CK 20; (J) – Ki-67.

Master Diagnostica, Spain), S100 (Clone 4C4.9, ThermoFisher Scientific, USA), TTF1 (Clone SPT24, Master Diagnostica, Spain), Synaptophysin (Clone SP11, Master Diagnostica, Spain).

CK pan, CK 20, chromogranin A, and Synaptophysin had a dot-like IHC expression in tumor cells. About 40 % of tumor cells had positive Ki-67 immunostaining. At the same time, neoplastic cells were negative for CD 45, CK 7, TTF1 and S100 expression (Fig. 1).

The morphological pattern and immunophenotype of tumor corresponded to Merkel cell carcinoma, ICD-O code 8247/3.

The patient was administrated chemotherapy and radiation therapy after the diagnosis.

One year later, the patient was admitted to the hospital with complaints of indigestion and vomiting (bile, leftover food). After conservative treatment, relief was not observed. Computed tomography confirmed a diagnosis – a tumor of the small intestine complicated by intestinal obstruction. After the surgery, the intestinal tissue with a tumor was sent for histological examination.

On the grossing, the small intestine was expanded throughout, with a thinned wall and preserved folds. In the center of the intestinal fragment, a narrowing site of 2.0 cm length was found with a thickened intestinal wall up to 1.0 cm and narrowed lumen. The edges of the resection had no signs of tumor growth.

The histogenesis of the tumor was confirmed by IHC. Tumor tissue was negative for CD 45 which excludes the diagnosis of lymphatic malignant tumor. Negative immunostaining for CK 7, TTF1, and S100 in tumor cells also excludes from the differential diagnosis the metastases of lung cancer and melanoma, respectively.

On the other hand, the tumor was positive for markers of

neuroendocrine tumors, such as Chromogranin A and Synaptophysin, and had a positive membrane dot-like reaction to CK 20. Ki-67 was expressed in 60–70 % of tumor cells (Fig. 2). All these results and clinical data pointed out for the recurrence of MCC in this patient.

Antibody	Original MCC	MCC metastasis
CK 20	+++	+++
CK pan	++	+++
Synaptophysin	+	++
Chromogranin A A	+	++
Ki-67	++	+++
CD 45	-	-
CK 7	±	-
TTF1	-	-
S100	-	-

3. Discussion

MCC is a fairly rare aggressive tumor, with an insidious course and low 5-year survival rates. There is a trend for an increase of MCC incidence in recent years. In the US, the number of reported cases increased by 95 % from 2000 to 2013. It should be noted that the increase in incidence rates for melanoma was 57 %, and all other types of "solid" cancer – 15 % [8]. In 2013, the incidence rate of MCC was 0.7 per 100, 000 population, corresponding to 2488 reported cases. In 2020, 2835 cases were registered. It is predicted that the number of cases will increase to 3284 in 2025 [9].

Despite the classic clinical picture of MCC as a rapidly growing mass localized on the UV-exposed skin, the pathological features of the tumor

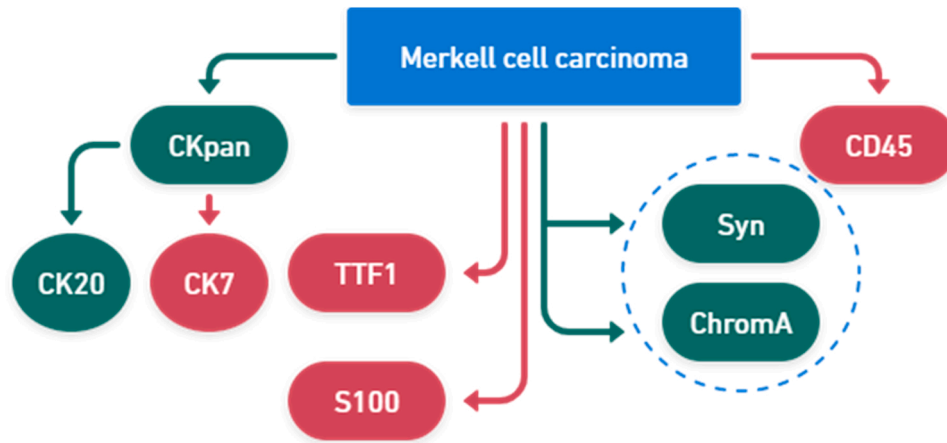


Fig. 3. The panel of markers used for MCC diagnosis. Green indicates a positive reaction, red indicates a negative reaction.

are the most important for the correct diagnosis.

A rather interesting fact is the propensity of MCC to metastasize. It is known that this tumor develops predominantly lymphogenic metastases. About 50–70 % of patients have micrometastases in the lymph nodes [10]. At the same time, 33–70 % of patients have distant metastases. The so-called "anonymity" of MCC metastasis should be noted, namely the low clarity of the primary lesion [11]. It has been established that the first sites of metastasis in MCC are distant lymph nodes and organs of the abdomen [12].

We described a unique case of metastatic MCC with a spread to the small intestine which has not been reported before.

In this case, the metastatic formation was detected one year after the diagnosis of the primary focus of MCC in the left gluteal region. We detected the expression of CK pan, CK 20, Chromogranin A, Synaptophysin, and Ki-67 in primary and metastatic neoplasms. CK 20 expression had a specific cytoplasmic dot-like staining pattern in tumor cells. The expression of Ki-67 in primary and metastatic tumors increased from 40 % to 60–70 %, respectively. This, in turn, indicates a significantly higher proliferative activity of small intestine metastasis tumor cells.

The lack of pathognomonic microscopic characteristics of the MCC provides obstacles to histological verification of the tumor, which emphasizes the need for IHC. It also made it possible to differentiate MCC from metastases of small-cell lung cancer, B-cell lymphoma, and melanoma (Fig. 3).

Declaration of Competing Interest

The authors declare that they have no known competing financial interests or personal relationships that could have appeared to influence the work reported in this paper.

Acknowledgements

This research has been performed with the financial support of grants of the Ministry of Education and Science of Ukraine #RN 1740-2023.

References

[1] K.G. Paulson, S. Bhatia, Advances in immunotherapy for metastatic merkel cell carcinoma: a clinician's guide, *J. Natl. Compr. Canc Netw.* 16 (6) (2018) 782–790, <https://doi.org/10.6004/jnccn.2018.7049>.

[2] T.L. Tello, K. Cogshall, S.S. Yom, S.S. Yu, Merkel cell carcinoma: an update and review: current and future therapy, *J. Am. Acad. Dermatol.* 78 (3) (2018) 445–454, <https://doi.org/10.1016/j.jaad.2017.12.004>. Epub 2017 Dec 9.

[3] S. Guadagni, A.R. Farina, L.A. Cappabianca, M. Sebastiano, R. Maccaroni, V. Zelli, M. Clementi, A. Chiominto, G. Bruera, E. Ricevuto, G. Fiorentini, D. Sarti, A. R. Mackay, Multidisciplinary Treatment, including locoregional chemotherapy, for Merkel-polyomavirus-positive merkel cell carcinomas: perspectives for patients exhibiting oncogenic alternative Δ exon 6-7 TrkAIII splicing of neurotrophin receptor tropomyosin-related kinase a, *Int. J. Mol. Sci.* 21 (21) (2020) 8222, <https://doi.org/10.3390/ijms21218222>. PMID: 33153070; PMCID: PMC7662965.

[4] M. Brady, A.M. Spiker, *Merkel Cell Carcinoma Of The Skin*. [Updated 2022 Jul 19]. StatPearls [Internet], StatPearls Publishing, Treasure Island (FL), 2022 (Jan–Available from), (<https://www.ncbi.nlm.nih.gov/books/NBK482329/>).

[5] J.C. Becker, A. Stang, J.A. DeCaprio, L. Cerroni, C. Lebbé, M. Veness, P. Nghiem, Merkel cell carcinoma, *Nat. Rev. Dis. Prim.* 3 (2017) 17077, <https://doi.org/10.1038/nrdp.2017.77>. PMID: 29072302; PMCID: PMC6054450.

[6] D.J. Lewis, J.F. Sobanko, J.R. Etkorn, T.M. Shin, C.N. Giordano, S.L. McMurray, J. L. Walker, J. Zhang, C.J. Miller, H.W. Higgins 2nd, Merkel cell carcinoma, *Dermatol. Clin.* 41 (1) (2023) 101–115, <https://doi.org/10.1016/j.det.2022.07.015>. Epub 2022 Oct 28.

[7] F. Saqlain, S.Z. Shalhout, K.S. Emerick, T.G. Neilan, T. Sharova, D.M. Miller, Metastatic Merkel cell carcinoma masquerading as multiple immune-related adverse events, *Case Rep. Dermatol. Med* 2020 (2020) 8890845, <https://doi.org/10.1155/2020/8890845>. PMID: 33062347; PMCID: PMC7545440.

[8] M. Scampa, R. Merat, E. Tzika, D.F. Kalbermatten, C.M. Oranges, Survival outcomes and epidemiology of Merkel cell carcinoma of the lower limb and hip: a surveillance, *Epidemiol., End. Results Anal.* 2000-2018. *JAAD Int* 7 (2022) 13–21, <https://doi.org/10.1016/j.jdin.2021.12.010>. PMID: 35243404; PMCID: PMC8873923.

[9] K.G. Paulson, S.Y. Park, N.A. Vandeven, K. Lachance, H. Thomas, A.G. Chapuis, K. L. Harms, J.A. Thompson, S. Bhatia, A. Stang, P. Nghiem, Merkel cell carcinoma: current US incidence and projected increases based on changing demographics, *J. Am. Acad. Dermatol.* 78 (3) (2018) 457–463, <https://doi.org/10.1016/j.jaad.2017.10.028>. Epub 2017 Nov 2. PMID: 29102486; PMCID: PMC5815902.

[10] M. Kouzmina, V. Koljonen, J. Leikola, T. Böhling, E. Lantto, Frequency and locations of systemic metastases in Merkel cell carcinoma by imaging, *Acta Radio. Open* 6 (3) (2017), <https://doi.org/10.1177/2058460117700449>. PMID: 28540062; PMCID: PMC5433554.

[11] C.W. Lewis, J. Qazi, D.S. Hippe, K. Lachance, H. Thomas, M.M. Cook, I. Juhlin, N. Singh, Z. Thuesmun, S.R. Takagishi, A. McEvoy, C. Doolittle-Amieva, S. Bhatia, K.G. Paulson, R.B. O'Malley, C.L. Wang, P. Nghiem, Patterns of distant metastases in 215 Merkel cell carcinoma patients: implications for prognosis and surveillance, *Cancer Med* 9 (4) (2020) 1374–1382, <https://doi.org/10.1002/cam4.2781>. Epub 2019 Dec 27. PMID: 31883234; PMCID: PMC7013053.

[12] Y. Song, F.S. Azari, R. Tang, A.B. Shannon, J.T. Miura, D.L. Fraker, G.C. Karakousis, Patterns of metastasis in merkel cell carcinoma, *Ann. Surg. Oncol.* 28 (1) (2021) 519–529, <https://doi.org/10.1245/s10434-020-08587-3>. Epub 2020 May 13. PMID: 32405979; PMCID: PMC7220648.