

Clinical case

DOI: 10.26565/2313-6693-2023-46-06

УДК: 616.314.2-007-079.2-085

Lychko V. ^{A, C, D, F}, **Lychko S.** ^{B, C, D}, **Zhyvotovskiy I.** ^{B, C, E}, **Burtyka M.** ^B

v.lychko@med.sumdu.edu.ua

MASTICATORY MYOFASCIAL PAIN SYNDROME PROVOKED BY SARS-COV-2 INFECTION IN A PATIENT WITH OROFACIAL PATHOLOGY (CLINICAL CASE)

A – research concept and design; B – collection and/or assembly of data; C – data analysis and interpretation; D – writing the article; E – critical revision of the article; F – final approval of the article

Abstract. Myofascial pain syndrome (MFPS) is a chronic pain condition characterised by the appearance of myofascial trigger points (MTP) in muscles. The condition can be caused by various factors and is diagnosed through clinical examination and palpation of MTPs. Recent studies have shown that infections like SARS-CoV-2 can cause MFPS, along with other symptoms. Dentists often encounter the problem of MFPS in patients with temporomandibular joint dysfunction, but it can also develop in patients with a normally functioning joint. Symptoms include pain, sensitivity, and abnormalities in mandible mobility. In this article, the case of MFPS in a person with orofacial pathology after SARS-CoV-2 diagnosis is presented.

Materials and methods of research. Describes a person who has the instability of the bite caused by the absence, destruction and disposition of the chewing teeth led to disorders of the chewing muscles. The patient was found to have appearing MFPS symptoms after COVID-19. The systematic online search of articles utilising the search terms «Coronavirus, SARS-COV-2 and Myofascial pain syndrome», published between January 2020 and October 2023, was performed.

Results. The patient was diagnosed with SARS-CoV-2 in October 2021 and was hospitalised for 10 days. After discharge, she went to the dentist with complaints of headache and stiffness in the area of masticatory muscles, absence and destruction of lateral teeth, difficulty in chewing food, mobility and displacement of individual teeth, periodic bleeding gums, as well as aesthetic disorders. During the objective examination, secondary partial adentia was revealed, which led to instability of the bite, defects of the hard tissues of the chewing teeth, pathological wear of the frontal group, and traumatic occlusion phenomena. During palpation, trigger points were found in the area of the masticatory and temporal muscles. The patient underwent a series of ten trigger point injections (dry needling) in her chewing muscles, with about 30 % immediate relief.

Conclusion. MFPS can be caused by various factors, including infections like SARS-CoV-2. The diagnosis is based on clinical examination and palpation of MTPs, and treatment may include trigger point injections, physical therapy, and non-invasive therapy methods. In the presented case, the patient had partial adentia, leading to instability of the bite and MFPS symptoms after SARS-CoV-2 diagnosis. Prompt diagnosis and management of MFPS are necessary to improve the patient's quality of life.

KEY WORDS: *temporomandibular dysfunction, myofascial pain syndrome, bruxism, bite defect, trigger point*

INFORMATION ABOUT AUTHORS

Volodymyr Lychko, MD, Associate Professor, Department of Neurosurgery and Neurology, Academic and Research Medical Institute of Sumy State University, 1, Sanatorna st., Sumy, Ukraine, 40018; e-mail: v.lychko@med.sumdu.edu.ua, ORCID ID: <https://orcid.org/0000-0001-5518-5274>

Svitlana Lychko, Trainee teacher, Department of Dentistry, Academic and Research Medical Institute of Sumy State University, 1, Sanatorna st., Sumy, Ukraine, 40018; e-mail: s.lychko@med.sumdu.edu.ua, ORCID ID: <https://orcid.org/0000-0001-6906-1643>

Igor Zhyvotovskiy, MD, PhD, Department of Dentistry, Academic and Research Medical Institute of Sumy State University, 1, Sanatorna st., Sumy, Ukraine, 40018; e-mail: i.zhyvotovskiy@med.sumdu.edu.ua, ORCID ID: <https://orcid.org/0000-0002-1899-5558>

Mykola Burtyka, 6th-year student, Academic and Research Medical Institute of Sumy State University, 1, Sanatorna st., Sumy, Ukraine, 40018

For citation:

Lychko V, Lychko S, Zhivotovsky I, Burtyka M. MASTICATORY MYOFASCIAL PAIN SYNDROME PROVOKED BY SARS-COV-2 INFECTION IN A PATIENT WITH OROFACIAL PATHOLOGY (CLINICAL CASE). *The Journal of V. N. Karazin Kharkiv National University. Series «Medicine».* 2023;46:57–63. DOI: <https://doi.org/10.26565/2313-6693-2023-46-06> (in Ukrainian)

INTRODUCTION

Myofascial pain syndrome (MFPS) is characterised by chronic pain when appears the myofascial trigger points (MTP), which are sensitive taut areas within muscles [1]. MTP touching can cause pain either in the muscle itself or can irradiate to another part of the body. Diagnosis is typically made through clinical examination and palpation of the MTP. MFPS can be caused by various factors, such as postural dysfunction, trauma, psychological stress, spinal or orofacial pathology, etc. The condition's pathophysiology involves an initial stimulus that increases acetylcholine release, leading to muscle fibre depolarization and contraction [2]. Repetitive stimulation can cause hypoxia and nociceptor sensitization, resulting in MPT formation. Recently studies have shown that some infections, for example, SARS-CoV-2, can cause MFPS, along with other symptoms such as myalgia, arthralgia, respiratory dysfunction, and general weakness [3, 4].

A dentist is most often faced with the problem of MFPS in patients with temporomandibular joint dysfunction [5]. But there are cases of its development in patients with a normally functioning joint. In general, this syndrome can be caused by many reasons: distortion of the bite, one-sided type of chewing, jaw injuries, careless chewing of hard food, the excessive opening of the mouth during laughing, yawning, singing, clenching the teeth, grimacing; some iatrogenies – unsuccessful prosthetics or, for example, by installing an inflated seal, when the load on the jaw is unevenly distributed [6].

A deep bite and the absence of many teeth, pathological wear of the hard tissues of the teeth can also be the causes of MFPS [6].

Symptoms include pain in cooperation with sensitivity increasing some masticatory structures and areas around them, which may radiate to other areas of the head and neck. Often, the appearance of the MFPS clinic is accompanied by abnormalities in the mobility

of the mandible. The diagnosis is based on anamnesis and additional examination of the patient [7].

This is the most common disease that spreads to the temporomandibular region. MFPS occurs more often in women and has a bimodal age distribution immediately after 20 years and during menopause [8].

In the affected muscle, the formation of local pain and MTP can also be the result of such parafunctional manifestations as bruxism (clenching or grinding of teeth), which are considered two different forms – bruxism of sleep or vivacity, each of which has a different aetiology [9].

In this article, we present the case of MFPS developing in person with orofacial pathology diagnosed after SARS-CoV-2.

MATERIALS AND METHODS OF RESEARCH

Describes a person who has the instability of the bite caused by the absence, destruction and disposition of the chewing teeth led to disorders of the chewing muscles. The patient was found to have appearing MFPS symptoms after COVID-19. The systematic online search of articles utilising the search terms «Coronavirus, SARS-COV-2 and Myofascial pain syndrome», published between January 2020 and October 2023, was performed.

CASE PRESENTATION

The patient is a 67-year-old overweight female. Past medical history was significant for diabetes mellitus type 2 and arterial hypertension.

She was diagnosed with SARS-CoV-2 in October 2021 by a PCR test and was hospitalised for 10 days. Her hospital course was remarkable for high-dose oxygen therapy with CPAP followed by 2 days of intubation, medical management with remdesivir and dexamethasone course.

The patient was subsequently discharged home. During the first week after discharge, she endorsed myalgia in chewing muscles, described as «tightness» and «spasms», in her

mandible with some radiation more to the left temporomandibular joints. She had never had this type of pain before and had no history of migraine headaches.

The patient went to the dentist with complaints of headache and stiffness in the

area of masticatory muscles, absence and destruction of lateral teeth, difficulty in chewing food, mobility and displacement of individual teeth, periodic bleeding gums, as well as aesthetic disorders (figures 1–2).

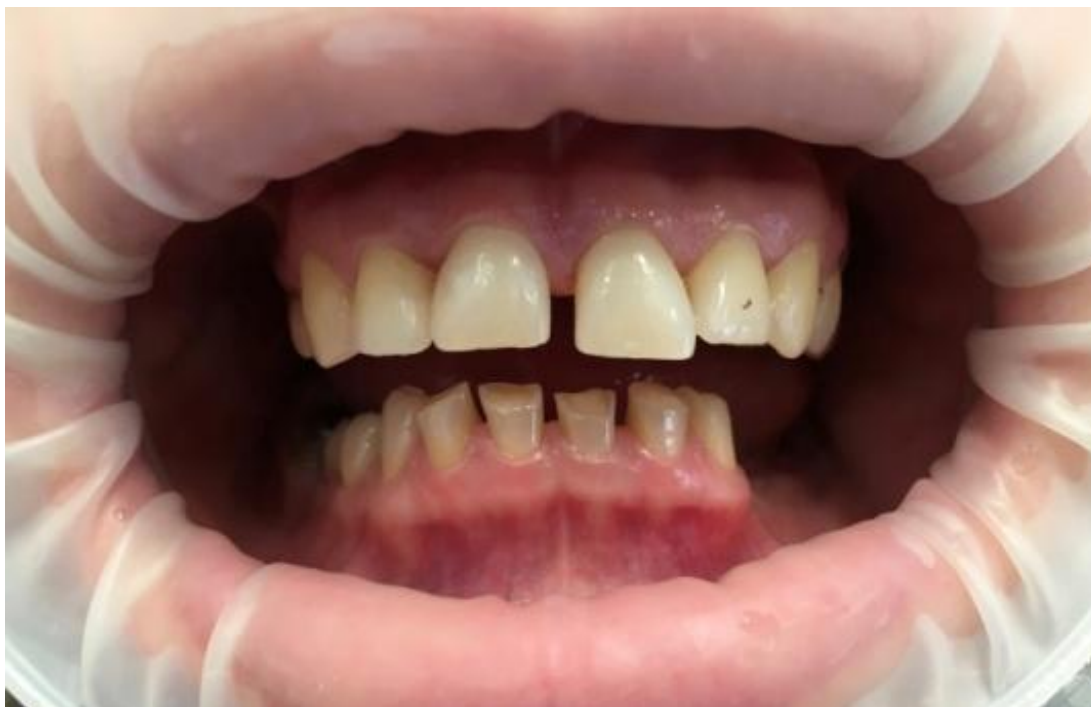

Fig. 1. The condition of the teeth in the oral cavity

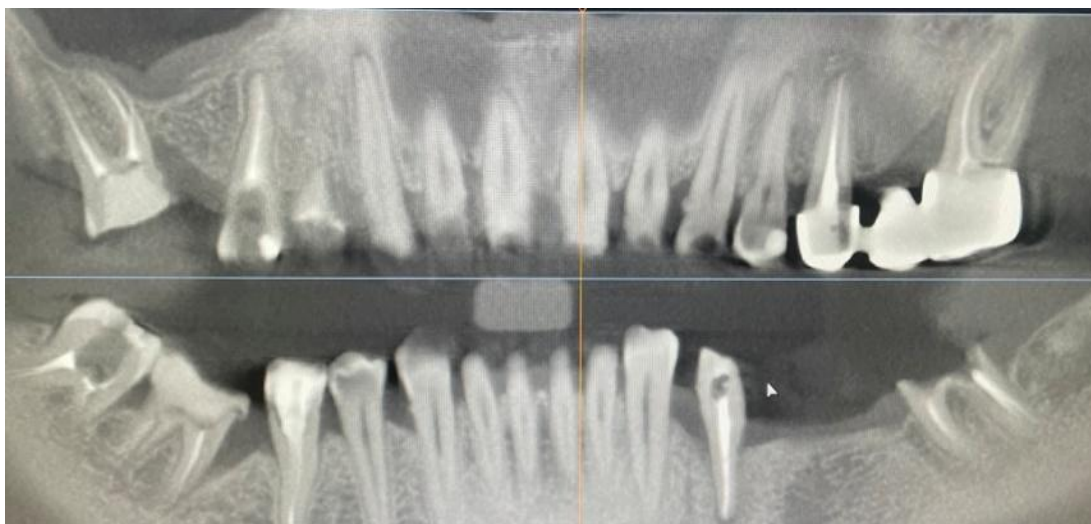


Fig. 2. Cone-beam computed tomography

Periodontal symptoms have been observed for more than five years, which the patient associates with diabetes. These symptoms significantly increased after the transfer of COVID-19, namely increased tooth mobility and bleeding gums.

During the objective examination, secondary partial adentia was revealed, which led to pathology and instability of the bite, defects of the hard tissues of the chewing teeth, pathological wear of the frontal group and traumatic occlusion phenomena. During

palpation, trigger points were found in the area of the masticatory and temporal muscles. The pain the patient indicated was more on the left side. Muscle hypertonus was also expressed on the same side, which was visualised by a slight asymmetry of the face.

At the time of examination, she initially took pregabalin 75 mg bid for pain management. The patient has refused interventional management in the form of trigger point injections. She underwent a series of ten trigger point injections (dry needling) in her chewing muscles, with about 30% immediate relief. The patient was referred to physical therapy to regain strength and conditioning targeted especially for her chewing muscles and both temporomandibular joints. For short and long-term relief were used some non-invasive therapy methods such as electrical stimulation, ultrasound, laser, and magnet therapies. On her post-procedure follow-up one month later, the patient's numerical pain rating scale (NPRS) was a 1/10 and seemed to have had a significant improvement and reduction in her self-reported pain by 80 %.

The patient was followed up in the clinic 3 months later with some improvement. The NPRS at this follow-up visit was 1/10. On physical exam, some palpable taut muscle bands were still identified in the chewing muscles, with a similar referral pattern as before.

DISCUSSION

Myofascial pain is a common cause of soft tissue discomfort that can cause tenderness or changes in the autonomic system [10]. To diagnose it, doctors will first evaluate the patient's medical history, considering factors such as age, location of pain, duration, daily activity level, occupation, and any associated symptoms. MFPS can develop due to traumatic events, muscular overloads, or psychological stress, leading to palpable bands and trigger points within the muscles [1]. Diagnosis of MFPS is primarily clinical and requires the presence of a taut band within the muscle, tenderness at a point on the band, and the reproduction of the patient's pain [11]. While other symptoms, such as local twitch response, referred pain, weakness, restricted range of motion, and autonomic signs may occur, but they are not necessary for a diagnosis. However, these

symptoms may be masked due to individual variability of the patients and many other conditions. There are no specific lab tests to confirm the diagnosis of MFPS, but examinations such as electromyography, thermography, and ultrasound imaging can be used to help identify the condition [2].

Treating myofascial pain involves addressing the underlying factors that caused the trigger point to form, which can be accomplished by stretching sarcomeres and restoring normal muscle length [12]. Various manual therapies such as muscle energy, ischemic compression, strain and counter strain, trigger point pressure, and transverse friction massage have been described for deactivating myofascial trigger points and providing moderate relief for short periods [13]. Non-invasive therapies such as electrical stimulation, ultrasound, laser, and magnet therapies have also been found to provide moderate evidence for short and long-term relief [14]. Invasive therapies involve using a trigger point injection to inactivate the MTP, with or without local anaesthetic. Inserting a needle into the trigger point causes a local twitch response and may reproduce pain, but ultimately results in relaxation of the taut muscle band and pain relief [12, 15].

The treatment approach for pain management involves a combination of some analgesic medications such as NSAIDs, diclofenac, COX-2 inhibitors, tramadol, and lidocaine patches [8]. Although each medication works differently and may not target the same nociceptors, they can still alleviate pain similar to musculoskeletal pain. Another group of medications used for pain management includes muscle relaxants and antidepressants such as tizanidine, benzodiazepine, and tricyclic antidepressants (TCA) [16]. Tizanidine is typically the first choice of treatment, whereas TCAs may be prescribed if other treatment options fail due to the high risk of side effects. Botulinum type A toxin may also be used for pain management. However, more research is needed to determine its effectiveness [17].

The onset of MFPS is typically caused by either traumatic stress, some orofacial issues, mechanical trauma or psychological stress, as explained previously. In combination with bite defects caused by the absence of many teeth SARS-CoV-2 as well could be one of

these stressors that triggered the condition, which was identified in the presented case through a comprehensive analysis of medical history and physical examination results.

Although there is no direct correlation between SARS-CoV-2 and MFPS, prolonged bedrest or inactivity, as seen in extended hospital stays, may cause muscle overloads, atrophy, or psychological stress, leading to the formation of palpable bands and latent MTP. Moreover, during viral infections, myalgia is frequently mediated by interleukine-6, which results in muscle and joint pain [18]. In SARS-CoV-2 infections, generalised inflammation and cytokine response could cause myalgia, resulting in prolonged pain and morbidity, known as long COVID syndrome [11]. The virus may also induce changes in nociceptor excitability, leading to neuropathies, worsening pre-existing pain conditions, and promoting pain. Cytokine dysregulation in COVID-19 may cause unique immune reactions that interact with nociceptors, leading to pain [19, 20].

The term «long COVID syndrome» refers to symptoms that persist for more than 12–24 weeks, while «persistent post-COVID syndrome» describes symptoms that last for more than 24 weeks. These symptoms affect multiple organ systems and require targeted treatment. Examples of post-COVID symptoms include autonomic, neurocognitive, and musculoskeletal dysfunctions [21].

REFERENCES

1. Barbero M, Schneebeli A, Koetsier E, Maino P. Myofascial pain syndrome and trigger points: evaluation and treatment in patients with musculoskeletal pain. *Curr Opin Support Palliat Care*. 2019;13(3):270-6. DOI: <https://doi.org/10.1097/spc.0000000000000445>
2. Duarte FCK, West DWD, Linde LD, Hassan S, Kumbhare DA. Re-Examining Myofascial Pain Syndrome: Toward Biomarker Development and Mechanism-Based Diagnostic Criteria. *Curr Rheumatol Rep*. 2021;23(8):69. DOI: <https://doi.org/10.1007/s11926-021-01024-8>
3. Li LQ, Huang T, Wang YQ, Wang ZP, Liang Y, Huang TB, et al. COVID-19 patients' clinical characteristics, discharge rate, and fatality rate of meta-analysis. *J Med Virol*. 2020;92(6):577-83. DOI: <https://doi.org/10.1002/jmv.25757>
4. Willi S, Lüthold R, Hunt A, Hänggi NV, Sejdiu D, Scaff C, et al. COVID-19 sequelae in adults aged less than 50 years: A systematic review. *Travel Med Infect Dis*. 2021;40:101995. DOI: <https://doi.org/10.1016/j.tmaid.2021.101995>
5. Elbarbary M, Oren A, Goldberg M, Freeman BV, Mock D, Tenenbaum HC, et al. Masticatory Myofascial Pain Syndrome: Implications for Endodontists. *J Endod*. 2022;48(1):55–69. DOI: <https://doi.org/10.1016/j.joen.2021.10.004>
6. Golanska P, Saczuk K, Domarecka M, Kuć J, Lukomska-Szymanska M. Temporomandibular Myofascial Pain Syndrome-Aetiology and Biopsychosocial Modulation. A Narrative Review. *Int J Environ Res Public Health*. 2021;18(15). DOI: <https://doi.org/10.3390/ijerph18157807>
7. Kalladka M, Young A, Khan J. Myofascial pain in temporomandibular disorders: Updates on etiopathogenesis and management. *J Bodyw Mov Ther*. 2021;28:104-13. DOI: <https://doi.org/10.1016/j.jbmt.2021.07.015>

It has been suggested that there should be a temporal relationship between the onset of new symptoms and positive SARS-CoV-2 testing due to the wide range of symptomatology associated with the virus activity. The case mentioned above demonstrates a correlation between post-COVID symptoms and coronavirus that persists beyond the typical «wash out» period of 4–5 weeks after viral diagnosis [22]. Recent research indicates that if symptoms persist beyond this period, there is a strong likelihood of a relationship between diagnosis and symptoms.

CONCLUSION

The coronavirus has widespread effects on the human body, and recent observations show a correlation between MFPS and SARS-CoV-2, as in the presented case. Specifically, this virus is known to cause tension and strain on skeletal muscles, leading to the formation of MTP. A patient with a PCR diagnosis of SARS-CoV-2 and undergoing prolonged bed rest reported long-term side effects and pain symptoms. The cytokine storm caused by the viral infection is thought to be responsible for these pain symptoms [23]. It's an up-and-coming issue for future research, which will help to understand the mechanisms of MTP development in coronavirus patients independently of other medical conditions.

8. Urits I, Charipova K, Gress K, Schaaf AL, Gupta S, Kiernan HC, et al. Treatment and management of myofascial pain syndrome. *Best Pract Res Clin Anaesthesiol.* 2020; 34 (3): 427–48. DOI: <https://doi.org/10.1016/j.bpa.2020.08.003>
9. Pires RE, Reis IGN, Waldolato GS, Pires DD, Bidolegui F, Giordano V. What Do We Need to Know About Musculoskeletal Manifestations of COVID-19?: A Systematic Review. *JBJS Rev.* 2022;10(6). DOI: <https://doi.org/10.2106/jbjs.Rvw.22.00013>
10. Dotan A, David P, Arnheim D, Shoenfeld Y. The autonomic aspects of the post-COVID19 syndrome. *Autoimmun Rev.* 2022;21(5):103071. DOI: <https://doi.org/10.1016/j.autrev.2022.103071>
11. Ursini F, Ciaffi J, Mancarella L, Lisi L, Brusi V, Cavallari C, et al. Fibromyalgia: a new facet of the post-COVID-19 syndrome spectrum? Results from a web-based survey. *RMD Open.* 2021;7(3). DOI: <https://doi.org/10.1136/rmdopen-2021-001735>
12. Charles D, Hudgins T, MacNaughton J, Newman E, Tan J, Wigger M. A systematic review of manual therapy techniques, dry cupping and dry needling in the reduction of myofascial pain and myofascial trigger points. *J Bodyw Mov Ther.* 2019;23(3):539-46. DOI: <https://doi.org/10.1016/j.jbmt.2019.04.001>
13. Zha M, Chaffee K, Alsarraj J. Trigger point injections and dry needling can be effective in treating long COVID syndrome-related myalgia: a case report. *J Med Case Rep.* 2022; 16 (1): 31. DOI: <https://doi.org/10.1186/s13256-021-03239-w>
14. Batres-Marroquín AB, Medina-García AC, Vargas Guerrero A, Barrera-Villalpando MI, Martínez-Lavín M, Martínez-Martínez LA. Effect of COVID-19 Pandemic Lockdown on Fibromyalgia Symptoms. *J Clin Rheumatol.* 2022;28(1):e289-e91. DOI: <https://doi.org/10.1097/rhu.0000000000001685>
15. Khan M, Nishi SE, Hassan SN, Islam MA, Gan SH. Trigeminal Neuralgia, Glossopharyngeal Neuralgia, and Myofascial Pain Dysfunction Syndrome: An Update. *Pain Res Manag.* 2017;2017:7438326. DOI: <https://doi.org/10.1155/2017/7438326>
16. Devlikamova FI. Results of the post-registration clinical study «PARUS» on efficiency and safety assessment of Mydocalm-Richter for local injection therapy of a myofascial trigger zone. *Ter Arkh.* 2018;90(6):81-8. DOI: <https://doi.org/10.26442/terarkh201890681-88>
17. Serrera-Figallo MA, Ruiz-de-León-Hernández G, Torres-Lagares D, Castro-Araya A, Torres-Ferreros O, Hernández-Pacheco E, et al. Use of Botulinum Toxin in Orofacial Clinical Practice. *Toxins (Basel).* 2020;12(2). DOI: <https://doi.org/10.3390/toxins12020112>
18. Mendieta D, De la Cruz-Aguilera DL, Barrera-Villalpando MI, Becerril-Villanueva E, Arreola R, Hernández-Ferreira E, et al. IL-8 and IL-6 primarily mediate the inflammatory response in fibromyalgia patients. *J Neuroimmunol.* 2016;290:22-5. DOI: <https://doi.org/10.1016/j.jneuroim.2015.11.011>
19. Arunachalam PS, Wimmers F, Mok CKP, Perera RAPM, Scott M, Hagan T, et al. Systems biological assessment of immunity to mild versus severe COVID-19 infection in humans. *Science.* 2020;369(6508):1210-20. DOI: <https://doi.org/10.1126/science.abc6261>
20. Mathew D, Giles JR, Baxter AE, Greenplate AR, Wu JE, Alanio C, et al. Deep immune profiling of COVID-19 patients reveals patient heterogeneity and distinct immunotypes with implications for therapeutic interventions. *bioRxiv.* 2020. DOI: <https://doi.org/10.1101/2020.05.20.106401>
21. Fernández-de-Las-Peñas C, Palacios-Ceña D, Gómez-Mayordomo V, Cuadrado ML, Florencio LL. Defining Post-COVID Symptoms (Post-Acute COVID, Long COVID, Persistent Post-COVID): An Integrative Classification. *Int J Environ Res Public Health.* 2021;18(5). DOI: <https://doi.org/10.3390/ijerph18052621>
22. Fialho MFP, Brum ES, Oliveira SM. Could the fibromyalgia syndrome be triggered or enhanced by COVID-19? *Inflammopharmacology.* 2023;1-19. DOI: <https://doi.org/10.1007/s10787-023-01160-w>
23. Hu B, Huang S, Yin L. The cytokine storm and COVID-19. *J Med Virol.* 2021;93(1):250-6. DOI: <https://doi.org/10.1002/jmv.26232>

Received: 03.11.2023

Accepted: 04.24.2023

Conflicts of interest: author has no conflict of interest to declare.

Личко В. С.^{А, С, D, F}, Личко С. О.^{В, С, D}, Животовський І. В.^{В, С, E}, Буртика М. М.^В

ЖУВАЛЬНИЙ МІОФАСЦІАЛЬНИЙ БОЛЬОВИЙ СИНДРОМ, ЩО СПРОВОКОВАНИЙ SARS-COV-2 ІНФЕКЦІЄЮ У ОСІБ З ОРО-ЛИЦЕВОЮ ПАТОЛОГІЄЮ (КЛІНІЧНИЙ ВИПАДОК)

А – концепція та дизайн дослідження; В – збір даних; С – аналіз та інтерпретація даних; D – написання статті; E – редагування статті; F – остаточне затвердження статті

Анотація. Міофасціальний больовий синдром (МФБС) – це хронічний больовий стан, що характеризується появою міофасціальних тригерних точок (МТТ) у м'язах. Захворювання може бути спричинене різними факторами та діагностується шляхом клінічного огляду та пальпації МТТ. Результати недавніх досліджень показали, що такі інфекції, як SARS-CoV-2, можуть спричинити МФБС, особливо у поєднанні з іншими захворюваннями. Лікарі-стоматологи часто стикаються з проблемою МФБС у пацієнтів з дисфункцією скронево-нижньощелепного суглоба, але вона може розвинутися і у пацієнтів з нормально функціонуючим суглобом. Симптоми найчастіше включають біль, чутливість і порушення рухливості нижньої щелепи. У цій статті представлено клінічний випадок розвитку МФБС у пацієнтки з орофасціальною патологією на фоні перенесеної SARS-CoV-2 інфекції.

Матеріали та методи дослідження. Описано особу з нестабільністю прикусу, яка викликана відсутністю, руйнуванням і розхитуванням жувальних зубів та призвела до розвитку функціональних, а потім і органічних розладів жувальних м'язів. У пацієнтки було виявлено симптоми МФБС після перенесеної SARS-CoV-2 інфекції. Проведено систематичний онлайн-пошук статей із використанням пошукових термінів «Коронавірус, SARS-COV-2 та міофасціальний больовий синдром», що були опубліковані в період з січня 2020 року по жовтень 2023 року.

Результати. В жовтні 2021 року після підтвердження діагнозу SARS-CoV-2 інфекції пацієнтку госпіталізували на 10 днів. Після виписки звернулася до лікаря-стоматолога зі скаргами на головний біль та скутість у ділянці жувальних м'язів, відсутність та руйнування бічних зубів, утруднене пережовування їжі, рухомість та зміщення окремих зубів, періодичну кровоточивість ясен, а також деякі естетичні порушення. Під час об'єктивного обстеження виявлена вторинна часткова адентія, що призвела до нестабільності прикусу, дефектів твердих тканин жувальних зубів, патологічної стертості фронтальної групи, травматичних явищ прикусу. Під час пальпації виявлено МТТ в ділянці жувальних та скроневих м'язів. Пацієнтка пройшла серію фізіотерапевтичних маніпуляцій на жувальні м'язи, що призвело до негайного полегшення приблизно на 30 %.

Висновок. МФБС може бути спричинений різними факторами, включаючи інфекції, такі як SARS-CoV-2. Діагноз ґрунтується на клінічному огляді та пальпації МТТ, а лікування може включати ін'єкції в тригерні точки, фізіотерапію та неінвазивні методи терапії. У представленому випадку у пацієнта було поєднання часткової адентії, яка призвела до нестабільності прикусу із SARS-CoV-2 інфекцією, що спровокувало розвиток МФБС.

КЛЮЧОВІ СЛОВА: *скронево-нижньощелепна дисфункція, міофасціальний больовий синдром, бруксизм, дефект прикусу, тригерна точка*

ІНФОРМАЦІЯ ПРО АВТОРІВ

Личко Володимир Станіславович, д. мед. н., доцент кафедри нейрохірургії та неврології навчально-наукового Медичного інституту Сумського державного університету, вул. Санаторна. 1, Суми, Україна, 40018, e-mail: v.lychko@med.sumdu.edu.ua, ORCID ID: <https://orcid.org/0000-0001-5518-5274>

Личко Світлана Олександрівна, викладач-стажист, кафедра стоматології навчально-наукового Медичного інституту Сумського державного університету, вул. Санаторна. 1, Суми, Україна, 40018, e-mail: s.lychko@med.sumdu.edu.ua, ORCID ID: <https://orcid.org/0000-0001-6906-1643>

Животовський Ігор Володимирович, асистент, кафедра стоматології навчально-наукового Медичного інституту Сумського державного університету, вул. Санаторна. 1, Суми, Україна, 40018, e-mail: i.zhivotovsky@med.sumdu.edu.ua, ORCID ID: <https://orcid.org/0000-0002-1899-5558>

Буртика Микола Миколайович, студент 6-го курсу, навчально-науковий Медичний інститут Сумського державного університету, вул. Санаторна. 1, Суми, Україна, 40018

Для цитування:

Личко ВС, Личко СО, Животовський ІВ, Буртика ММ. ЖУВАЛЬНИЙ МІОФАСЦІАЛЬНИЙ БОЛЬОВИЙ СИНДРОМ, ЩО СПРОВОКОВАНИЙ SARS-COV-2 ІНФЕКЦІЄЮ У ОСІБ З ОРО-ЛИЦЕВОЮ ПАТОЛОГІЄЮ (КЛІНІЧНИЙ ВИПАДОК). Вісник Харківського національного університету імені В. Н. Каразіна. Серія «Медицина». 2023;46:57–63. DOI: 10.26565/2313-6693-2023-46-06

*Отримано: 11.03.2023
Прийнято до друку: 24.04.2023*

Конфлікт інтересів: відсутній.