

Romanian Journal of DIABETES, NUTRITION AND METABOLIC DISEASES

Editorial

SARS-CoV-2 EPIDEMIC AND DIABETES
Cristian Guja

Original papers

**THE EFFECT OF PROTEIN FRACTIONS OF AVOCADO
(Persea americana) ON BIOCHEMICAL PARAMETERS
IN A DIABETIC RAT MODEL**
Zena Aljawadi

**THE REMODELING OF LUNGS UNDER THE INFLUENCE
OF ALLOXAN-INDUCED HYPERGLYCEMIA**
Tatiana Teslyk, Olha Yarmolenko, Valentyna Bumeister,
Nadiia Demikhova, Olha Prykhodko, Serhii Dmytruk, Iya Dehtyarova

**THE RELATIONSHIP BETWEEN NON-LINEAR ANALYSIS
OF HEART RATE VARIABILITY, QTC INTERVAL AND
CARDIOVASCULAR RISK FACTORS IN YOUNG
INDIVIDUALS WITH PRE-DIABETES**
Deepika Velusami, Vijayakumar Raman, Muthu Gopal

Review articles

**THE EFFECTS OF EXENATIDE ON SERUM CRP LEVELS
IN PATIENTS WITH TYPE 2 DIABETES: A SYSTEMATIC
REVIEW OF RANDOMIZED CONTROLLED TRIALS**
Bogdan-Horia Apan, Cornelia Bala, Anamaria Cristina,
Anca Dana Buzoianu

**INTERACTION OF ADIPOKINES WITH DIABETES
MELLITUS AND DENTAL IMPLANTS**
Meenu Goel, Amorin Remus Popa

The Official Journal of the
**ROMANIAN SOCIETY OF DIABETES,
NUTRITION AND METABOLIC DISEASES**



Original Article

The Remodeling of Lungs Under the Influence of Alloxan-Induced Hyperglycemia

Tatiana Teslyk¹, Olha Yarmolenko¹, Valentyna Bumeister¹, Nadiia Demikhova^{1*}, Olha Prykhodko¹, Serhii Dmytruk¹, Iya Dehtyarova²

¹ Sumy State University, Sumy, Ukraine

² National Academy of Public Administration under the President of Ukraine, Kiev, Ukraine

* Correspondence to: Nadiia Demikhova, Ryms'koho-Korsakova St, 2, Sumy, Sumy Oblast, Ukraine, 40000. e-mail: nadezhda-sumy@ukr.net

Received: 15 February 2020 / Accepted: 3 March 2020

Abstract

Introduction: Diabetes mellitus is a global medical and social problem. 2-3% of the population suffers from diabetes mellitus. According to current forecasts, the number of people with diabetes mellitus will double every 15 years. Diabetes mellitus is the basis for the development of complex comorbidities and complications such as diabetic microangiopathy and neuropathy. Diabetes patients are at increased risk for atherosclerosis, coronary heart disease, and renal failure. Scientists around the world have been thoroughly engaged in the problem of hyperglycemia, which is the consequence of type 1 diabetes mellitus, but the causes of its occurrence have not been fully established yet. The study aimed to investigate the lungs of pre-reproductive age rats under the influence of alloxan-induced hyperglycemia. **Material and Methods:** 12 rats of 3 months of age were involved in the experiment. They were divided into two series: experimental and control. The Control series includes six intact rats. For the experimental modeling of hyperglycemia, we used alloxan monohydrate, pre-dissolved in 0.9% solution of sodium chloride, which was then injected intraperitoneally once at a dose of 20 mg/100 g on an empty stomach. The experiment lasted 60 days. We measured the glucose level using the Accu-Chek Advantage (Boehringer, Germany) at 2, 12, and 24 hours after alloxan injection, and then weekly. The average level of glucose in the blood remained at $11 \text{ mmol/L} \pm 2 \text{ mmol/L}$. To study the remodeling of the lungs, we used the histological examination by a light microscope (Olympus BH-2) and histomorphometry using the universal certified program "SEO Scan Lab 2.0" and "SEO Image Lab 2.0". The obtained data were processed on a personal computer using the software "GraphPad" and a licensed Excel XP spreadsheet editor (Microsoft Office 2013). The data were analyzed by unpaired t-test. P values ≤ 0.05 were considered as statistically significant. **Results:** Obtained morphometric data shows the increase of the width of alveoli by 8.5% ($p < 0.05$), the width of the conducting part of the respiratory bronchiole by 15.7% ($p < 0.05$) and the thickness of the interalveolar septum by 8.3% ($p < 0.05$). The wall thickness of pulmonary vessels increased by 22.9% ($p < 0.05$). Lymphoid nodules were more hypertrophied compared to the control ones by 2.4 times ($p < 0.05$). **Conclusions:** Alloxan-induced hyperglycemia leads to the development of emphysematous changes in combination with restriction. The vascular wall of muscular pulmonary vessels was thickened due to hypertrophy of the tunica media and tunica externa. The hypertrophy of lymphoid follicles and lymph nodes of the upper and lower mediastinum was observed in experimental animals.

Keywords: Lung, alloxan, hyperglycemia, age.

Introduction

Diabetes mellitus is a global medical and social problem because it leads to disability and death. It is ranked third after cardiovascular diseases and cancer. Approximately 300 million individuals are suffering

from diabetes mellitus worldwide [1]. Type 1 Diabetes Mellitus mainly affects children and adolescents, reaching 1 million patients worldly [2, 3]. Diabetes mellitus is the basis for the development of complex comorbidities and complications such as diabetic microangiopathy and neuropathy. Diabetes patients are at increased



risk for atherosclerosis, coronary heart disease, and renal failure [4-10]. For about half a century, scientists around the world have been thoroughly engaged in the problem of hyperglycemia, which is the consequence of diabetes mellitus type 1, but the causes of its occurrence have not been fully established yet. The most relevant modern theory is the autoimmune theory of diabetes pathogenesis [11, 12]. The interest in solving the problem of type 1 diabetes mellitus is not diminishing and encourages scientists to search for new ways of diagnosis, treatment and prevention. Violations of all kinds of metabolism in chronic hyperglycemia lead to generalized lesions of the macro- and microcirculation [13, 14]. Diabetic angiopathies have been thoroughly studied in the kidneys, retina, skin, and spleen, while changes in the blood vessels of the pulmonary circulation and, consequently, in the lungs are less explored.

Therefore, our main aim was to investigate the lungs of pre-reproductive age rats under the influence of alloxan-induced hyperglycemia.

Material and Methods

Twelve rats at the age of 3 months were divided into two series: experimental and control. Six experimental rats were served as an animal model of alloxan-induced hyperglycemia. The Control series includes six intact rats. For the experimental modeling of hyperglycemia, which was due to absolute insulin deficiency in the body, we used alloxan monohydrate. Alloxane monohydrate is a decomposition product of uric acid, which, through a parenteral route of administration, causes selective necrosis of pancreatic islets by interacting with the thiol glucokinase groups of the β -cell enzyme. As a result, glucose oxidation, ATP generation, and insulin secretion are reduced. Alloxan-induced hyperglycemia was simulated by injection of alloxan, pre-dissolved in 0.9% solution of sodium chloride, intraperitoneally once at a dose of 20 mg/100 g on an empty stomach. It is known that alloxan is toxic to cells of the tubules of the nephron [15]. Therefore, the animals additionally received a 10% glucose solution during the 24 hours after alloxan injection and 5% glucose solution during the experiment, which lasted 60 days. We measured the glucose level using Accu-Chek Advantage (Boehringer, Germany) at 2, 12, and 24 hours after alloxan injection, and then weekly. The average level of glucose in the blood remained at $11 \text{ mmol/L} \pm 2 \text{ mmol/L}$.

To study the remodeling of the lungs under hyperglycemia, we used the following methods:

- Histological examination. Histological samples prepared by the standard method were stained with hematoxylin and eosin, investigated using the light microscope (Olympus BH-2), and photographed with a digital video camera (Baumer Optronic CX 05c, Switzerland).
- Histomorphometry. It was performed dynamically using the universal certified program "SEO Scan Lab 2.0" and "SEO Image Lab 2.0". We measured the width and depth of pulmonary alveoli, the width of the conducting part of the respiratory bronchioles, the thickness of the interalveolar septum, perimeter of the lymphoid follicles, the thickness of the complex tunica intima + tunica media of the muscular pulmonary arteries, the thickness of the tunica media of vessels, and the thickness of the tunica externa of vessels.
- A statistical method. The obtained data were processed on a personal computer using the software "GraphPad" and a licensed Excel XP spreadsheet editor (Microsoft Office 2013). The data were analyzed by unpaired t-test. P values ≤ 0.05 were considered statistically significant.

Ethical approval

This study was approved by the Ethics Committee of the Sumy State University, Ukraine. The keeping and all manipulations of animals were carried out in accordance with generally accepted recommendations, requirements and provisions set out in the following documents: "European Convention of the Protection of Vertebrate Animals used for Experimental and other Scientific Purposes" (Strasbourg, 1985) and "General Ethical Principles of Animal Experiments" adopted by the First National Congress of Bioethics (Kiev, 2001).

Results

The light microscopy of lung tissue samples reveals full-blooding, thickening of the interalveolar septa with single inclusions of collagen fibers in their composition comparing with samples of intact animals. The lumen of the alveoli is free (Figures 1, 2). Along with emphysematous changes, we found collapsing alveoli. The interalveolar septa are of different thicknesses: thin in the areas of the expanded alveoli, and thick and full-blooded in atelectatic areas. Stasis in the vessels can be observed as well. Different-sized clusters of

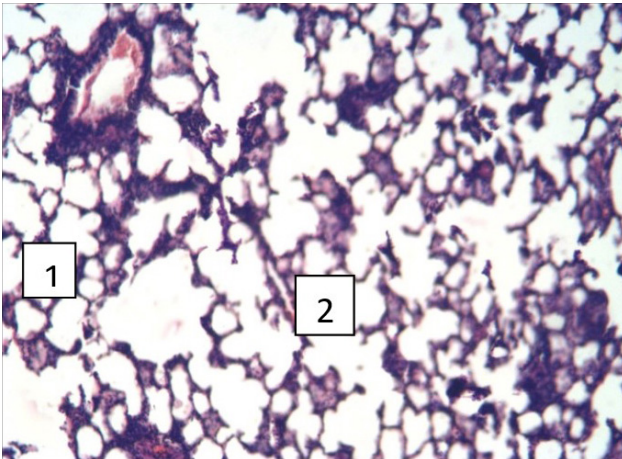


Figure 1: Lung's tissue of experimental rats $\times 100$. 1 - Pulmonary alveoli cavity; 2 - interalveolar septum.

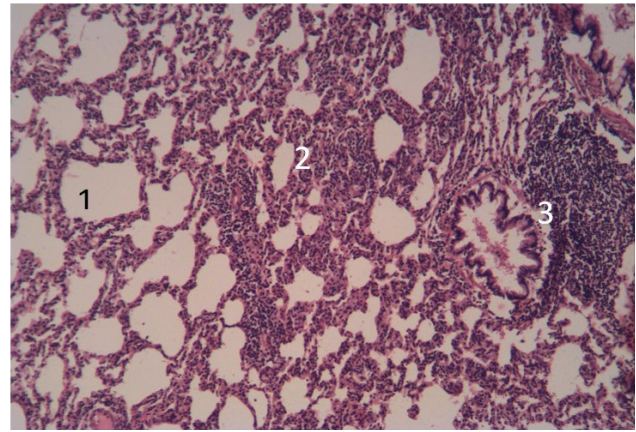


Figure 3: Lung's tissue of experimental rats $\times 100$. 1 - Emphysematous transformation of lung tissue; 2 - areas of atelectasis; 3 - hypertrophied lymphoid follicle.

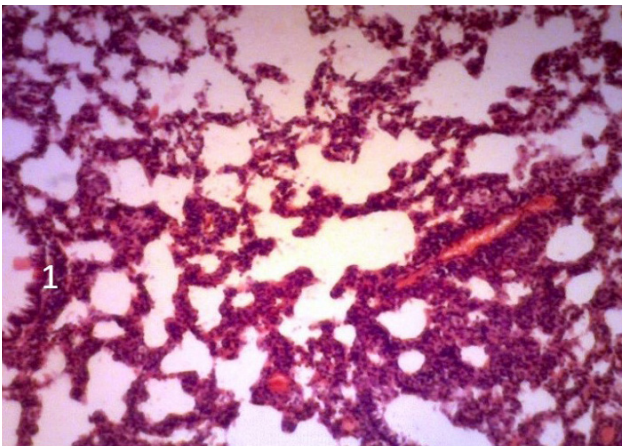


Figure 2: Lung's tissue of experimental rats $\times 100$. 1 - Thickened and full-blooded interalveolar septa.

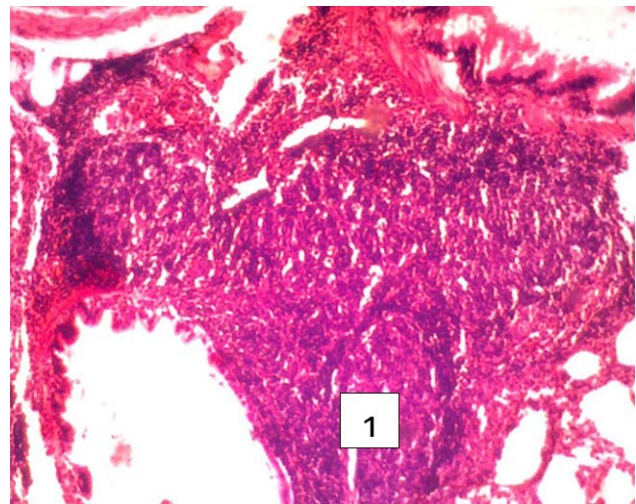


Figure 4: Lung's tissue of experimental rats $\times 100$. 1 - Hypertrophied, full-blooded pulmonary lymphoid follicle surrounding the bronchus in the form of a "clutch".

lymphoid tissue are found around bronchi and vessels. They contain a large number of vessels (Figures 3, 4).

Inside the interalveolar septa, there is a small number of mature collagen fibers. In the tunica externa and tunica media of muscular pulmonary vessels is the hypertrophy of mature collagen fibers (Figure 5).

Obtained morphometric data show the increase of the width of alveoli by 8.5% ($p < 0.05$), the width of the conducting part of the respiratory bronchioles by 15.7% ($p < 0.05$) and the thickness of the interalveolar septum by 8.3% ($p < 0.05$). Their values were $72.1 \pm 0.46 \mu\text{m}$, $62.003 \pm 0.16 \mu\text{m}$, and $6.9 \pm 0.04 \mu\text{m}$, respectively. This indicates the initial emphysematous changes in combination with fibrotic changes in the pulmonary stroma. The wall thickness of pulmonary vessels increased by 22.9% ($p < 0.05$) compared to intact animals and is $41.8 \pm 0.02 \mu\text{m}$ ($p < 0.05$); accordingly, the thickness of its components increases. Thus, the thickness of the com-

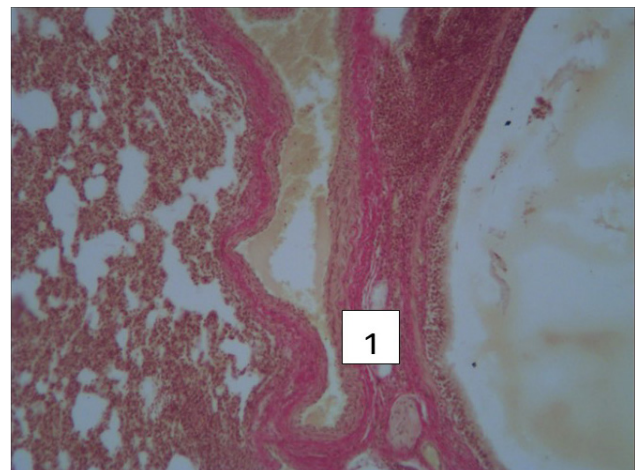


Figure 5: Lung's tissue of experimental rats $\times 100$. 1 - Collagen fibers in the wall of the pulmonary vessel.

plex tunica intima + tunica media of the muscular pulmonary vessels was $24.4 \pm 0.01 \mu\text{m}$ ($p < 0.05$), which is 28.9% ($p < 0.05$) more than in intact rats. The increase in this indicator is mainly due to the thickening of the muscular layer, which is higher than the control indicator by 22.3% ($p < 0.05$) and is equal to $22.3 \pm 0.02 \mu\text{m}$ ($p < 0.05$). The thickness of the tunica externa of vessels was $17.4 \pm 0.02 \mu\text{m}$ ($p < 0.05$). The morphometry of lymphoid nodules indicates their hypertrophy, $1049.6 \pm 0.16 \mu\text{m}$ ($p < 0.05$), which is 2.4 times ($p < 0.05$) more compared to the intact group.

Discussion

In the present study, we used such age groups as premature (3-month) animals. This choice is based on the fact that alloxan causes type 1 diabetes mellitus, which mainly affects this group of the population, while in older adults, type 2 diabetes mellitus is dominant [16].

The current study describes the processes of lung tissue remodeling, which are insufficiently covered in the scientific literature. Changes in the lungs occur primarily due to microcirculatory disorders in the pulmonary circulation under the influence of persistent hyperglycemia and are associated with the pro-inflammatory and proliferative properties of diabetes [17, 18]. The light microscopy with morphometry reveals sclerotic changes in the pulmonary stroma, destruction in the alveolates, which leads to the thickening of the interalveolar septa. Alloxan-induced hyperglycemia leads to the development of emphysematous changes in combination with restriction. The vascular wall of the muscular pulmonary vessels is thickened due to hypertrophy of the tunica media and tunica externa. The hypertrophy of lymphoid follicles and lymph nodes of the upper and lower mediastinum was observed in experimental animals. This is because the products of impaired glucose metabolism (advanced glycation end products - AGEs) are formed on the background of hyperglycemia. They bind to macrophage receptors, which in turn, secrete cytokines that provoke the development of immune responses [19-21].

Given the described changes, we can assume that microcirculatory disorders represent the trigger mechanism of lung tissue remodeling. Alloxan-induced hyperglycemia adversely affects the morphofunctional state of the lungs, both directly and indirectly (due to disorders of the cardiovascular system). Although the symptoms of complications from prolonged exposure

to hyperglycemia are more pronounced in internal organs like the kidneys, brain, heart, we need to take into account the achieved findings since the effects of hyperglycemia on lungs lead to morphological remodeling and then, with the progression of diabetes, to the development of respiratory failure. This fact is confirmed in modern scientific works [22, 23].

Conclusion

The obtained results suggest that alloxan-induced hyperglycemia affects the structure of the lung tissue. Changes in the parenchymatous component of the lung tissue are mosaic. They are characterized by the development of emphysematous changes and the presence of sites of atelectasis. Muscle-type vessels and lymphoid tissue undergo hypertrophic changes.

Conflict of Interest

The author declares no conflict of interest.

References

1. Guimaraes JFC, Muzio BP, Rosa CM et al. Rutin administration attenuates myocardial dysfunction in diabetic rats. *Cardiovascular Diabetology* 14: 1-6, 2015
2. IDF Diabetes Atlas, Eighth edition, 2017. Online version of IDF Diabetes Atlas: www.diabetesatlas.org
3. Smiyani OI, Loboda AM, Manko YA et al. Dynamics of content of some minerals in teenagers with cardiovascular system pathology against the background of chronic tonsillitis. *Wiadomosci lekarskie* 71(4): 861-864, 2018
4. Papadopoulou-Marketou N, Margeli A, Papassotiropoulos I, Chrousos GP, Kakana-Gantenbein C, Wahlberg J. NGAL as an Early Predictive Marker of Diabetic Nephropathy in Children and Young Adults with Type 1 Diabetes Mellitus. *J Diab Res* 2: 11-17, 2017
5. Sattar N. Revisiting the links between glycaemia, diabetes and cardiovascular disease. *Diabetologia* 56: 686-695, 2013
6. de Ferranti SD, de Boer IH, Fonseca V et al. Type 1 Diabetes Mellitus and Cardiovascular Disease: A Scientific Statement From the American Heart Association and American Diabetes Association. *Diabetes Care* 37(10): 2843-2863, 2014
7. Guzyk MM, Dyakun KO, Yanytska LV et al. Inhibitors of Poly(ADP-Ribose) Polymerase-1 as Agents Providing Correction of Brain Dysfunctions Induced by Experimental Diabetes. *Neurophysiology* 49(3): 183-193, 2017
8. Cherkashyna L, Konoval N, Shklyar A et al. Study of structural and biochemical changes in the muscular tissue of the oesoph-

- agus for solving the problem of diagnosing the prescription of death coming *Pol Merkur Lekarski* 48 (283): 42-44, 2020
9. Yarmolenko O, Sikora V, Bumeister V, Olga P. Age-dependent cardioprotective action of meldonium on heart remodeling under the experimental hypoosmolar hyperhydration. *Bangladesh J Med Sci* 18(2): 395-401, 2019
 10. Barchan G, Demikhov O, Cherkashyna L et al. A complex of regional ecological and medico-social factors: evaluation of dysplastic dependent pathology of the bronchopulmonary system *Pol Merkur Lekarski* 48 (283): 49-54, 2020
 11. Okey AO, Paul CC, Agomuo CO. Blood glucose level and lipid profile of alloxan-induced hyperglycemic rats treated with single and combinatorial herbal formulations *Journal of Traditional and Complementary Medicine* 6(2): 184-192, 2016
 12. Demikhova N, Cherkashyna L, Chernatska O et al. The relationship between lipid metabolism and albuminuria level with single nucleotide polymorphism -204a>c [rs 3808607] CYP7A1 gene in patients with 2 type diabetes mellitus and diabetic nephropathy *Rom J Diabetes Nutr Metab Dis* 26(3): 253-261, 2019
 13. Chernatska O, Demikhova N Improvement of treatment in persons with arterial hypertension and type 2 diabetes mellitus. *Georgian Medical News* 11(284): 47-51, 2018
 14. Chernatska O, Demikhova N, Rudenko T, Demikhov A Assessment of the lipid profile correction in patients with arterial hypertension and type 2 diabetes mellitus *Azerbaijan Medical Journal* 1: 95-99, 2019
 15. Misra M, Aiman U. Alloxan: An unpredictable drug for diabetes induction? *Indian Journal of Pharmacology* 44(4): 538-539, 2012
 16. Wenjun F. Epidemiology in diabetes mellitus and cardiovascular disease. *Cardiovascular Endocrinology & Metabolism* 6 (1): 8-16, 2017
 17. Khateeb J, Fuchs E, Khamaisi M. Diabetes and Lung Disease: A Neglected Relationship. *Rev Diabet Stud.* 15:1-15, 2019
 18. Marushchak M, Krynytska I, Petrenko N, Klishch I. The determination of correlation linkages between level of reactive oxygen species, contents of neutrophils and blood gas composition in experimental acute lung injury *Georgian Medical News* 4(253): 98-103, 2016
 19. Kohlmeier JE, Miller SC, Woodland DL. Cutting edge: antigen is not required for the activation and maintenance of virus-specific memory CD-8 T-cells in the lung airways. *J Immunol* 178(8): 4721-5, 2007
 20. Krynytska I, Marushchak M. The Indices of Nitric Oxide System in Rats with Carrageenan-Induced Enterocolitis Combined with Diabetes Mellitus. *Rom J Diabetes Nutr Metab Dis* 25(3): 283-288, 2018
 21. Prykhodko OA, Gulaya VI, Yarmolenko OS et al. Microscopic changes in the organs of rats under conditions of general dehydration of the organism *Azerbaijan Medical Journal* 4: 95-100, 2016
 22. Te-Wei H, Chun-Ta H, Sheng-Yuan R, Yu-Ju T, Feipei L, Chong-Jen Y. Diabetes mellitus in patients with chronic obstructive pulmonary disease-The impact on mortality. *PLoS ONE* 12(4), 2017
 23. Kinney GL, Black-Shinn JL, Wan ES et al. Pulmonary Function Reduction in Diabetes With and Without Chronic Obstructive Pulmonary Disease *Diabetes Care* 37(2): 389-395, 2014